



Case Report

Ileosigmoid knotting: An unusual cause of intestinal obstruction

Mahim Koshariya^{*}, Arpan Choudhary, Narendra Gome, Arvind Meravi, A. Rai, M. C. Songra

Department of Surgery, Gandhi Medical College, Bhopal, Madhya Pradesh, India

*Corresponding author email: mahimk2000@yahoo.co.uk

How to cite this article: Mahim Koshariya, Arpan Choudhary, Narendra Gome, Arvind Meravi, A. Rai, M. C. Songra. Ileosigmoid knotting: An unusual cause of intestinal obstruction. IAIM, 2015; 2(4): 179-181.

Available online at www.iaimjournal.com

Received on: 18-03-2015

Accepted on: 30-03-2015

Abstract

Ileosigmoid knot or double volvulus is an unusual cause of intestinal obstruction and presents as a surgical emergency. It affects men of middle and old age. It occurs due to entangling of ileal and sigmoid loops producing obstruction and strangulation. Here, we have described a case of 60 years old male presented with features of intestinal obstruction. Emergency laparotomy revealed ileosigmoid knotting with gangrene of involved segment. Resection of unviable portion with knot was done with double primary anastomosis and covering ileostomy.

Key words

Ileosigmoid knot, Double volvulus, Intestinal obstruction, Gangrene.

Introduction

Ileosigmoid knotting, also known as compound volvulus or double volvulus is a condition where the ileum wraps around the sigmoid colon and its mesentery. It is a rare surgical emergency, difficult to diagnose preoperatively. This is a surgical emergency that requires urgent exploration and resection of gangrenous bowel and untwisting of the volvulus. Ileosigmoid knot or double volvulus is an uncommon event where loops of ileum get wrapped around the redundant sigmoid colon causing obstruction of both, and rapidly progressing to gangrene [1]. It

occurs mostly in males in between their 4th and 6th decade of life. However it has also been reported in children [2].

Case report

A 60 years old male patient presented with complaints of severe pain in abdomen, distension of abdomen and not passing flatus and motion since 1 day. In past, patient had intermittent bouts of pain in abdomen for 2 years and constipation for 1 year. There was no history of bleeding per rectum and melena. On admission patient was dehydrated, with pulse

140/min and blood pressure 90/60 mmHg. Per abdominal examination revealed distended abdomen and tenderness, all over the abdomen. Guarding, rigidity and shifting dullness were also presented suggestive of peritonitis. Bowel sounds were absent. Digital rectal examination showed empty rectum, tenderness and boggy over anterior rectal wall, other findings were normal. Erect X-ray abdomen showed dilated small and large bowel loops. Routine blood investigations were within normal limit, except increase in total leukocyte count. In view of diagnosis of acute intestinal obstruction, exploratory laparotomy was planned.

Intra-operatively twisting of distal ileum and sigmoid colon was noted causing gangrene of involved segments, i.e. of sigmoid colon (**Photo - 1**) and ileum (**Photo - 2**) along with 2.5 liters of serosanguinous fluid. Resection of gangrenous bowel was done along with the knot, without any attempt to untwist it. Intestinal continuity restored with colo-rectal and ileo-transverse anastomosis, with covering loop ileostomy.

Postoperatively patient recovered quickly, with stable vitals and soft abdomen. Ileostomy started functioning from 2nd day onward. Successful stoma closure was done after 8 weeks.

Discussion

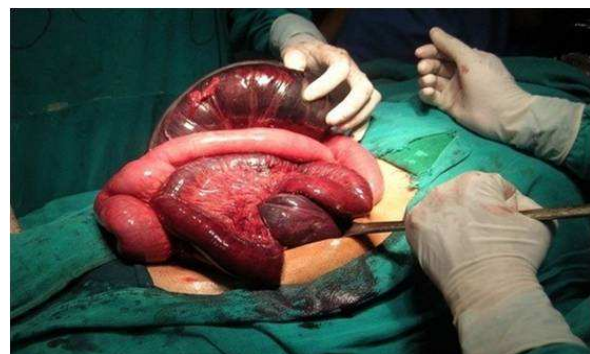
Ileosigmoid knotting also known as double volvulus, compound volvulus, and intestinal knotting, occurs as a loop of small intestine descends into left paracolic gutter to encircle the sigmoid in clockwise or an anti clockwise direction. As the knot tightens the bowel obstructs forming a double closed loops and the mesenteric involvement usually progresses to early strangulation [1]. The long pelvic mesocolon allows the ileum to twist around the sigmoid colon and then become gangrenous [3]. It occurs mostly in men in their 4th to 6th decade

of life [4]. Predisposing factors described are high fiber diet, frail and debilitated patient, chronic laxative use, hyper mobile small intestine with markedly elongated mesentery. Primary event is usually a hyperactive ileum winding around the narrow pedicle of a passive sigmoid.

Photo - 1: Intra-operative dilated gangrenous sigmoid colon.

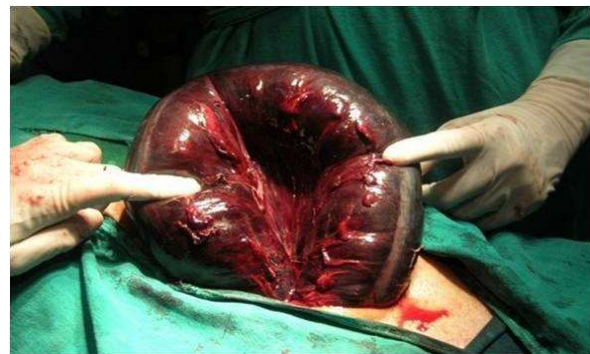

Photo - 2: Gangrenous sigmoid colon and terminal ileum with normal primal bowel loops.



Preoperative diagnosis is seldom obtained. Findings of plain X-ray abdomen include a dilated loop of the pelvic colon, the evidence of a small intestinal obstruction, retention of feces in an undistended proximal colon and encroachment of small bowel loops in left iliac fossa. CT abdomen shows dilated loop of intestine with central mesenteric vessels forming characteristic whirl and tightly twisted ileum [5].



Treatment includes resuscitation followed by surgery. Surgical options depend upon the condition of bowel, with viable intestinal loops, untying of knot is sufficient, however most cases presents with gangrene demanding en block resection of knot and double primary anastomosis of ileal and sigmoid segments [1, 6]. Other options available are closure of distal ileal stump with end to side ileo-colic bypass anastomosis, however it can produce blind loop syndrome. Old age, delay in diagnosis and extensive gangrene impart poor prognosis [7].

Conclusion

Ileosigmoid knotting also known as double volvulus, compound volvulus, and intestinal knotting is an uncommon cause of intestinal obstruction. Preoperative diagnosis is difficult and it rapidly progress to gangrene. It should be considered as a differential diagnosis in a elderly male presenting with features of acute intestinal obstruction. Prompt surgery with resection of gangrenous segment and anastomosis is the treatment of choice.

References

1. Shepherd JJ. Ninety-two cases of ileosigmoid knotting in Uganda. *Br. J of surgery*, 1967; 54: 561-566.
2. Ghassan A. Al-Nasir, M. M. Mohammed. Ileosigmoid knot Review of Literatures and Record of Seven Cases. *IJGE*, 2002; 1(3).
3. Kakar A., Bhatnagar B.N.S. Ileosigmoid Knotting: A clinical study in 11 cases. *Australia and New Zealand Journal of Surgery*, 1981; 51: 456.
4. Scott Q. J. Ileosigmoid knot and sigmoid volvulus. *S Afr J Surg*, 1973; 11: 29-32.
5. Lee S.H, Park Y.H, Won Y.S. The ileosigmoid knot: CT findings. *AJR Am J Roentgenol*, 2000; 174: 685-687.
6. Akgun Y. Management of ileosigmoid knotting. *Br J Surg*, 1997; 84: 672-673.
7. Puthu D, Rajan N, Shenoy G.M, Pai SU. The ileosigmoid knot. *Dis Colon Rectum*, 1991; 34: 161-166.

Source of support: Nil

Conflict of interest: None declared.