



Study of success rates in endoscopic dacryocystorhinostomy with and without stenting

Kirti Ambani¹, Niraj Suri², Hiren Parmar^{3*}

¹Assistant Professor, ENT Department, GMERS Medical College, Gandhinagar, Gujarat, India

²Associate Professor, ENT Department, GMERS Medical College, Gandhinagar, Gujarat, India

³Associate Professor, General surgery Department, GMERS Medical College, Gandhinagar, Gujarat, India

*Corresponding author email: drhirenparmar@gmail.com

How to cite this article: Kirti Ambani, Niraj Suri, Hiren Parmar. Study of success rates in endoscopic dacryocystorhinostomy with and without stenting. IAIM, 2015; 2(4): 52-56.

Available online at www.iaimjournal.com

Received on: 24-03-2015

Accepted on: 31-03-2015

Abstract

Background: The dacryocystorhinostomy (DCR) surgery involves fistulization of the lacrimal sac into the nasal cavity. DCR is currently the main stay of treatment of nasolacrimal duct (NLD) obstruction. It can be performed externally or endoscopically.

Aim: To evaluate the success rates of endoscopic DCR with silicone stenting comparing to those with DCR without stenting in patients with epiphora who failed medical treatment.

Material and methods: A retrospective study of 39 consecutive patients who underwent primary or revision endoscopic DCR with or without stenting was done at our hospital between January to July 2014. These patients were divided in two groups: Groups - A in which DCR was followed by stenting, Group – B in which no stent placement was done.

Results: There were more female patients – 28 (71.79%) than male patients – 11 (28.20%). The mean age was 40.44 years. Age range was 14–74 years. Both eyes were almost equally affected. Left eye was affected in 16 patients compared to 17 patients had right eye involvement. 6 patients had bilateral symptoms of which one eye was operated at a time. Revision cases included our own revision of endoscopic DCR without stenting 2 (5.12%) and of endoscopic DCR with stent 1 (2.5%). 4 of these patients had atrophic rhinitis, which was preoperatively controlled by appropriate medical treatment. 11 of these patients had deviated nasal septum in which 5 patients had undergone correction simultaneously. In our own revision cases of endoscopic DCR with stent, the cause was synechiae formation as simultaneous septoplasty with stenting was done. Revision cases of endoscopic DCR without stenting the causes were granulations and stoma closure. During revision surgery stenting was done.



Conclusion: Endoscopic DCR is a simple, minimally invasive procedure. In our study, we concluded that endoscopic DCR with stent placement had good results. Regular follow up after endoscopic DCR is necessary. Endoscopic DCR with stent has several advantages over classical external approach.

Key words

Dacryocystorhinostomy, Endoscopy, Stent.

Introduction

The dacryocystorhinostomy DCR surgery involves fistulization of the lacrimal sac into the nasal cavity. DCR is currently the main stay of treatment of nasolacrimal duct (NLD) obstruction. It can be performed externally or endoscopically. The advent of rigid endoscope has awakened interest in endonasal endoscopic DCR. Endoscopic DCR is well tolerated by patients with good success rates. Caldwell described the first intranasal DCR in 1893 [1]. Then in 1989, MC Donogh and Meiring [2] described the endoscopic endonasal DCR. Endonasal DCR surgery has advantages of preventing scar on the skin and preserving pump function of the nasolacrimal sac. Since then many modifications have been described. Different laser of Holmium: YAG, Argon, CO₂ (carbon dioxide), Potassium titanium phosphate (KTP) have been tried. Many techniques advocate the use of silicone stent which is placed as a loop in the superior and inferior canaliculi, through the common canaliculus and lacrimal sac into the nose by an endoscope. This can be kept for two weeks to six months [3, 4]. The aim of this study was to evaluate the success rates of endoscopic DCR with silicone stenting comparing to those with DCR without stenting in patients with epiphora who failed medical treatment.

Material and methods

A retrospective study of 39 consecutive patients who underwent primary or revision endoscopic DCR with or without stenting was done at our hospital between January to July 2014. These

patients were divided in two groups. Group - A in which DCR was followed by stenting, Group - B in which no stent placement was done. All patients were assessed by complete ENT and Ophthalmic examinations. In every patient with dacryocystitis, it is important to take a good history and carefully observe the patient. A thorough examination of the lacrimal system, included probing and sac syringing, to establish patency of the lacrimal system was done. In sac syringing where resistance to saline flow and regurgitation from opposite punctum was seen, nasolacrimal duct obstruction confirmed. Rigid nasal endoscopy was done in all patients. This procedure allowed septal deviation and any additional nasal or sinus pathologic conditions to be evaluated and so that can be corrected simultaneously with DCR or prior to it if required. Patients with evidence of lacrimal sac tumor, canalicular obstruction, dacryolith or traumatic obstruction were excluded from the study. Surgery was done in patients of chronic dacryocystitis or after resolution of acute inflammation. Informed consent regarding surgery and anesthesia obtained in all patients. Majority of patients were operated under local anesthesia. Patients below 18 years were operated under general anesthesia. The nasal cavity were packed with gauze strips soaked in 4% lignocaine with adrenaline (1: 1,00,000) 20 minutes prior to procedure. So we could achieve mucosal anesthesia and good vasoconstriction that improves patients' co-operativity and helps in bloodless field. Surgery was carried out by 0° endoscope. Lignocaine 2% with adrenaline 1: 1,00,000, injected anterior and above to the anterior attachment of middle turbinate.

Circular incision was kept anterior to the uncinata process with sickle knife. Mucosal flap was raised with freer elevator and frontonasal process of maxilla; lacrimal crest and lacrimal bone were exposed. Frontonasal process of maxilla was removed with Kerrison's straight and curved punches or by drilling to expose the lacrimal sac. The bony defect was widened circumferentially and lacrimal sac exposed adequately. The punctum was dilated with punctum dilator. Lacrimal probe was passed through the punctum and sac was confirmed by pressure effect of probe on sac. Then medial wall of the sac was incised with sickle knife or 11 no. blade and partially removed and marsupialised or completely removed. Syringing confirmed the patency of the stoma.

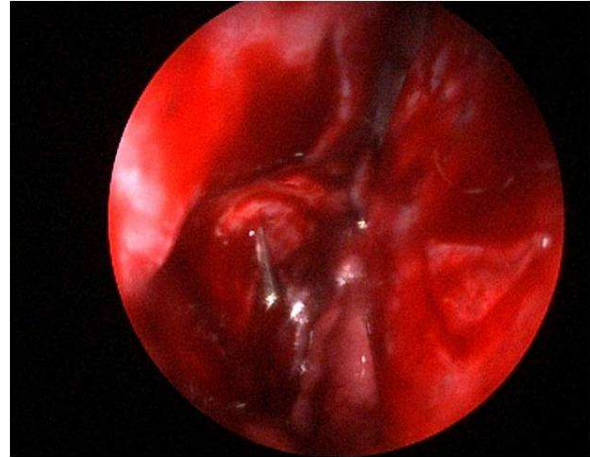
In patients of Group – A, stenting was done. For that we used prepackaged sets consisting of silicone tubes attached to metal probes. Metal ends of silicone tubes were passed through upper and lower canalicula into the sac, pulled out and tied in nasal cavity. Nasal cavity was packed with gelfoam or ointment soaked small wick for few hours. In Group – B, stenting was not done. Post operative oral antibiotics, decongestants and antibiotic with steroid eye drops were given to all patients. Follow up was done after 1 week, 15 days, 1 month, 3 months, 6 months and 1 year after surgery. Stents were usually removed at 4–8 weeks postoperative visit. Average intubation time was 6.1 weeks. On follow up, patients were assessed in terms of anatomical patency and symptom relief. **(Photo – 1)**

Results

In this retrospective study, comparison of the outcome of stenting (Group - A) v/s non stenting (Group - B) in 39 consecutive patients who underwent endonasal DCR between January 2011 to July 2014 was done. There were more

female patients – 28 (71.79%) than male patients – 11 (28.20%). The mean age was 40.44 years. Age range was 14–74 years as per **Table - 1**.

Photo – 1: Endoscopic DCR.



Both eyes were almost equally affected. Left eye was affected in 16 patients compared to 17 patients had right eye involvement. 6 patients had bilateral symptoms of which one eye was operated at a time. Revision cases included our own revision of endoscopic DCR without stenting 2 (5.12%) and of endoscopic DCR with stent 1 (2.5%). 4 of these patients had atrophic rhinitis, which was preoperatively controlled by appropriate medical treatment. 11 of these patients had deviated nasal septum in which 5 patients had undergone correction simultaneously. In our own revision cases of Endoscopic DCR with stent, the cause was synechiae formation as simultaneous septoplasty with stenting was done. Revision cases of Endoscopic DCR without stenting the causes were granulations and stoma closure. During revision surgery stenting was done. Regular follow up was maintained for 6 months to 2 years and complications like granulations, adhesions, stoma closure were faced in cases where stent was not inserted. Although no definite time frame for stent retention has been established. It has been suggested that the



silicone stent should remain in place for 6 to 12 months following surgery [5]. In this study, stents were removed after an average of 1–3 months. There were no major complications. We believed stenting is necessary in every patient and regular follow up should be maintained. At the end of this study, 76.92% patients were relieved of these symptoms completely. Success rate of endonasal DCR of Group – A, and Group - B at 6 months follow up was as per **Table – 2**.

Discussion

Dacryocystorhinostomy (DCR) is performed in cases of nasolacrimal duct obstruction to drain the lacrimal sac in chronic dacryocystitis [6]. DCR with or without stenting has been used widely in the treatment of NLD obstruction. There is some controversy regarding placement of stent during DCR surgery. Allen and Berlin reported a higher failure rate when stents were used [3]. Vishwakarma, et al. had a high success rate with silicone tubing [7]. During the study, we noted that the failure of endoscopic DCR especially in cases where no stent was used, were because of granulations and scarring near stoma. Technical error in locating the sac, intra operative bleeding hampering the vision or small obliterated atrophic sac or impaired canalicular function also leads failure of DCR. Endocanicular stenting is believed to maintain the patency of the ostium during the post operative period & healing process.

Conclusion

Endoscopic DCR is a simple, minimally invasive procedure. In our study, we concluded that endoscopic DCR with stent placement had good results. Regular follow up after endoscopic DCR is necessary. Endoscopic DCR with stent has

several advantages over classical external approach.

References

1. Caldwell G. W. Two new operations of obstructions of the nasal duct with preservation of the canaliculi & an incidental description of a new lacrimal probe. *Am J Ophthalmol*, 1893; 10: 189-93.
2. Mc Donogh M, Meiring JH. Endoscopic transnasal Dacryocystorhinostomy. *J Laryngol otol*, 1989; 103: 585-7.
3. Allen K, Berlin AJ. Dacryocystorhinostomy failure; association with nasolacrimal silicone intubation. *Ophthalmic Surg*, 1989; 20: 486-9.
4. Anderson RL, Edwards JJ. Indications, complications & results with silicone stents. *Ophthalmology*, 1979; 86: 1474-87.
5. Mathew G, Mc Gwin, Boyle M. The consequence of premature silicone stent loss after external Dacryocystorhinostomy. *Ophthalmology*, 2008; 115: 1241-124.
6. Harvindes S, Rosalind S, Philip R. Powered Endoscopic Dacryocystorhinostomy with mucosal flaps without stenting. *Med J Malaysia*, 2008; 63: 237-238.
7. Vishwakarma R, Singh N, Ghosh R. A study of 272 cases of endoscopic DCR. *Indian J Otolaryngol Head Neck Surgery*, 2004; 56: 259-261.

Source of support: Nil

Conflict of interest: None declared.



Table – 1: Age distribution of cases.

Age (in years)	10-20	20-30	30-40	40-50	50-60	60-70
No. of cases	1	3	11	16	7	1
%	2.56	7.69	28.20	41.02	17.94	2.56

Table – 2: Success rate of endonasal DCR of Group – A, and Group - B at 6 months follow up.

Group	Total (n = 39)	Success rate at 6 months	Failure rates at 6 months
Group A	25	22 (88%)	3 (12%)
Group B	14	8 (57.14%)	6 (42.85%)