

Original Research Article

Clinical study of otological manifestations among children with cleft palate from a tertiary care teaching hospital

Ziauddin Ahmad¹, Abhishek Singh^{2*}, Shewtank Goel³, Aakansha Gupta⁴, Sanjeet Panesar⁵, Avinash Surana⁶, Deepak Pathania⁷, Amit Kumar Singh³, Mohd. Shadab Shamsi³, Lalit Kumar Singh⁸

¹Assistant Professor, Department of ENT, MSDS Medical College, Fatehgarh, Uttar Pradesh, India

²Assistant Professor, Department of Community Medicine, SHKM Govt. Medical College, Mewat, India

³Assistant Professor, Department of Microbiology, MSDS Medical College, Fatehgarh, Uttar Pradesh, India

⁴Tutor, Department of Microbiology, MSDS Medical College, Fatehgarh, Uttar Pradesh, India


⁵Senior Resident, Department of Community Medicine, VM Medical College and Safdarjung Hospital, New Delhi, India

⁶Assistant Director Health, 19 Inf. Div., India

⁷Assistant Professor, Department of Community Medicine, MMIMSR, Mullana, India

⁸Assistant Professor, Department of Sociology, Government Degree College, Gonda, Aligarh, India

*Corresponding author email: abhishekparleg@gmail.com

	International Archives of Integrated Medicine, Vol. 2, Issue 7, July, 2015.	
	Copy right © 2015, IAIM, All Rights Reserved.	
	Available online at http://iaimjournal.com/	
	ISSN: 2394-0026 (P)	ISSN: 2394-0034 (O)
	Received on: 23-05-2015	Accepted on: 28-06-2015
	Source of support: Nil	Conflict of interest: None declared.

Abstract

Background: Despite having a well documented relationship of cleft palate with middle ear effusion, little data exists regarding otopathology in Indian children with cleft palate.

Objectives: Therefore, the present study was planned with an objective to determine the various otological manifestations that occur in patients with cleft palates seeking care at a tertiary care teaching hospital.

Material and methods: The present study was carried out in the Department of Otorhinolaryngology of a tertiary care teaching hospital of northern India during June 2012 to May 2014 among 30 cases of cleft palate. On the first visit, history and thorough clinical examination are undertaken. Next, common and special investigations are undertaken to evaluate and assess the status of disease. X-ray mastoids, Pure tone audiometry and Tympanometry were also carried out.

Results: The ears are found affected in 86.7%, 60.1% ears had an intact but dull tympanic membrane whereas 16.7% ears had CSOM with a central perforation. On pure tone audiogram (n=18) 33.33% had a hearing loss in one ear and 44.44% had a hearing loss in both ears in the form of a mild or moderate degree of conductive deafness. On tympanogram, 23.3% had an 'A' type of tympanogram whereas 44 ears had a 'B' type of tympanogram indicative of recurrent effusions in the middle ear. Majority from this sub-group >80% had associated conductive hearing loss-mild to moderate degrees.

Conclusion: Cleft palate individuals should always be evaluated for possible otological manifestations.

Key words

Cleft palate, Otitis media with effusion, Eustachian tube dysfunction.

Introduction

Cleft palate is the failure of fusion of the roof of the mouth, resulting in an inappropriate communication between the oral and nasal cavities. These disorders can result in feeding problems, speech problems, hearing problems, and frequent ear infections. Less than half the time the condition is associated with other disorders. The cause in most cases is unknown [1]. Risk factors include smoking during pregnancy, diabetes, an older mother, obesity, and certain medications such as some used to treat seizures. They can often be diagnosed during an ultrasound done during pregnancy. The management of cleft affected children is a multidisciplinary affair with inputs from various specialties [2].

This failure of separation of the cavities results in an increased incidence of aspiration of milk and consequently inhalation pneumonia. Cleft palate may be due to hereditary or non-hereditary causes. This condition is commonly associated with arthrogyrosis, or "crooked calf disease", which can be caused by a number of factors, including toxic plants (tobacco, locoweed, poison hemlock, veratrum californicum), Akabane Virus, and Bluetongue Virus [3]. Milder cases of cleft palate without accompanying musculoskeletal defects may have a hereditary component [4, 5].

Despite having a well documented relationship of cleft palate with middle ear effusion [6], little data exists regarding otopathology in Indian

children with cleft palate. It is observed clinically that a high number of children with non-syndromic cleft palate may have external ear abnormalities. Therefore, the present study was planned with an objective to determine the various otological manifestations that occur in patients with cleft palates seeking care at a tertiary care teaching hospital. Additional objectives were to evaluate the severity of the manifestations with relation to the various types of clefts and to obtain a statistical data for the same as found in the local population.

Material and methods

The present study was carried out in the Department of Otorhinolaryngology of a tertiary care teaching hospital of northern India during June 2012 to May 2014. Thirty such cases seeking care for cleft palate (with or without cleft lip) were included in the study. On the first visit, history and thorough clinical examination are undertaken. Next, common and special investigations are undertaken to evaluate and assess the status of disease. The cases with only a cleft lip were excluded. Hearing assessment was done in children older than 5 yrs by a voice test (whispering test and conversational voice test) and routine tuning fork tests. In children who were younger, hearing was tested by distracting the child towards a noise (clap).

Regarding investigations carried out in these subject; X-ray mastoids (both sides) Lateral oblique view – to detect the pneumatization of the mastoid air cell system, Pure tone audiometry

- (in children older than 5 years) - to get documented and subjective assessment of hearing status, and Tympanometry - to get an assessment of eustachian tube function in all age groups.

All the questionnaires were manually checked and edited for completeness and consistency and were then coded for computer entry. After compilation of collected data, analysis was done using Statistical Package for Social Sciences (SPSS), version 20 (IBM, Chicago, USA). The results were expressed as proportions. Interpretation of the collected data was done by using appropriate statistical methods.

Results and Discussion

Thirty cases of cleft palates with or without cleft lips were studied and evaluated with aforementioned investigations. Males (20, 66.67%) outnumbered females (10, 33.33%) in this study. The result of this study is in agreement with previous study from Kolkata [7].

Regarding age of study subjects, majority (n=10) of the patients in this study belonged to the age group of 2-5 years. Six patients each belonged to the 1-2 years and 5-10 years age group respectively. Two infants were found in the study; five patients were in the 10-20 years age group and one patient were greater than 20 years in which one was sub mucus cleft patient while the other had an incomplete midline cleft of the secondary palate that had not been repaired till date. Actually there is lack of uniformity of the age of participants in previous studies, and there is also a lack of age stratified data available in the literature.

The ears are found affected in (26, 86.7%) of cleft palate individuals. Only 8 ears i.e. 4 subjects (13.3%) were found to be normal with an intact pearly white tympanic membrane and demonstrable landmarks. Thirty six (60.1%) ears had an intact but dull tympanic membrane whereas 10 (16.68%) ears had Chronic Suppurative Otitis Media (CSOM) with a central

perforation and one patient had attic pathology with cholesteatoma (**Table - 1**) which had an eustachian tube dysfunction with a negative middle ear pressure.

Another author reported the presence of Eustachian tube dysfunction in 84% of cleft patients. According to him, this dysfunction decreases with the age of the patient [8]. He further stated that 7.1% of such patients develop cholesteatomas despite regular otological examination. Robinson P.J. observed that ventilation tube insertion in cleft patients is associated with a larger mastoid air cell system than the nonventilated side [9].

Cellularity of mastoid bone is an indicator of middle ear infection. Individuals who suffer from repeated middle ear infections have a proportionate loss of cellularity of their mastoid air cell system [10]. It was observed in this study that 12 (40.0%) individuals had pneumatic mastoid air cells. Majority of these individuals had clefts of the primary palate or a sub mucous cleft palate. Ten study subjects (33.3%) had a diploic mastoid evident on a lateral oblique skiagram while eight (22.67%) individuals had sclerotic mastoids.

Authors have reported a greater incidence of hearing loss in patients with cleft palate [11]. In the current study hearing loss was recognized by a pure tone audiogram in individuals >5 years of age. 18 patients fulfilled this criterion and of them four (22.22%) had normal hearing. Six (33.33%) had a hearing loss in one ear and eight subjects (44.44%) had a hearing loss in both ears in the form of a mild or moderate degree of conductive deafness. (**Figure - 1**)

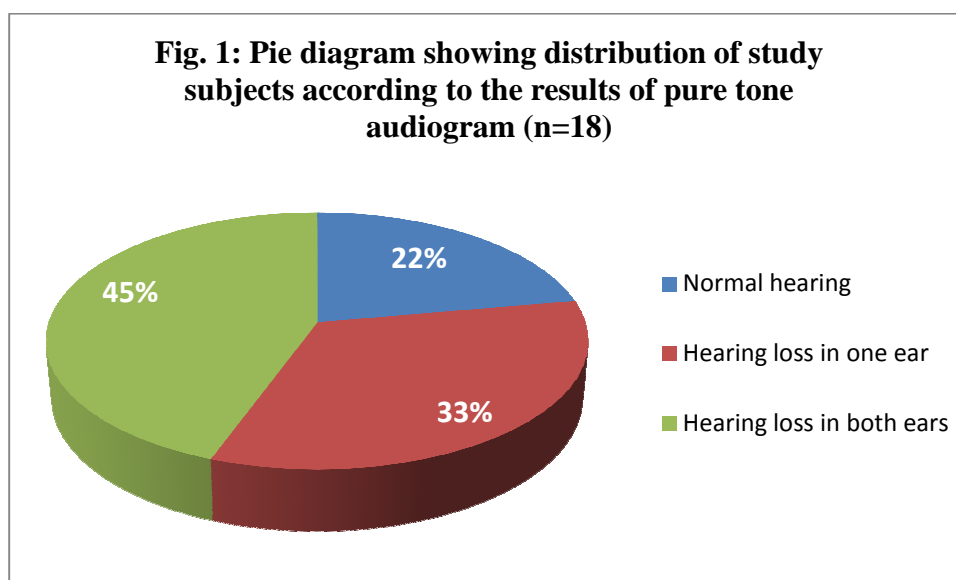
Another author reported that 96.2% of the patients of cleft palate develop middle ear disease significant enough to require tympanostomy tubes [12]. Regarding study of the tympanogram, it was found that only 14 ears (23.3%) (out of a total of 60 ears in 30 patients) had an 'A' type of tympanogram whereas 44 ears (73.3%) had a 'B' type of tympanogram

indicative of recurrent effusions in the middle ear. Majority from this sub-group >80% had associated conductive hearing loss-mild to moderate degrees. Two ears had a 'C' type of

curve indicating frank eustachian tube dysfunction with negative middle ear pressure. On examination, patient showed retracted eardrum with cholesteatoma.

Table - 1: Distribution of study subjects according to the findings of otoscopic examination.

Otosopic Findings		Number of Ears	Number of patients	Percentage	
Absent	Normal Tm	8	4	13.3	
Present	Dull intact Tm	36	18	60.10	86.7
	Retraction/Frank OME	4	2	6.68	
	CSOM with central perforation	10	5	16.68	
	CSOM with attic pathology	2	1	3.33	
Total		60	30	100	



Conclusion

It can be concluded on the basis of findings of current study that the most common age group to present with the ontological problem in cleft palates is 2-5 years, a significant number of patients with cleft palate have middle ear effusion and infection leading to sclerotic changes in their mastoid air cell system, significant numbers of such individuals have Eustachian tube dysfunction, majority of such individuals have hearing loss. Therefore to conclude cleft palate individuals should always be evaluated for possible otological manifestations.

References

1. Cummins CW. Otolaryngology and Head Neck Surgery. 3rd edition. Mosby: Cleft Lip and Palate.
2. Grabb WC. General aspects of cleft palate surgery. Little, Brown: Boston; 1971.
3. Rajjon ZA, Alwi Z. Genetics of Cleft Lip and Palate: A Review. Malaysian Journal of Medical Sciences, 2007; 14(1): 4-9.
4. Seno S, Kamide Y, Schacharn PA, Paparella MM. Micropathologic changes of pars tensa in children with otitis media with effusion. Arch Otolaryngol Head Neck Surg, 1994; 120: 815-9.

5. Ludman H, Wright T. Diseases of the ear, 6th edition, 1998.
6. Wormald PJ. Clinical Examination of the ears and hearing. In: Gleeson M, Browning GG, Burton MJ, Clarke R, Hibbert J, Jones NS et al. Scott Brown's Otolaryngology, Head and Neck Surgery. 7th edition. Great Britain: Hodder Arnold; 2008, p. 3311–3319.
7. Khan SY, Pal R, Sengupta A, Roy P. Clinical study of otological manifestations in cases of cleft palate. IJOHNS, 2006; 58 (1): 35–37.
8. Severeid LR. Development of cholesteatomas in children with cleft palate. In: McCabe BF, Sade J, Abramson M editors. Cholesteatoma: First International Conference, Aesculapius: Birmingham; 1977, p. 287-92.
9. Robinson PJ. Secretory otitis media and mastoid air cell development. Int J Paediatr Otolaryngol, 1991; 25: 13-8.
10. Friedman O, Wang TD, Milczuk HA. Cleft Lip and Palate. In: Cummings CW, Flint PW, Harker LA, Haughley BH, Richardson MA, et al. editors. Otolaryngology Head & Neck Surgery. Fourth edition. Philadelphia: Mosby; 2005; p. 4052–4085.
11. Goudy S, Lott D, Canady J, Smith RJH. (2006) Conductive hearing loss and otopathology in cleft palate patients. Otolaryngology– Head and Neck Surgery, 2006; 134: 946–948.
12. Muntz HR. An overview of middle ear disease in cleft palate children. Fac Plast Surg, 1993; 9: 177.