


Case Report

Atypical (Symplastic) Leiomyoma – A case report

Lakshmbai B. Mallappa^{1*}, Basavaraj H. Talawar²,
Narasimhamurthy V², Dayananda S. Biligi³

¹Assistant Professor, ²Post graduate students, ³Professor and Head
Department of Pathology, Bangalore Medical College and Research Institute, Bangalore, Karnataka,
India

*Corresponding author email: lakshmbalal.krishna@gmail.com

	International Archives of Integrated Medicine, Vol. 2, Issue 8, August, 2015. Copy right © 2015, IAIM, All Rights Reserved. Available online at http://iaimjournal.com/	
	ISSN: 2394-0026 (P)	ISSN: 2394-0034 (O)
	Received on: 24-06-2015	Accepted on: 24-07-2015
	Source of support: Nil	Conflict of interest: None declared.

Abstract

Atypical, bizarre, symplastic (symplastic), or pleomorphic leiomyoma contains bizarre tumor cells with variation in size and shape, hyperchromatic nuclei, giant cells and occasional multinucleated giant cells but no coagulative necrosis or increased mitotic activity. Mitotic counts higher than 10/10hpf in such a tumor indicates a high malignant potential smooth muscle tumor (leiomyosarcoma). Bizarre leiomyoma closely mimics leiomyosarcoma. We report a case of 31 years old, nulliparous woman who presented with a history of infertility. On examination she was found to have uterine fibroid of 28 weeks size over a period of 5 years. She was diagnosed to have fibroid clinically and on ultrasonographic examination. Hence, a myomectomy was performed. Histomorphological features are of atypical (Symplastic) leiomyoma which closely mimics leiomyosarcoma and immunohistochemical markers are certainly of help to exclude malignancy in case of dilemma.

Key words

Atypical leiomyoma, mitotic activity, multinucleated giant cells, immunohistochemical markers.

Introduction

Leiomyomas are by far the most frequent mesenchymal uterine neoplasms. Leiomyoma variants refer to a particular histological differentiation and growth pattern. Atypical and bizarre leiomyoma synonymous with symplastic leiomyoma, are rare smooth muscle tumors that

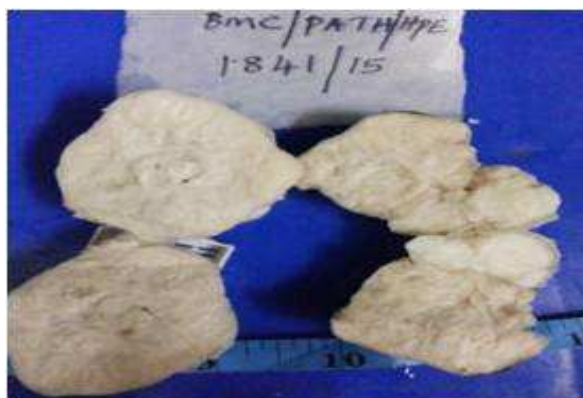
contain cells with moderate to severe cytological atypia but cell necrosis is absent and mitotic index is fewer than 10 /10 hpf [1]. The features like average age of patient at presentation and maximum tumor size are identical to those of common leiomyoma but clinical behavior and prognosis of these rare tumors depends on

number of mitotic figures [2]. Mitotic counts higher than 10 in such a tumor indicate a high malignant potential smooth muscle tumor (leiomyosarcoma) [3]. Symplastic leiomyoma has been diagnosed in different sites other than uterus like vagina, nasal cavity and in scrotum [4]. This case report describes the occurrence of symplastic leiomyoma in a young lady with primary infertility.

Case report

We have reported here a case of 31 years old, nulliparous woman who presented with history of infertility. On examination, she was found to have uterine fibroid of 28 weeks size over a period of 5 years. Abdominal ultrasound scan showed uterus measuring 12x10x8 cm with intramural fibroid measuring 4 cm in diameter. Myomectomy was performed and subjected to histopathological and immunohistochemical examination using markers MIB1(Ki 67 antigen), Calponin-h1 and Desmin. Gross features of the specimen correlated with the findings of ultrasound. (Figure – 1)

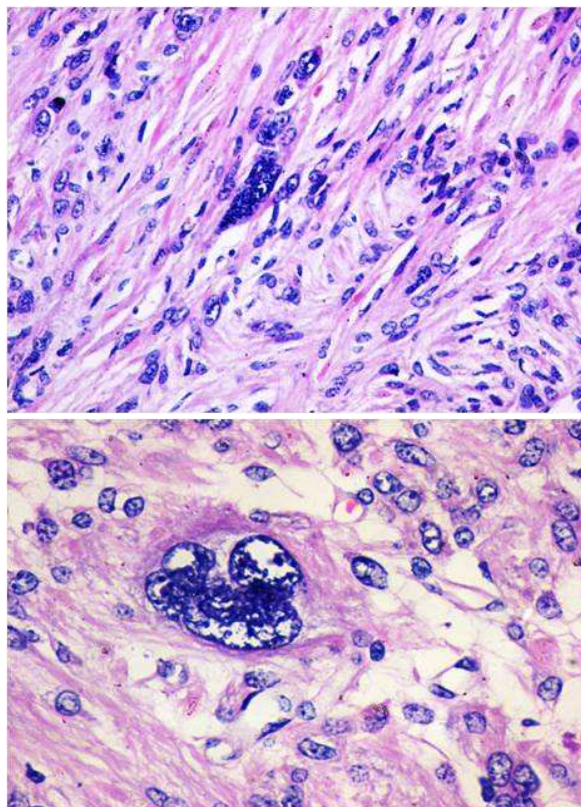
Figure - 1: Cut section shows grey-white intramural fibroid.



Microscopy revealed endometrial glands in secretory phase. Myometrium showed intramural leiomyoma composed of bizarre spindle shaped cells with vesicular nuclei showing moderate to severe pleomorphism arranged diffusely and in fascicles. Presence of bizarre giant cells was the most striking feature. Good number of cells showed prominent nucleoli. Few cells showed

intranuclear inclusion bodies. Tumor cells showed mitotic activity of less than four / ten high power field (hpf). (Figure – 2, 3)

Figure – 2 (H & E 200X) and Figure – 3 (H & E 400X): Bizarre spindle shaped cells with vesicular nuclei showing moderate to severe pleomorphism arranged in fascicles and presence of bizarre giant cells.



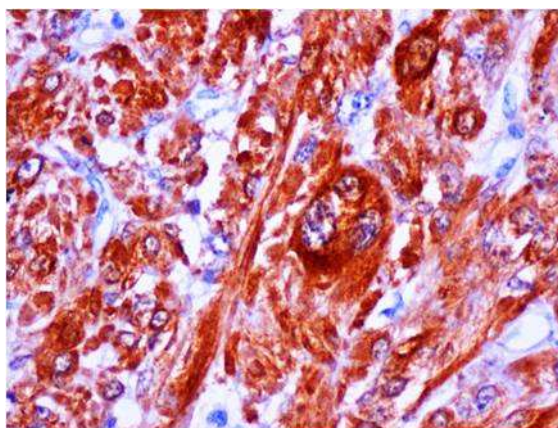
Immunohistochemical report revealed highly intensive positivity for Calponin h1 (Figure - 4) along with negative expression of MIB 1 (Ki 67) antigen (Figure - 5) supporting the benign nature of Atypical (Symplastic) Leiomyoma.

Discussion

In 1961, Przybora introduced the term 'leiomyosarcoma in situ' for a group of 15 uterine smooth muscle tumors in which distinct atypical cells including multinucleate giant cells were found within an otherwise simple myoma [5]. He postulated that leiomyosarcoma in situ is a transitional phase in the development of a fully malignant sarcoma, analogous to carcinoma in

situ (this concept has subsequently been disregarded). Further studies with uterine smooth muscle tumors with atypical histological features, including multinucleate tumor giant cells of the symplastic type but without mitotic activity have recognized their clinically benign course [6, 7]. To distinguish between benign and malignant lesions, and lesions of uncertain potential, histological criteria as well as different immune histochemical markers e.g. MIB1 (Ki 67 antigen), Calponin h1 and Desmin expression are being used. Over expression of MIB 1 (Ki 67 antigen) along with reduced expression of Calponin h1 and Desmin expression have high sensitivity for leiomyosarcoma differentiating them from benign variants of leiomyoma and tumors of uncertain malignant potential [8, 9, 10, 11]. In the present case, MIB1 (Ki 67) shows negative expression. Calponin-h1 shows high intense positivity. Ünver NU, et al. in their studies concluded that p16 and p21 may be of value as an adjunct to conventional morphologic criteria in the assessment of problematic uterine smooth muscle tumors [12].

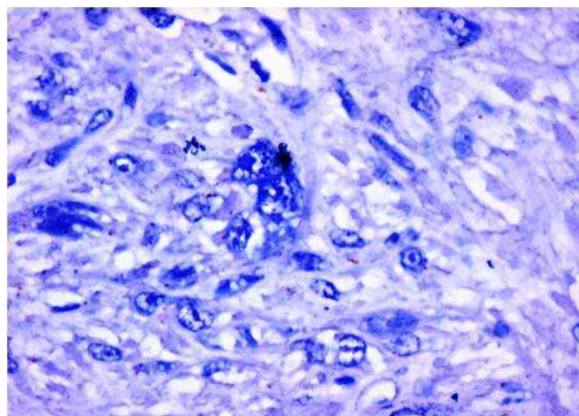
Figure - 4: highly intensive positivity for Calponin h1 (400X)



Conclusion

Atypical (Symplastic) leiomyoma is a rare tumor of uterine smooth muscles. Histomorphological features of atypical (Symplastic) leiomyoma closely mimics leiomyosarcoma and immune histochemical markers are certainly of help to exclude malignancy in case of dilemma.

Figure - 5: Negative expression of MIB 1 (Ki 67) antigen.



References

1. Bell SW, Kempson RL, Hendrickson MR. Problematic uterine smooth muscle neoplasms: A clinicopathologic study of 213cases. *Am J Surg Pathol*, 1994; 18: 535-58.
2. Rammeh-Rommani S, Mokni M, Stita W, Trabelsi A, Hamissa S, Sriha B, et al. Uterine smooth muscle tumors: Retrospective epidemiological and pathological study of 2760 cases. *J Gynecol Obstet Biol Reprod (Paris)*, 2005; 34: 568-71.
3. Perrone T, Dehner LP. Prognostically favorable "mitotically active" smooth-muscle tumors of the uterus. A clinicopathologic study of 10 cases. *Am J Surg Pathol*, 1988; 12: 1-8.
4. Kim NR, Saug CO, Han J. Bizarre leiomyoma of the scrotum. *J Korean Med Sci*, 2003; 18: 452-4.
5. Przybora LA. Leiomyosarcoma in situ of the uterus. *Cancer*, 1961; 14: 483-92.
6. Downes KA, Hart WR. Bizarre Leiomyomas of the Uterus: A Comprehensive Pathologic Study of 24 cases with long- term follow- up *Am J Surg Pathol*, 1997; 21: 1261-70.
7. Christopherson WM, Williamson EO. Leiomyosarcoma of the uterus. *Cancer*, 1972; 29: 1512-7.
8. O'Neill CJ, McBride HA, Connolly LE, McCluggage WG. Uterine

leiomyosarcomas are characterized by high p 16, p 53 and MIB1 expression in comparison with usual leiomyomas, leiomyoma variants and smooth muscle tumours of uncertain malignant potential. *Histopathology*, 2007; 50: 851-8.

9. Bodner-Adler B, Bodner K, Czerwenka K, Kimberger O, Leodolter S, Mayerhofer K. Expression of p16 protein in patients with uterine smooth muscle tumors: an immunohistochemical analysis. *Gynecol Oncol*, 2005; 96: 62-6.
10. Horiuchi A, Nikaido T, Ito K, Zhai Y, Orii A, Taniguchi S, et al. Reduced expression of calponin h1 in leiomyosarcoma of the uterus. *Lab Invest*, 1998; 78: 839-46.
11. Mayerhofer K, Lozanov P, Bodner K, Bodner-Adler B, Kimberger O, Czerwenka K. Ki-67 expression in patients with uterine leiomyomas, uterine smooth muscle tumors of uncertain malignant potential (STUMP) and uterine leiomyosarcomas (LMS). *Acta Obstet Gynecol Scand*, 2004; 83:1085-8.
12. Ünver NU, Acikalin MF, Öner Ü, Ciftci E, Ozalp SS, Colak E. Differential expression of P16 and P21 in benign and malignant uterine smooth muscle tumors. *Arch Gynecol Obstet.*, 2011; 284(2): 483-90.