

Original Research Article

Consistency and percentage agreement of preoperative surface marking of subcutaneous foreign body by colour comet tail artefact with its intra-operative positional findings - A prospective study

Kashi Nath Sarkar^{1*}, Sumanta Kumar Mandal², Pranay Kabiraj³, Rikta Mallik⁴, Dileep Kumar Gupta⁵, Manisha Sarkar⁶

¹Junior Resident II, Department of Radio diagnosis, Bankura Sammilani Medical College, Bankura, West Bengal, India

²Associate Professor, Department of Radio diagnosis, Bankura Sammilani Medical College, Bankura, West Bengal, India


³Junior Resident III, Department of Surgery, Bankura Sammilani Medical College, Bankura, West Bengal, India

⁴Assistant Professor, Department of Radio diagnosis, Bankura Sammilani Medical College, Bankura, West Bengal, India

⁵Intern, Department of Surgery, Bankura Sammilani Medical College, Bankura, West Bengal, India

⁶Junior Resident III, Department of Community Medicine, Medical College, Kolkata, India

*Corresponding author email: drkashisarkar@gmail.com

	International Archives of Integrated Medicine, Vol. 3, Issue 6, June, 2016.	
	Copy right © 2016, IAIM, All Rights Reserved.	
	Available online at http://iaimjournal.com/	
	ISSN: 2394-0026 (P)	ISSN: 2394-0034 (O)
	Received on: 16-05-2016	Accepted on: 25-05-2016
	Source of support: Nil	Conflict of interest: None declared.
How to cite this article: Sarkar KN, Mandal SK, Kabiraj P, Mallik R, Gupta DK, Sarkar M. Consistency and percentage agreement of preoperative surface marking of subcutaneous foreign body by colour comet tail artefact with its intra-operative positional findings - A prospective study. IAIM, 2016; 3(6): 32-41.		

Abstract

Background: Exact surface localization of foreign body is vital prior to its surgical removal. Preoperative localization errors lead to excessive soft tissue exploration, prolonged surgery, increased morbidity and post-surgical complications.

Aim: Determination of percentage agreement of preoperative surface marking of subcutaneous foreign body by colour comet tail artefact with its intra-operative positional findings.

Materials and methods: Prospective observational study was conducted on 100 patients over duration of eight months from September 2015 to April 2016 at our institution. Preoperative surface marking of foreign body was done using Ultrasound machine PHILIPS HD7 (2.0.1) with 7 MHz linear transducer, Excel mark premium black stamp ink 2oz, Acco smooth steel wire paper clip, Trade mark 45 cm wooden measuring scale and Apsara glass marking pencil. Percentage agreement of preoperative surface marking of subcutaneous foreign body by colour comet tail artefact with its intra-operative positional findings was studied in 100 patients prospectively. All analysis was done by using IBM SSPS statistics 24 and MS Excel.

Results: The color tail artifact technique showed percentage agreement of 93.5% for accurate surface marking of vertical line within ≤ 5 mm of actual location and percentage agreement of 92.5% for surface marking of horizontal line within ≤ 5 mm of actual location.

Conclusions: Blind surgical procedures of foreign body removal have been replaced by real time ultrasound guided removal under strict sterile conditions in most of the affluent nations. However in developing nations and semi urban places where there is limited and underrated sterilization and disinfection technique, real time ultrasound procedures for foreign body removal remains a challenging option. This study shall suffice to the needs of developing nations and semi urban places with precise preoperative surface localization, advantages of minimal surgical exploration, minimal local tissue injury, reduced patient's morbidity and no real time ultrasound associated nosocomial infection. The study shall also be helpful with special emphasis to those underserved villages where surgeons still rely on blind foreign body removal procedures, causing massive tissue exploration, increased hospital stay, increased cost of treatment, failure of removal and increased patients morbidity.

Key words

Colour comet tail artefact, Preoperative "H" shaped surface marking, Intra-operative consistency, Vertical displacement, Horizontal displacement, Foreign body.

Introduction

Foreign bodies are an object of extraneous matter that has entered the body during accidental injuries viz. household trauma, road traffic accidents, explosions, ammunitions etc. Low radiopaque foreign bodies such as woods, thorns and sands which are among the common accident site flora, are rarely detected on plain radiography [1-9]. These persisting and undetected foreign bodies may remain asymptomatic or else can present with inflammation, pain, allergies, wound site infection, abscess, granuloma, necrotizing fasciitis, chronic discharging sinus and continued morbidity [1-9]. Even though for deeply located and radio-opaque foreign bodies, CT provides better delineation of its location, high frequency

ultrasound shows a sensitivity and specificity of 92% and 95% respectively in detection of superficial foreign body (within 3 cm depth) [1-9]. Small foreign bodies may migrate from its entry site and are difficult to locate owing to its small size. Exact surface localization of foreign body is vital prior to its surgical removal. Preoperative localization errors lead to excessive soft tissue exploration, prolonged surgery, increased morbidity and post-surgical complications. In our study done on 100 patients with high frequency ultrasound showing foreign bodies, we describe a simple technique based on colour comet tail artefact for precise surface localization of foreign body, and evaluating percentage agreement of preoperative surface marking of subcutaneous foreign body with its intra-operative positional findings. The study

shall be a boon for those hospitals not having access to computed tomography or are not having adequate sterilization to carry out real time ultrasound guided removal of foreign body.

Materials and methods

Study was approved by institutional ethics committee and consent was obtained from all study participants. Study population included all persons in whom foreign bodies were detected on ultrasound, post referral to department of radio diagnosis, irrespective of age, gender, site, nature, dimension of foreign body and its depth (provided its visualised on ultrasound). A prospective observational study was conducted on 100 patients over duration of eight months. Ultrasound was performed on PHILIPS HD7 (2.0.1) using a 7MHz linear transducer. Surface localization was done using Excel mark premium black stamp ink 2oz, Acco smooth steel wire paper clip (**Figure - 1A**), Trade mark 45 cm wooden measuring scale and Apsara glass marking pencil. Ultrasound was conducted by radiologist with ample experience and under defined scanning parameters. First of all the patients referred from surgery department with a history of foreign body insertion were scanned using a high frequency linear transducer, ample acoustic coupling gel in the sagittal, coronal and axial planes. Precise localization was then carried out as illustrated below, in all cases where foreign bodies could be demonstrated on ultrasound in addition to determination of its size, location, depth, orientation and relation to other vital structures. On switching on the colour mode, paper clip demonstrates a focal depression and colour comet tail artefact in the acoustic window when placed between skin and the transducer (**Figure - 2A, Figure - 2B, Figure - 2C, Figure - 3A and Figure - 3B**) [1]. Paper clip is first opened from one side (**Figure - 1B**), the shorter triangular segment is held from the non-dominant hand, placing the longer triangular segment between the skin and linear transducer. The longer triangular segment of paper clip is held perpendicular to linear transducer (**Figure - 1C**). The linear transducer is held parallel and

aligned to the long axis of the foreign body. As discussed above, the paper clip produces colour comet tail artefact after switching on the colour mode (**Figure - 3A, Figure - 3B, Figure - 4A, Figure - 4B and Figure - 4C**). Identifying the relative position of paper clip based on easily demonstrable and simultaneous colour comet tail artefact, the paper clip is then moved to the area of interest, that is the longer segment of the paper clip is moved proximally keeping it perpendicular to the stationary linear transducer till colour comet tail artefact reaches the terminal most proximal end of the foreign body (point A). The linear transducer is then removed keeping the longer segment of the paper clip at the same point of proximal colour comet tail artefact. Post wiping of acoustic coupling jelly, a line (line A, **Figure - 5**) is drawn using glass marker and black ink along the axis of the longer segment of the paper clip. The same procedure is repeated to mark the distal most end of the foreign body (line B of **Figure - 5**). Placing the transducer along the axis of the foreign body, the longer triangular segment of the paper clip is now held parallel to the axis of the transducer, at either of the end, in between skin and transducer (**Figure - 4C**). During precise long axis delineation of the foreign body using colour comet tail artefact, ultrasound window is freeze at a stage, when all of the three come to lay along the same vertical axis, that is linear transducer, longer triangular segment of the paper clip identified by the colour comet tail artefact and echogenic foreign body. After wiping off the acoustic coupling jelly and keeping the linear segment of the paper clip fixed, a long vertical line C (**Figure - 5**) is drawn along its axis. While most of the foreign bodies were linear, few of them were tiny dot shaped and few were broken inside as well, depending upon the individual cases, precise surface localization was done marking one point to many lines as was best for its precise delineation. With respect to precise surface localization of foreign body, the surgeons further extended the "H" shaped marking on skin; by increasing the dimension of all lines that are line A, line B, and line C along their axis [1]. They were also

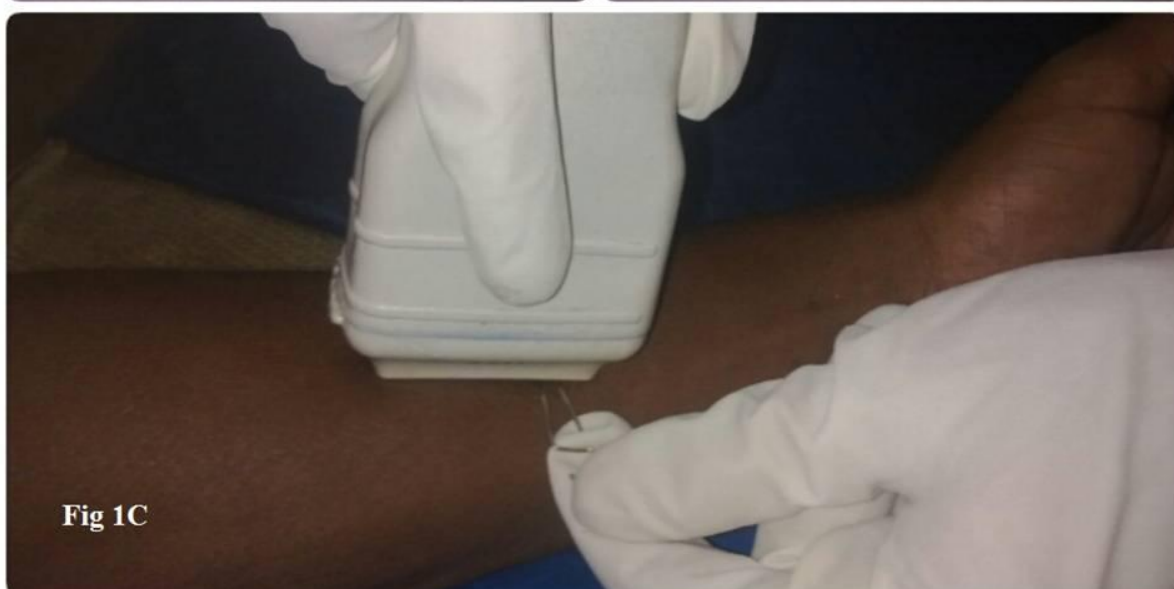
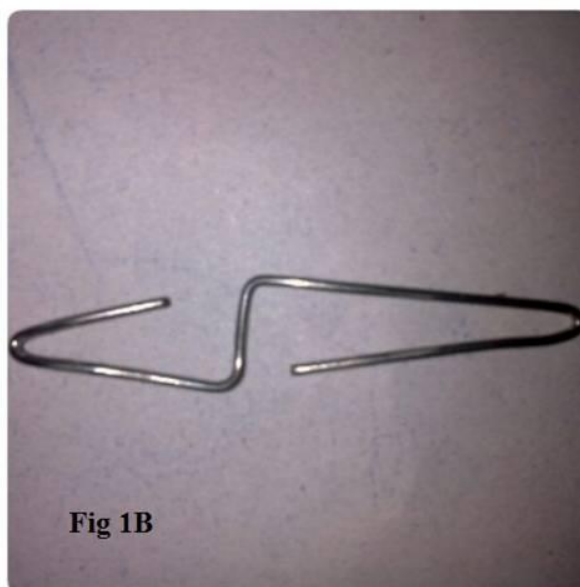provided with a simple form as illustrated in table 1 to be filled in the intra-operative and post-operative period. They noted down the intra-operative location of foreign body in terms of

vertical displacement and horizontal displacement from preoperative markings of line C and line A. (≤ 5 mm was considered positive and > 5 mm was considered negative)

Figure - 1A: Acco smooth steel wire paper clip.

Figure - 1B: Unfolded Acco smooth steel wire paper clip, shorter triangular segment is used for stable gripping to be held by non-dominant hand while longer triangular segment is placed between transducer and skin surface.

Figure - 1C: Longer triangular segment of paper clip is placed between transducer and skin at 90 degree to the transducer which is aligned along the long axis of foreign body while marking either of the proximal or distal end.



Results

A foreign body may rest itself in three different plane inside a human body that is within an air

filled cavity, within soft tissue or intramuscular plane and between muscle bone interfaces. Most of the undetected foreign bodies on radiography

were identified on ultrasound (93%) (**Figure - 6**). In our case with respect to age, mean age of presentation was 30.32 years with a standard deviation of 14.59 and 95% confidence interval of the study population were in the age group between 27.42 and 33.22 years (**Figure - 7**). Minimum reported age was 4 and maximum 90 years. 59% cases were reported in male and 41% cases were reported in female (**Figure - 8**). Prior to ultrasound evaluation, all persons were interrogated of their chief complaint. 44% of cases had foreign body sensation, 27% came with discharging sinus, 24% of cases had unexplained pain and 5% had a history of trivial foreign body injury (**Figure - 9**). Depending on age of presentation, 39% of foreign bodies were highly echogenic with posterior acoustic shadow signifying acute presentation with air trapped within material. 32% of foreign bodies had perifocal hypo echoic halo sign due to edema and granulation tissue. 29% had perifocal collection (**Figure - 10**). On surgical exploration foreign bodies were detected in 93% of cases. Ultrasound showed false positive results in 7% cases. All false positive cases had history of failed attempt of blind surgical exploration for foreign body detection subsequently leading to formation of scar tissue, air bubble or granuloma which appeared hyper echoic on ultrasound; however none had posterior acoustic shadow (**Table - 2**). Among all the foreign bodies detected at surgery, 59% were thorn, 22% were woods, 8% were glass pieces and 4% were hard plastic materials that include poly vinyl chloride, HDPE high density polyethylene and polypropylene. Remaining 7% were post-operative scar tissue, air bubble and granuloma (**Figure - 11**). Location wise, 48% of foreign bodies were located on foot, 19% on hand, 10% on leg, 6% on arm, 3% each on ankle and knee, and 2% each on forearm and thigh respectively (**Figure - 12**). The mean length of foreign body detected was 21.84 mm with a standard deviation of 12.193. 95 % confidence interval had 19.33 as lower limit and 24.35 as upper limit respectively. The smallest foreign body detected was 4 mm in length and largest 70 mm.

With respect to precise surface localization of foreign body, the surgeons further extended the “H” shaped marking on skin; by increasing the dimension of all lines that are line A, line B, and line C along their axis. They were also provided with a simple form as illustrated in **Table - 1** which they filled in the intra-operative and post-operative period. We found out that the intra-operative location of foreign body had a vertical displacement and horizontal displacement from preoperative markings line C and line A less than equal to (≤ 5 mm) in 91.4% of cases marked superficially. The same were greater than 5 mm (> 5 mm) in only 5.4%. The percentage agreement was 93.5% for accurate surface marking of line C within ≤ 5 mm of actual location (**Table - 3**). The percentage agreement was 92.5% for surface marking of line A within ≤ 5 mm of actual location as a ratio of all marked cases. (≤ 5 mm was considered positive and > 5 mm was considered negative).

Figure - 2A: Case 1 – A linear hyper echoic foreign body measuring 4.5 mm at a depth of 1.94 mm with perifocal hypo echoic halo sign.

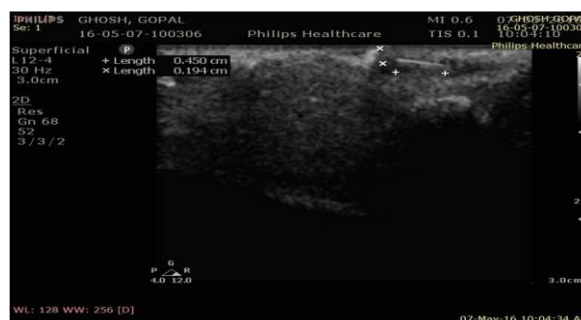


Figure - 2B: Case 2 - A thick linear hyperechoic foreign body measuring 10.9 mm at a depth of 3.9 mm with posterior acoustic shadowing.

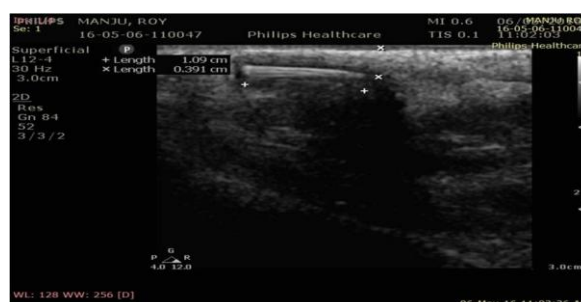

Figure – 2C: Case 3 - A tiny echogenic foreign body surrounded by perifocal halo, marked superficially as a focal echogenic depression caused by longer triangular segment of paper clip, producing posterior comet tail and reverberation artifact.

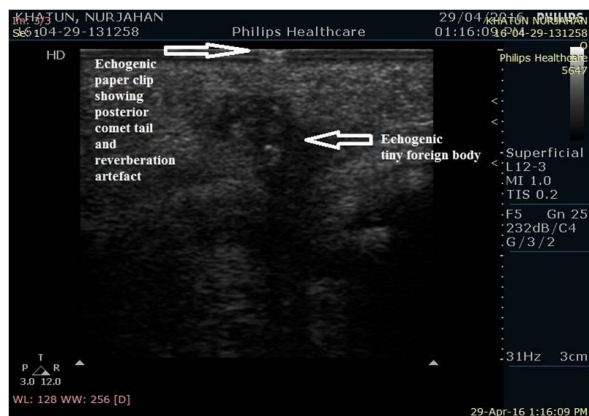
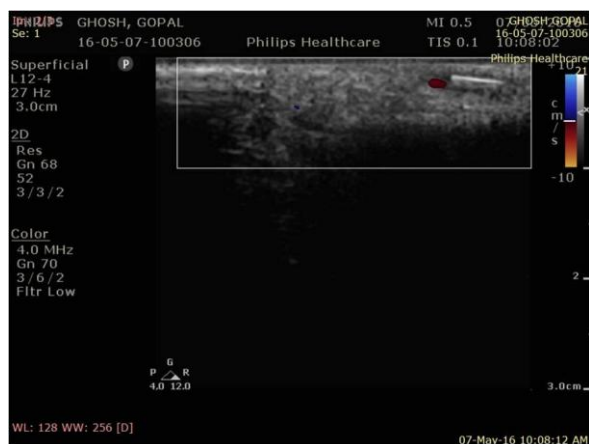
Figure - 3A: Case 1 – Proximal end of the foreign body is localized superficially by moving longer triangular segment of the paper clip, in perpendicular to the transducer, while keeping colour mode on, such that the colour comet tail artefact lies just anterior to the proximal end. The point is marked superficially as a horizontal line A.



Discussion

We have undertaken this study taking semi urban locations into consideration, where history of foreign body insertion is a common outpatient department complaint. Blind surgical procedures of foreign body removal have been replaced by real time ultrasound guided removal under strict sterile conditions in most of the affluent nations

[1-9]. However in developing nations and semi urban places where there is limited and underrated sterilization and disinfection technique, real time ultrasound procedures for foreign body removal remains a challenging option. Real time ultrasound procedures were associated with longer hospital stay due to transducer induced nosocomial infections, though had less surgical exploration. Adjacent neurovascular bundles contradicts real time procedures and necessitates open surgical removal [1-9]. This study shall suffice to the needs of developing nations and semi urban places with precise preoperative surface localization, with advantages of minimal surgical exploration, minimal local tissue injury, reduced patient's morbidity and no real time ultrasound associated nosocomial infection. The study shall also be helpful with special emphasis to those underserved villages where surgeons still rely on blind foreign body removal procedures, causing massive tissue exploration, increased hospital stay, increased cost of treatment, failure of removal and increased patients morbidity. The color tail artifact technique showed percentage agreement of 93.5% for accurate surface marking of vertical line within ≤ 5 mm of actual location and percentage agreement of 92.5% for surface marking horizontal line within ≤ 5 mm of actual location as a ratio of all marked cases.

Figure - 3B: Case 2 - Colour Comet tail artefact based surface localization of proximal end of foreign body in case 2.

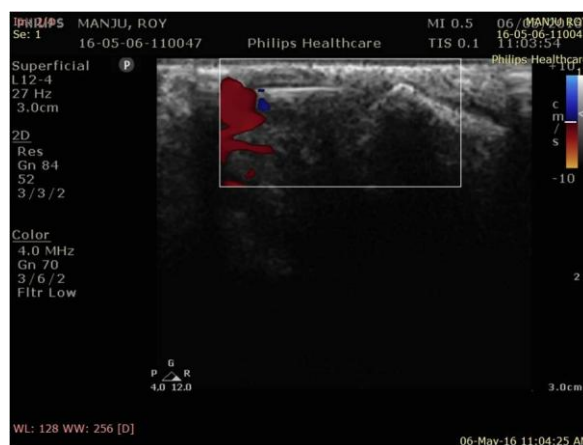


Figure - 4A: Case 1 - Colour comet tail artifact based surface localization of distal end of foreign body in case 1, thereafter marked superficially with a glass marker and black ink as line B.

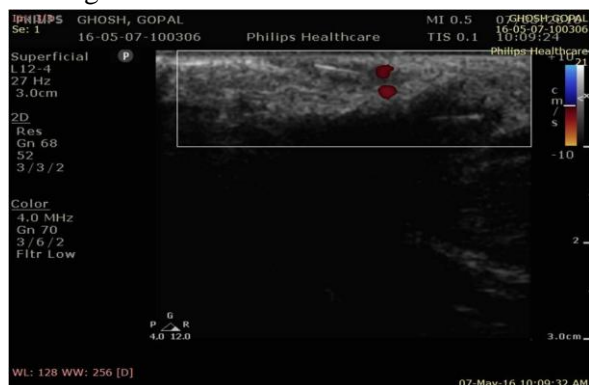

Figure - 4B: Case 2 - Colour comet tail artifact based surface localization of distal end of foreign body in case 2.

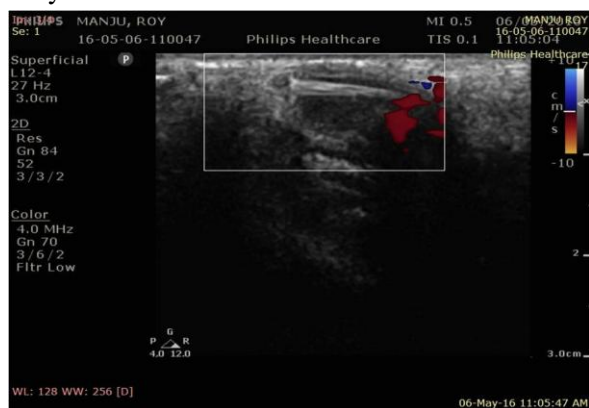

Figure - 4C: Case 4 - Color comet tail artifact based surface localization of the long axis of the foreign body in case 4 by placing the longer triangular segment of paper clip between skin and transducer, all along the same axis and keeping color mode on, thereafter marking as line C.

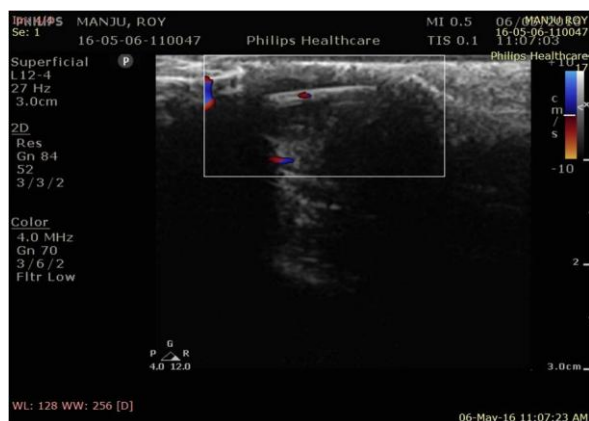


Figure - 5: “H” shaped surface marking in case 2 based on color comet tail artifact. The shape was formed by joining the two horizontal marking corresponding to proximal and distal end of foreign body with that of vertical line corresponding to its long axis.

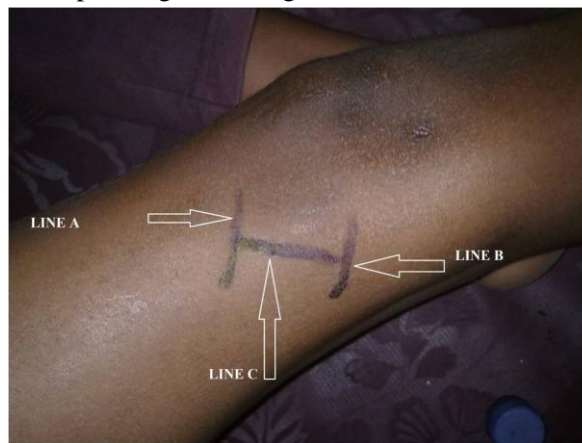


Figure - 6: Linear wooden thorn after minimal surgical exploration measuring 11 mm in case 2.



Figure - 7: Frequency- age (years) 3D bar, minimum age of presentation 4 years & maximum age of presentation 90 years. Mean age of presentation was 30.32 years.

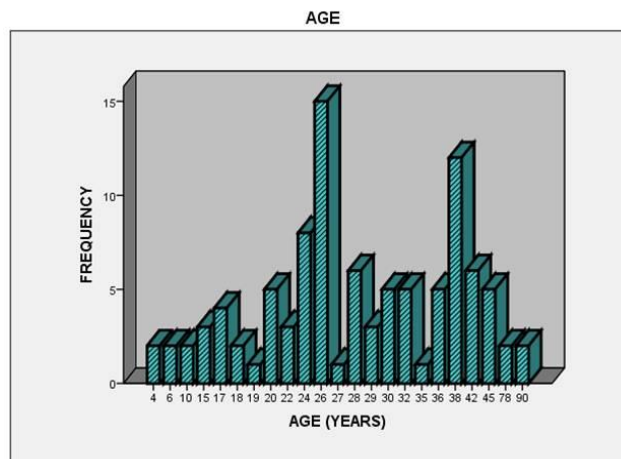


Figure - 8: Pie chart showing sex wise distribution of cases, 59% cases were reported in male and 41% cases were reported in female.

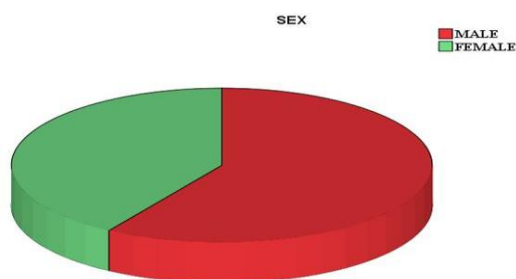


Figure - 9: Chief complaint - Frequency distribution 3D bar. 44% of cases had foreign body sensation, 27% came with discharging sinus, 24% of cases had unexplained pain and 5% had a history of trivial foreign body injury.

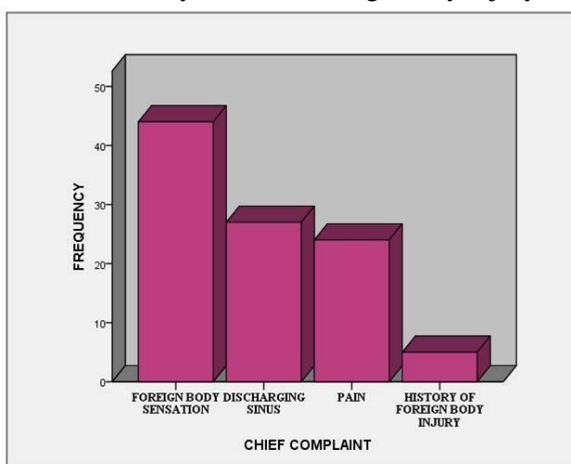


Figure - 10: Ultrasound appearance - Frequency distribution 3D bar. 39% of foreign bodies were highly echogenic with posterior acoustic. 32% of foreign bodies had perifocal hypo echoic halo sign. 29% had perifocal collection.

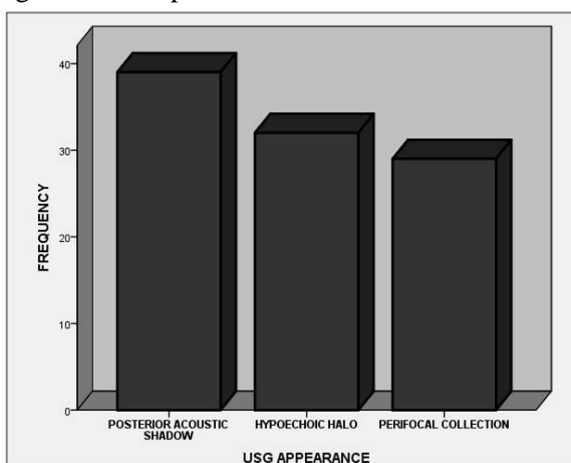


Figure - 11: Pie chart for distribution of nature of foreign bodies detected at surgery. 59% were thorn, 22% were woods, 8% were glass pieces and 4% were hard plastic materials that include poly vinyl chloride, HDPE high density polyethylene and polypropylene. Remaining 7% were post-operative scar tissue, air bubble and granuloma.

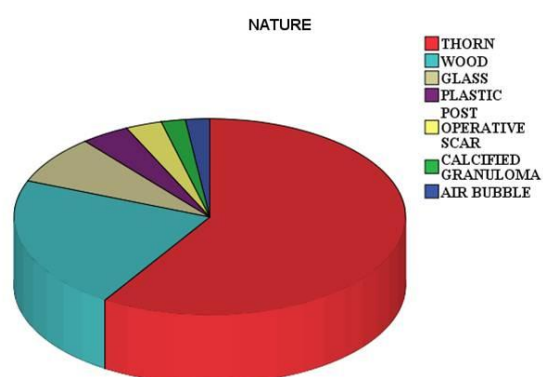
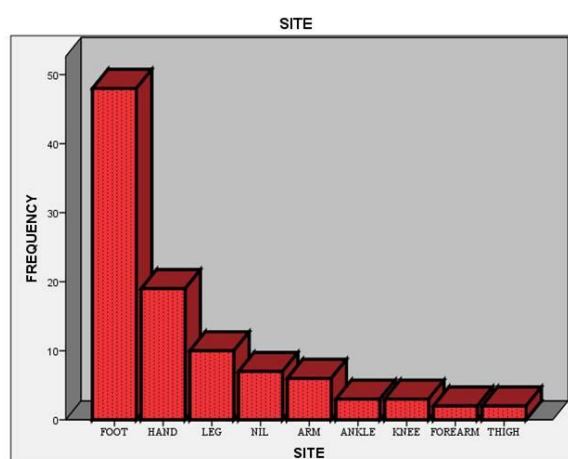


Figure - 12: Location wise- frequency distribution 3D bar. 48% of foreign bodies were located on foot, 19% on hand, 10% on leg, 6% on arm, 3% each on ankle and knee, and 2% each on forearm and thigh respectively.



Foreign bodies can be categorized as metallic, organic and inorganic, which may further range from radio-opaque to being radiolucent. Organic materials include thorns, woods. Inorganic materials include poly vinyl chloride, plastic and broken glass pieces. Ultrasound appearance of foreign bodies varies according to its age of presentation. In acute stages, with duration less than 3 days, they are echogenic with posterior

acoustic shadowing, which may further be attributed to air trapped within foreign body. In intermediate stages with duration ranging from 3 to 10 days, the foreign body becomes less echogenic; there is reduced triangle of posterior acoustic shadow and perifocal edema. 10 days onwards, that is during chronic stages, granulation tissues starts encapsulating the foreign body [1-9]. High resolution ultrasound shows a high sensitivity of 93 % approx. in detection of radiolucent foreign bodies such thorns, woods, plastics etc. in addition to being portable, relatively inexpensive with no radiation hazards. Depending upon the velocity of impact of foreign body injuries, it may be located within superficial soft tissues, muscle, tendons, joint spaces, cartilages, muscle bone interfaces and within bone itself [1-9]. Ultrasound is less

sensitive when it comes to detection of foreign bodies located at a depth of more than 3 cm, as is depicted in our study where we gave a false positive report in 7 out 10 cases where the foci of interest was located at a depth of more than 3 to 4 cm. It is also less sensitive in foreign bodies located within air filled cavities. Small echogenic foreign bodies' needs detailed evaluation and echogenic structures such as air bubble, scar tissue, ossified cartilage, intramuscular fascia and small hand bones are a close differential diagnosis. Posterior acoustic shadow whenever detected helps in differentiating the false positive ultrasound reports due to air bubble, intramuscular fascia and scar tissues, which do not depict posterior acoustic shadow [1-9]. The visibility of foreign body is maximum when it is aligned parallel to skin surface.

Table - 1: Simple form given to surgeons to be filled in the intra-operative and post-operative period.

Name	Nature of foreign body	Horizontal displacement from line A (≤ 5 mm OR > 5 mm)	Vertical displacement from line C (≤ 5 mm OR > 5 mm)
------	------------------------	--	--

Table - 2: Cross tabulation of ultrasound test and detection of foreign body on surgery.

			FB on surgery		Total
			Negative	Positive	
USG test	Positive	Count	7 _a	93 _a	100
		% within USG test	7.0%	93.0%	100.0%

Table - 3: Percentage agreement between preoperative H shaped surface marking and intra-operative positional findings (horizontal and vertical dimensions).

			Intra-operative Horizontal displacement at line A		Total
			> 5 mm	≤ 5 mm	
Intra-operative Vertical displacement	> 5 mm	Count	5	1	6
		% of Total	5.4%	1.1%	6.5%
	≤ 5 mm	Count	2	85	87
		% of Total	2.2%	91.4%	93.5%
Total		Count	7	86	93
		% of Total	7.5%	92.5%	100.0%

Conclusion

Blind surgical procedures of foreign body removal have been replaced by real time ultrasound guided removal under strict sterile conditions in most of the affluent nations. However in developing nations and semi urban places where there is limited and underrated sterilization and disinfection technique, real time ultrasound procedures for foreign body removal remains a challenging option. This study shall suffice to the needs of developing nations and semi urban places with precise preoperative surface localization, advantages of minimal surgical exploration, minimal local tissue injury, reduced patient's morbidity and no real time ultrasound associated nosocomial infection. The study shall also be helpful with special emphasis to those underserved villages where surgeons still rely on blind foreign body removal procedures, causing massive tissue exploration, increased hospital stay, increased cost of treatment, failure of removal and increased patients morbidity.

Acknowledgements

The authors hereby acknowledge Dr. Tapan Dhibar (Professor), Dr. Debasis Deoghuria, Dr. Jayati Bardhan and Dr. Sandip Kumar Ghosh (Associate Professors) for their extensive support, Dr. Runu Dhar, Dr. Bindu Bikash Srimani (Senior Residents), all of his colleagues Dr. Debashish Nandi, Dr. Somnath Paul, Dr. Saikat Roy, Dr. Koushik Sarkar, Dr. Samik Ghosh, and last but not the least the patient themselves who were all extremely pivotal and instrumental through the study period.

References

1. Stephanie A. Creel, Gandikota Girish, David A. Jamadar, et al. Sonographic Surface Localization of Subcutaneous Foreign Bodies and Masses. *J Clin Ultrasound*, 2009; 37: 158-160.
2. Ranajit Panigrahi, Sunil K Dash, Nishit Palo, et al. Foreign body detection in musculoskeletal Injuries: A in vitro blinded study comparing sensitivity among digital radiography, ultrasonography, CT and magnetic resonance imaging. *Musculoskeletal Regeneration*, 2015; 2: e649.
3. Gustavo Figueredo Casadei, Karina Romero, Victor Gomez. Soft-tissue foreign bodies: Diagnosis and removal under ultrasound guidance. *Colegio Interamericano de Radiología*, 2011; 1-11.
4. Leonardo Callegari, Anna Leonardi, Amedeo Bini, Chiara Sabato, Paolo Nicotera, Emanuela Spano, Davide Mariani, Eugenio A. Genovese, Carlo Fugazzola. Ultrasound-guided removal of foreign bodies: personal experience. *Eur Radiol.*, 2009; 19: 1273-1279.
5. Tahmasebi Morteza, Zareizadeh Hamdollah, Motamedfar Azim. Accuracy of ultrasonography in detecting radiolucent soft-tissue foreign bodies. *Indian Journal of Radiology and Imaging*, 2014; 24(2): 196-200.
6. Tedric D. Boyse, David P. Fessell, Jon A. Jacobson, John Lin, Marnix T. van Holsbeeck, Curtis W. Hayes. US of Soft-Tissue Foreign Bodies and Associated Complications with Surgical Correlation. *RadioGraphics*, 2001; 21: 1251-1256.
7. L. Kimberlee Horton, Jon A. Jacobson, Alex Powell, et al. Sonography and Radiography of Soft-Tissue Foreign Bodies. *AJR*, 2001; 176: 1155-1159.
8. Afshin Mohammadi, Mohammad Ghasemi-Rad, Maryam Khodabakhsh. Non-opaque soft tissue foreign body: sonographic findings. *BMC Medical Imaging*, 2011, 11: 9.
9. Andrew J. Rabe, William E. Shiels II. Ultrasound Guided Removal of an Intratendinous Foreign Body in an Adolescent. *J Am Osteopath Coll Radiol.*, 2012; 1(3).