

Original Research Article


# Two Port Needle Assisted Appendicectomy (TPNAA)

Manga Muralidhar<sup>1\*</sup>, P. V. Chalam<sup>2</sup>

<sup>1</sup>Associate Professor, <sup>2</sup>Professor

Department of Surgery, Gandhi Medical College, Hyderabad, India

\*Corresponding author email: [mmanga007@gmail.com](mailto:mmanga007@gmail.com)

	International Archives of Integrated Medicine, Vol. 3, Issue 7, July, 2016. Copy right © 2016, IAIM, All Rights Reserved. Available online at <a href="http://iaimjournal.com/">http://iaimjournal.com/</a> ISSN: 2394-0026 (P) ISSN: 2394-0034 (O)
	Received on: 27-06-2016 Accepted on: 05-07-2016 Source of support: Nil Conflict of interest: None declared.
<b>How to cite this article:</b> Manga Muralidhar, P. V. Chalam. Two Port Needle Assisted Appendicectomy (TPNAA). IAIM, 2016; 3(7): 211-215.	

## Abstract

**Background:** Laparoscopic appendicectomy has become the preferred procedure for treating appendicitis in last 10-15 years. The reasons are laparoscopy provides a better visualization of the operating field, pelvic organs like ovaries can be visualized in female patients, causes less postoperative pain, needs lesser hospital stay, gives faster recovery and most importantly a better cosmetic scar. The standard laparoscopic appendicectomy needs 3 ports to be introduced into the abdomen. Many modifications were introduced recently like SILS (Single port/Incision Laparoscopic Surgery), NOTES (Natural Orifice Transluminal Endoscopic Surgery), TUSPLA (Trans Umbilical Single Port Laparoscopic Appendicectomy), etc. with an intention to decrease the postoperative pain, decrease the hospital stay and give better cosmetic outcome. We present a series of twelve cases of laparoscopic appendicectomy performed using two ports and a needle instead of third port, which when performed successfully gives a better cosmetic outcome as the third port is avoided.

**Aims and objectives:** The aim of the study was to assess the feasibility of two ports needle assisted laparoscopic appendicectomy.

**Materials and methods:** This was an observational study done on a total number of 42 laparoscopic appendicectomies performed by a single operating team between June 2015 and May 2016. Two port appendicectomy were attempted. But, the procedure could be successfully performed in only 12 cases because of various reasons.

**Results:** Out of 42 cases TPNAA could be performed successfully in 12 procedures. 30 cases needed regular 3 port procedure because of various reasons.

**Conclusion:** TPNAA is a modification of regular three port appendicectomy and is a simple procedure and gives a better cosmetic outcome which can be performed in selected cases.

## Key words

---

Appendicitis, Appendicectomy, Laparoscopic Appendicectomy, Two Port Needle Assisted Appendicectomy.

## Introduction

---

Acute Appendicitis is one of the most common serious surgical emergencies encountered by the general surgeons throughout the world [1, 2, 3]. Acute appendicitis causes diffuse or periumbilical pain initially and pain shifting to the right iliac fossa afterwards. It is also associated with nausea or vomiting, loss of appetite, fever and leukocytosis and is diagnosed by using Alvarado (MANTRELS) score [1, 2, 3]. Recurrent appendicitis presents with lesser severity of symptoms but patients have localized tenderness at Mc Burney's point. Ultrasound plays significant role in diagnosis [1, 2, 3]. Although the classical appendicectomy by a Grid-iron incision or Lanz's incision is still being widely performed [1], laparoscopic appendicectomy has gained popularity in the past decade and had become the preferred option both by the surgeon and the patients because it provides the better visualization of the region concerned, specially the pelvic organs in female patients. Also it causes less postoperative pain, lesser duration of hospital stay and most importantly a good cosmetic outcome [1-9]. Regular laparoscopic appendicectomy requires three ports, a 10mm umbilical and two 5 mm ports in the lower abdomen on either side, the position of which can vary from case to case [2-6]. In recent times, many newer techniques were introduced like SILS (Single port/Incision Laparoscopic Surgery), NOTES (Natural orifice transluminal Endoscopic Surgery), TUSPLA (Trans Umbilical Single Port Laparoscopic Appendicectomy), etc. [10-18], all with the purpose of a better cosmetic outcome. Two port needle assisted appendicectomy (TPNAA) is a modification of regular laparoscopic procedure for appendicitis which significantly reduces the postoperative pain and has a good cosmetic outcome.

## Materials and methods

---

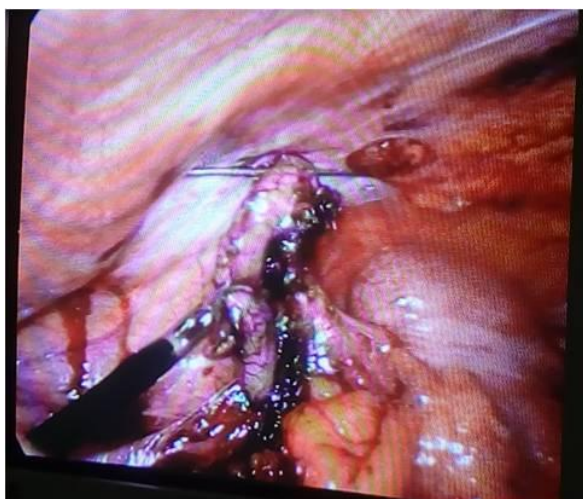
A total number of 42 cases of acute appendicitis were operated laparoscopically between June, 2015 and May, 2016. All patients with localized Mc Burney's' tenderness with symptoms less than 48 hours of duration were included. All patients with previous laparotomy scars, cases with signs of generalized peritonitis, cases unfit for general anesthesia. Age of the patients ranged between 14-50 yrs, with 32 females and 10 males. Alvarado (MANTRELS) score and ultrasound were used to evaluate all the patients.

## Procedure

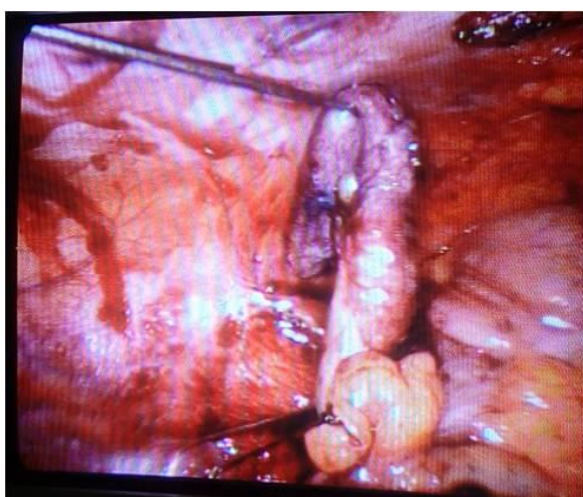
All cases were operated under general anesthesia after introducing a Foley's catheter. Pneumoperitoneum was created with a Veress needle and a 10 mm port introduced through a umbilical incision and abdomen visualized. A 5mm port was introduced through another incision lower abdomen on left side; appendix visualized and assessed for feasibility to perform TPNAA. The feasibility assessment depends on visualization, mobility, absence of complications like gangrene, perforation, dense adhesions etc. At this stage the decision to proceed with TPNAA was taken. Appendix was isolated and an 18G 20cm. long per cutaneous needle was introduced into the peritoneal cavity through the right iliac fossa close to the appendix and the tip of the needle passed through an avascular area in mesoappendix close to the appendix and then the tip was passed into the parietal wall thereby fixing the appendix. This is a very important step because once the appendix is anchored to the abdominal wall it cannot be maneuvered. Monopolar or bipolar diathermy was used to coagulate the mesoappendix and divide the mesoappendix upto the base without changing the position of appendix. After dealing with the mesoappendix, an endoloop was introduced and needle withdrawn from the appendix. The tip of the needle was passed through the endoloop and

again through the appendix, and base of the appendix was ligated and divided between the two ligatures. The appendix was then retrieved through the 10mm umbilical port and specimen sent for histopathological examination. The port sites were closed. The duration of surgery ranged from 45-60 minutes (**Figure – 1, 2**).

**Figure - 1:** Division of mesoappendix.



**Figure - 2:** Base of appendix ligated by endoloop.



## Results

Out of 42 cases, TPNAA could be performed successfully in 12 procedures (**Table – 1**). 30 cases needed regular 3 port procedure because of following reasons as per **Table – 2**.

**Table – 1:** Frequency of cases.

Case	No.
Total Appendicitis	42
Edematous appendices	12
Gangrenous appendices	5
Perforated appendices	5
Adhesions	8
TPNAA	12

**Table – 2:** Intra-operative findings.

Intra operative findings	Cases
Long Appendices more than 8 cm	4
Thick meso appendix	5
Friable appendices	6
Gangrenous appendices	5
Adhesions	5
Perforated appendices	5

## Discussion

Acute appendicitis is the most common surgical condition encountered by the general surgeons. Appendicectomy is also one of the most common surgical procedures performed. Although open appendicectomy by Grid-iron incision or Lanz's incision [1] is still widely being done , laparoscopic appendicectomy has gained popularity because of its advantages like better exposure, lesser postoperative pain, faster recovery, lesser hospital stay and a good cosmetic outcome [1-9]. Standard laparoscopic appendicectomy is performed through three ports. With technological development, newer and modified procedures were introduced. Two trocar appendicectomy was first performed by Schier [22] in 1998; many modified procedures were developed like laparoscopic appendicectomy through one incision at the umbilicus [14-18] or in right iliac fossa [19, 20]. In 2009 TUSPLA (Trans Umbilical Single Port Laparoscopic Appendicectomy) was introduced by Tae Ho Hong, et al. [10]. Other modifications like SILS (Single Incision Laparoscopic Surgery), NOTES (Natural Orifice Trans Endoscopic Surgeries– includes trans vaginal

and trans oral) were also introduced, each having its own disadvantages like NOTES -Transvaginal procedure can be performed only in females and many female patients do not accept this procedure [21-29]. Most of the Trans gastric procedures were on experimental animal models.

This modification described Two Port Needle Assisted Appendectomy can be performed with available regular and simple laparoscopic instruments and is safer to perform. The procedure is simple and does not require any special surgical expertise. The results do not vary much with other procedures, but has lesser postoperative pain, hospital stay and a good cosmetic outcome as the third port is avoided. The disadvantage of the procedure is that it cannot be performed in cases of thick edematous appendices, perforated appendices and gangrenous appendices and appendices with adhesions. The complications with Two Port Needle Assisted Appendectomy are quite similar with the standard three port procedure.

## Conclusion

Two Port Needle Assisted Appendectomy is a safe procedure that can be performed in significant number of cases. Although further randomized controlled trials are needed to assess the postoperative pain and hospital stay in comparison to other procedures, a significant reduction in postoperative scars can be achieved as a third port is avoided in this procedure.

## References

1. Bailey & Love's Short Practice of surgery. Chapter 71, edition 26, CRC press.
2. F. Graur, R. Eleisei, N. Al-Hajjar. E-NOTES Transumbilical Appendectomy. *Chirurgia*, 2013; 108: 571-575.
3. Momin Malik, Kirsty McCormack, et al. Single port/Incision laparoscopic surgery compared with standard three port laparoscopic surgery for appendectomy

- a randomized controlled trial. *Trials*, 2012; 13: 201.
4. Nguyen NT, Zainabadi K, Mavandadi S, Paya M, Stevens CM, Root J, et al. Trends in utilization and outcomes of laparoscopic versus open appendectomy. *Am J Surg.*, 2004; 188(6): 813-20.
5. Chung RS, Rowland DY, Li P, Diaz J. A meta-analysis of randomized controlled trials of laparoscopic versus conventional appendectomy. *Am J Surg.*, 1999; 177(3): 250-6.
6. Champault A, Polliand C, Mendes da Costa P, Champault G. Laparoscopic appendectomies: retrospective study of 2074 cases. *Surg Laparosc Endosc Percutan Tech.*, 2008; 18(2): 168-72.
7. Jitea N, Angelescu N, Burcoş T, Cristian D, Voiculescu S, Mircea N. Laparoscopic appendectomy in obese patients. A comparative study with open appendectomy. *Chirurgia (Bucur.)*, 1996; 45(4): 203-5.
8. Munteanu R, Copăescu C, Liăescu M, Turcu F, Iosifescu R, Timișescu L, et al. Laparoscopic appendectomy - considerations in about 1000 cases. *Chirurgia (Bucur.)*, 2005; 100(6): 541-9.
9. Nicolau AE. Laparoscopic appendectomy. *Chirurgia (Bucur.)*, 2011; 106(4): 495-503.
10. Hong TH, Kim HL, Lee YS, Kim JJ, Lee KH, You YK, et al. Transumbilical single-port laparoscopic appendectomy (TUSPLA): scarless intracorporeal appendectomy. *J Laparoendosc Adv Surg Tech A.*, 2009; 19(1): 75-8.
11. Oltmann SC, Garcia NM, Ventura B, Mitchell I, Fischer AC. Single-incision laparoscopic surgery: feasibility for pediatric appendectomies. *J Pediatr Surg.*, 2010; 45(6): 1208-12.
12. Ateş O, Hakgüder G, Olguner M, Akgür FM. Single-port laparoscopic appendectomy conducted intracorporeally with the aid of a transabdominal sling suture. *J Pediatr Surg.*, 2007; 42(6): 1071-4.

13. Nguyen NT, Reavis KM, Hinojosa MW, Smith BR, Stamos MJ. A single-port technique for laparoscopic extended stapled appendectomy. *Surg Innov.*, 2009; 16(1): 78-81.
14. Rispoli G, Armellino MF, Esposito C. One-trocar appendectomy. *Surg Endosc.*, 2002; 16(5): 833-5.
15. D'Alessio A, Piro E, Tadini B, Beretta F. One-trocar transumbilical laparoscopic-assisted appendectomy in children: our experience. *Eur J Pediatr Surg.*, 2002; 12(1): 24-7.
16. Valla J, Ordorica-Flores RM, Steyaert H, Merrot T, Bartels A, Breaud J, Ginier C, et al. Umbilical one-puncture laparoscopic-assisted appendectomy in children. *Surg Endosc.*, 1999; 13(1): 83-5.
17. Esposito C. One-trocar appendectomy in pediatric surgery. *Surg Endosc.*, 1998; 12(2): 177-8.
18. Pelosi MA, Pelosi MA 3rd. Laparoscopic appendectomy using a single umbilical puncture (minilaparoscopy). *J Reprod Med.*, 1992; 37(7): 588-94.
19. Inoue H, Takeshita K, Endo M. Single-port laparoscopy assisted appendectomy under local pneumoperitoneum condition. *Surg Endosc.*, 1994; 8(6): 714-6.
20. Ng PC. One-puncture laparoscopic appendectomy. *Surg Laparosc Endosc.*, 1997; 7(1): 22-4.
21. Tomulescu V, Popescu I. NOTES (Natural orifice transluminal endoscopic surgery) - present and perspectives. *Chirurgia (Bucur.)*, 2008; 103(2): 135-8.
22. Schier F. Laparoscopic appendectomy with 1.7-mm instruments. *Pediatr Surg Int.*, 1998; 14(1-2): 142-3.
23. Palanivelu C, Rajan PS, Rangarajan M, Parthasarathi R, Senthilnathan P, Prasad M. Transvaginal endoscopic appendectomy in humans: a unique approach to NOTES--world's first report. *Surg Endosc.*, 2008; 22(5): 1343-7.
24. Bucher P, Ostermann S, Pugin F, Morel P. E-NOTES appendectomy versus transvaginal appendectomy: similar cosmetic results but shorter complete recovery? *Surg Endosc.*, 2009; 23(4): 916-7.
25. Zorron R, Maggioni LC, Pombo L, Oliveira AL, Carvalho GL, Filgueiras M. NOTES transvaginal cholecystectomy: preliminary clinical application. *Surg Endosc.*, 2008; 22(2): 542-7.
26. Zornig C, Mofid H, Emmermann A, Alm M, von Waldenfels HA, Felixmüller C. Scarless cholecystectomy with combined transvaginal and transumbilical approach in a series of 20 patients. *Surg Endosc.*, 2008; 22(6): 1427-9.
27. Slim K, Launay-Savary MV. Launay-Savary, NOTES, the debate continues. *Surg Endosc.*, 2008; 22(10): 2326-2327.
28. ASGE; SAGES. ASGE/SAGES Working Group on Natural Orifice Transluminal Endoscopic Surgery White Paper October 2005. *Gastrointest Endosc.*, 2006; 63(2): 199-203.
29. Jayaraman S, Schlachta CM. Transgastric and transperineal natural orifice transluminal endoscopic surgery (NOTES) in an appendectomy test bed. *Surg Innov.*, 2009; 16(3): 223-7.