

Case Report


Primary splenic hydatid cyst – A case report

S. Thirumuruganand¹, S. Chelladurai^{2*}

¹Assistant Professor, ²PG Student

Department of General Surgery, Stanely Medical College, Tamil Nadu, India

*Corresponding author email: chelladuraimsgen@gmail.com

	International Archives of Integrated Medicine, Vol. 3, Issue 7, July, 2016.	
	Copy right © 2016, IAIM, All Rights Reserved.	
	Available online at http://iaimjournal.com/	
	ISSN: 2394-0026 (P)	ISSN: 2394-0034 (O)
	Received on: 13-06-2016	Accepted on: 20-06-2016
	Source of support: Nil	Conflict of interest: None declared.
How to cite this article: S. Thirumuruganand, S. Chelladurai. Primary splenic hydatid cyst – A case report. IAIM, 2016; 3(7): 358-361.		

Abstract

Hydatid cyst of spleen is a rare condition compared to hydatid cyst of other organs. It ranges from 0.5-4.0 % of abdominal hydatid cyst. The most common sites for hydatid cyst are the liver (60-70%) and lung (10-40%). The first filter of hydatid cyst is liver followed by lung which acts as a second filter. The other rare sites of hydatid cyst are spleen, thyroid, gall bladder, central nervous system, kidney, psoas muscle and retroperitoneum. Splenic hydatid cyst is uncommon, because cyst embryos are trapped by liver and lungs. In this case report, a 54 year old female admitted with complaint of left upper abdominal pain for 15 days duration with splenomegaly. With relevant investigations patient was diagnosed as isolated hydatid cyst of spleen and underwent open splenectomy. This case presented as a case for its rarity.

Key words

Hydatid cyst, Echinococcus, Splenectomy, Egg shell calcification.

Introduction

There are two types of Echinococcus infections, Echinococcus granulosus is the most common type, compared to Echinococcus multilocularis, which is less common, but more invasive. Hydatid disease is a parasitic disease caused by the larval form of Echinococcus granulosus. The disease is spread when food or water that contains the eggs of the parasite is eaten or by

close contact with an infected animal. The eggs are released in the stool of meat eating animal that are infected. The definitive host are dogs, whereas human was an intermediate host.

Splenic hydatid cyst is very rare with its occurrence less than 3% of total hydatid cyst. Splenic hydatid cyst is classified as primary or secondary based on isolated occurrence or associated with other organs. Isolated splenic

hydatid cyst occurs only when the parasite has passed two filters, namely hepatic and pulmonary system.

Case report

54 years old female patient admitted with complaint of upper abdominal pain for 15 days duration, gradual onset, progressive, dull aching and non radiating with no aggravating or relieving factors. No history of nausea, vomiting. No history of jaundice, cough or respiratory distress. She was known diabetic on oral drugs. On examination her general examination and vitals were normal. Abdominal examination revealed tenderness in left hypochondrium with splenomegaly. Respiratory, cardiovascular, central nervous system and musculoskeletal system were found to be normal.

Routine laboratory investigations like, complete hemogram, renal function test, liver function test and coagulation profile revealed no abnormalities. Plain radiograph of the abdomen showed soft tissue opacity with calcified margins is noted in left hypochondrium. Chest X-ray found to be normal. Ultrasound abdomen showed 6.3 X 5.9 cm round well defined peripherally calcified lesion noted in left hypochondrium. Contrast CT abdomen showed large 6.3 X 6.4 cm well defined lesion with peripheral rim of calcification is seen in upper pole of spleen (**Figure - 1**). Liver and lung showed no evidence of cyst. Patient was diagnosed as isolated hydatid cyst of spleen. Surgical exploration revealed a hydatid cyst occupying upper pole of spleen with rim of splenic tissue was noted in inferior surface (**Figure - 2**). The rest of abdominal organ found to be normal. Splenectomy was performed after adequate preparation and by applying clamp to the splenic pedicle. Histopathological examination showed 7.2 x 6.4 cm cavity lesion with thick calcified wall with many scolices with a double layer of hooklets confirmed the diagnosis of splenic hydatid cyst (**Figure - 3**). Post operative period was uneventful and patient was discharged with course of albendazole.

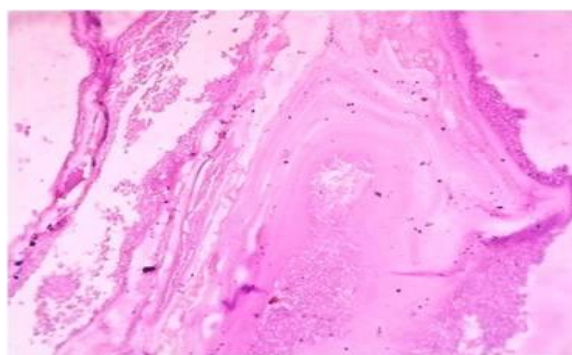
Figure - 1: 6.3 x 6.4 cm well defined lesion with peripheral rim of calcification.

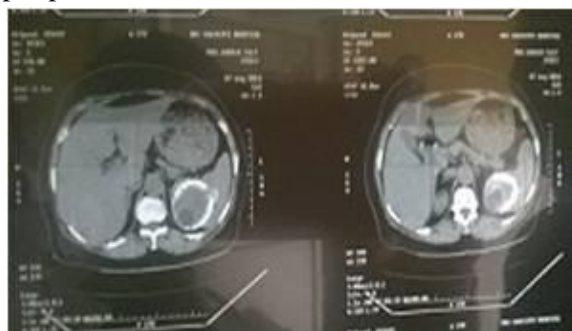

Figure - 2: Hydatid cyst occupying upper pole of spleen.

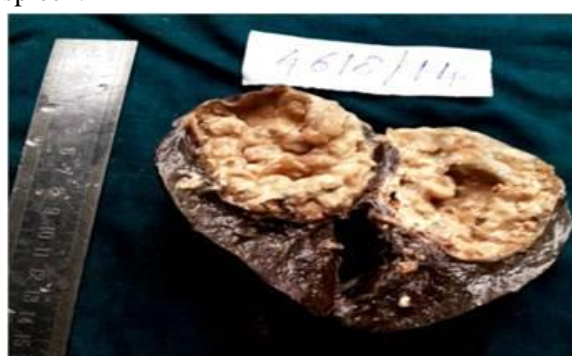

Figure - 3: Acellular lamellated eosinophilic membrane.



Discussion

Splenic hydatid cyst constitutes 0.5 to 4.0% of abdominal hydatid disease [1]. The most common affected organ of hydatid cyst was the liver and the lung, followed by other organs. Development of splenic hydatid cyst is uncommon due to life cycle of tapeworm, *Echinococcus granulosus* [2]. Primary infestation of the spleen usually takes place when parasite bypass hepatic and pulmonary filter. Retrograde spread of splenic Echinococcosis from the liver

to the spleen via the portal and splenic veins is also documented in cirrhosis with portal hypertension.

Primary infestation of spleen through the arterial route is possible. Secondary hydatid cyst of spleen usually follows systemic dissemination or intraperitoneal spread following ruptured hepatic hydatid cyst [3]. Most of the time splenic hydatid cyst is asymptomatic [4]. Splenic hydatid cysts associated with abdominal discomfort, abdominal pain and palpable mass in left hypochondrium [5]. It can present with multiple complications like infection, compression to adjacent organ, intra abdominal rupture, gastrointestinal bleeding and severe anaphylactic shock [6].

Mostly diagnosed based on imaging technique. Abdominal X-ray shows egg-shell calcifications in the splenic area, suggestive of hydatid cyst of the spleen. Ultrasound abdomen shows calcifications of the cyst wall, presence of daughter cyst, cyst membrane or septations. CT is the best modality to detect calcification and splenic hydatid cyst [7].

Surgery is the main modality of treatment [8]. Most of the time preferred line of management was total splenectomy, sometimes partial splenectomy, cyst enucleation and unrooting with omentoplasty also accepted management [9]. Splenectomy can be done either open or laparoscopic method, large spleen open method was preferred, whereas small spleen laparoscopy is the treatment of choice [10].

Conclusion

Isolated hydatid cyst of spleen is a rare entity. Most of the time non specific abdominal pain or mass abdomen will be the primary complaint. CT is the most sensitive investigations for confirmation of diagnosis. Surgical resection is the best curative procedure. Mode of surgical technique is either open or by laparoscopy. Large spleen open technique was preferred compared to laparoscopic technique. Post surgical

antihelminthic treatment necessary for complete remission.

References

1. Sharif MA, Mahmood A, Murtaza B, Malik IB, Khan A, Asghar Z, et al. Primary perisplenic hydatid cyst. *J Coll Physicians Surg--Pak JCPSP*, 2009; 19(6): 380–2.
2. Makkar M, Gupta C, Singh DP, Kaur S, Mahajan N. Giant isolated splenic hydatidosis. *Trop Parasitol.*, 2012; 2(1): 74–6.
3. Pukar MM, Pukar SM. Giant solitary hydatid cyst of spleen-A case report. *Int J Surg Case Rep.*, 2013; 4(4): 435–7.
4. Del Pino Porres FJ, Boils Arroyo PL, Pérez Folques JE, Baquero Valdelomar R, Pallas Regueira JA, Carbonell Tatay F, et al. Splenic hydatidosis: presentation of 8 cases and review of the literature. *Rev Clínica Esp.*, 1992; 190(2): 60–3.
5. Malik AA, ul Bari S, Younis M, Wani KA, Rather AA. Primary splenic hydatidosis. *Indian J Gastroenterol Off J Indian Soc Gastroenterol.*, 2011; 30(4): 175–7.
6. Uriarte C, Pomares N, Martin M, Conde A, Alonso N, Bueno MG. Splenic hydatidosis. *Am J Trop Med Hyg.*, 1991; 44(4): 420–3.
7. Sawarappa R, Kanoi A, Gupta M, Pai A, Khadri SIS. Isolated splenic hydatidosis. *J Clin Diagn Res JCDR*, 2014; 8(6): ND03–4.
8. Herrera Merino N, Abascal Morte J, Díaz del Río Botas M, Peñalver R, Colás Vicente A, Sánchez Movilla A, et al. Splenic hydatid cyst. A report of 16 cases. *Rev Esp Enfermedades Dig Organ Of Soc Esp Patol Dig.*, 1991; 79(4): 254–8.
9. Dar MA, Shah OJ, Wani NA, Khan FA, Shah P. Surgical management of splenic hydatidosis. *Surg Today*, 2002; 32(3): 224–9.

S. Thirumuruganand, S. Chelladurai. Primary splenic hydatid cyst – A case report. IAIM, 2016; 3(7): 358-361.

10. Rodríguez-Leal GA, Morán-Villota S, Milke-García M del P. Splenic hydatidosis: a rare differential diagnosis in a cystic lesion of the spleen. Rev Gastroenterol México., 2007; 72(2): 122–5.