

Original Research Article

# Assessment of clinic-pathologic discrepancy in diagnosis of Jaw lesions: A retrospective analysis

Siddharth Mosby<sup>1\*</sup>, Shaliputra Magar<sup>2</sup>, Shilpa Magar<sup>3</sup>,  
Sudarshan G Ranpise<sup>4</sup>, Pankaj Kumar Agarwal<sup>5</sup>, Sonam  
Agarwal<sup>6</sup>

<sup>1</sup>Principal and Head, Department of Oral Pathology and Microbiology, Vananchal Dental College and Hospital, Garhwa, Jharkhand, India

<sup>2</sup>Reader, Department of Oral Medicine and Radiology, Shri Aurobindo College of Dentistry and Research Centre, Indore, Madhya Pradesh, India


<sup>3</sup>Senior Lecturer, Department of Conservative and Endodontics, Shri Aurobindo College of Dentistry and Research Centre, Indore, Madhya Pradesh, India

<sup>4</sup>Ph.D Guide in Dentistry and Law, Zorosthian College and Open International University, Colombo, Srilanka

<sup>5</sup>Senior Lecturer, Maitri College of Dentistry and Research Centre, Anjora, Durg, Chattisgarh, India

<sup>6</sup>Senior Lecturer, Maitri College of Dentistry and Research Centre, Anjora, Durg, Chattisgarh, India

\*Corresponding author email: [siddhartha\\_mosby@ymail.com](mailto:siddhartha_mosby@ymail.com)

	International Archives of Integrated Medicine, Vol. 3, Issue 8, August, 2016. Copy right © 2016, IAIM, All Rights Reserved. Available online at <a href="http://iaimjournal.com/">http://iaimjournal.com/</a>	
	ISSN: 2394-0026 (P)	ISSN: 2394-0034 (O)
	Received on: 01-07-2016	Accepted on: 21-07-2016
	Source of support: Nil	Conflict of interest: None declared.
<b>How to cite this article:</b> Mosby S, Magar S, Magar S, Ranpise SG, Agarwal PK, Agarwal S. Assessment of clinic-pathologic discrepancy in diagnosis of Jaw lesions: A retrospective analysis . IAIM, 2016; 3(8): 140-145.		

## Abstract

**Background:** Numerous studies are quoted in literature which focuses mostly on evaluating the specific head and neck lesion such as tumours of odontogenic origin. Only limited studies are quoted in literature focusing on the prevalence the whole spectrum of biopsied oral and maxillofacial lesions in various countries. Hence; we planned this retrospectively analysis to evaluate the frequency of all biopsied jaw lesions in order to assess the discrepancy between clinical diagnoses and histopathologic diagnosis.

**Materials and methods:** The present study was planned in Vananchal Dental College, Jharkhand and involved analysis of records of all the patients whose biopsy specimen was submitted to the Department of Oral Pathology from June 2010 to July 2014. All the jaw lesions were divided

predominantly into three main groups depending on the type of lesions. Complete analysis of the record of the patients and their histopathologic reports was done and comparison was made between the clinical diagnosis and histopathologic diagnosis to assess the coordination between the two diagnoses of the jaw lesions.

**Results:** 1500 patient's records were evaluated in the present study. Group I, II and III had 400, 800 and 300 patients respectively. More male population was observed in the present study. Lesions diagnosed in the maxilla and in the mandible were approximately same in number. More than 75 percent of cases in this group were Periapical granulomas. The most prevalent lesion in Group II was radicular cyst followed by dentigerous and residual cyst.

**Conclusion:** Collaboration of histopathological details and radiographic findings should be done along with the clinical history to reach the final diagnosis.

## Key words

Biopsy, Diagnosis, Odonotogenic.

## Introduction

Literature from the past quotes studies which focus mostly on evaluating the specific head and neck lesion such as tumours of odontogenic origin [1, 2]. Many of these studies analyzed data in paediatric or geriatric population [3, 4]. Only limited studies are quoted in literature focusing on the prevalence the whole spectrum of biopsied oral and maxillofacial lesions in various countries [5-8]. A suitable semio-technique method to help determining the clinical and differential diagnosis between jaw cystic and tumoral lesions is aspiration puncture. The aspiration of a cystic lesion can provide additional information about its content (if liquid or serous, or if absent) and aid in the presumptive clinical diagnosis at the moment of its application [9]. Hence; we retrospectively analyzed the frequency of all biopsied jaw lesions and to compare the accuracy level of clinical diagnoses and histopathologic diagnosis.

## Materials and methods

We conducted this retrospective analysis dental college, Jharkhand. The institution was pre-informed about study protocol and written consent was obtained. Record of all the patients was collected whose biopsy specimen was submitted to the department of oral pathology from June 2010 to July 2014. Complete record of the patients were collected including their gender, age, location of lesion, provisional and

final histopathological diagnoses. Complete analysis of the record of the patients and their histopathologic reports was done and comparison was made between the clinical diagnosis and histopathologic diagnosis to assess the coordination between the two diagnoses of the jaw lesions. All the jaws lesions were divided into three predominant groups as shown in **Table - 1**.

**Table - 1:** Division of jaw lesions.

Groups	Parameter
I	Developmental/inflammatory/reactive lesions of the jaw
II	Cystic lesions
III	Tumors and tumor-like lesions

## Results

Records of 1500 patients were evaluated in the present study. **Graph - 1** shows the distributions of lesions between groups. Group I, II and III had 400, 800 and 300 patients respectively. More male population was observed in the present study. Lesions diagnosed in the maxilla and in the mandible were approximately same in number (**Table - 2**). The average age of the patients were  $42 \pm 1.7$  years and ranged from 6 to 80 years. **Table - 3** highlights the distribution of Group I lesions according to demographic details. More than 75 percent of cases in this group were Periapical granulomas. Hyperplastic dental follicle cases comprised of less than 10%.

The most prevalent lesion in Group II was radicular cyst followed by dentigerous and residual cyst as shown in **Table - 4**. **Table - 5** shows distribution of Group III lesions according to demographic details.

**Table - 2:** Distribution of jaw lesions according to demographic details.

Group	No. of patients	Site		Gender		Mean age $\pm$ SD (years)
		Maxilla	Mandible	Male	Female	
I	400	240	160	180	220	39 $\pm$ 5.8
II	800	410	390	500	300	41 $\pm$ 3.5
III	300	100	200	150	150	40 $\pm$ 2.6

**Table - 3:** Distribution of Group I lesions according to demographic details.

Group	No. of patients	Site		Gender		Mean age $\pm$ SD (years)
		Maxilla	Mandible	Male	Female	
Periapical granuloma	340	180	160	150	190	38 $\pm$ 4.2
Dental follicle (hyperplastic)	38	18	20	19	19	29 $\pm$ 3.1
Osteonecrosis	10	7	3	5	5	61 $\pm$ 4.1
Others	15	5	10	6	9	52.1 $\pm$ 4.7

**Table - 4:** Distribution of Group II lesions according to demographic details.

Group	No. of patients	Site		Gender		Mean age $\pm$ SD (years)
		Maxilla	Mandible	Male	Female	
Radicular cyst	440	230	210	240	200	41 $\pm$ 2.9
Dentigerous cyst	245	120	125	150	95	41 $\pm$ 2.4
Residual cyst	80	35	45	30	50	49 $\pm$ 3.7
Periodontal cyst	20	12	8	8	12	22 $\pm$ 2.1
Traumatic bone cyst	2	1	1	1	1	61 $\pm$ 7.1
Others	10	6	4	4	6	49 $\pm$ 6.4

**Table - 5:** Distribution of Group III lesions according to demographic details.

Group	No. of patients	Site		Gender		Mean age $\pm$ SD (years)
		Maxilla	Mandible	Male	Female	
Odontogenic benign tumours	200	102	98	111	89	39 $\pm$ 4.5
Non-odontogenic benign tumours	100	48	52	35	65	41 $\pm$ 4.5

## Discussion

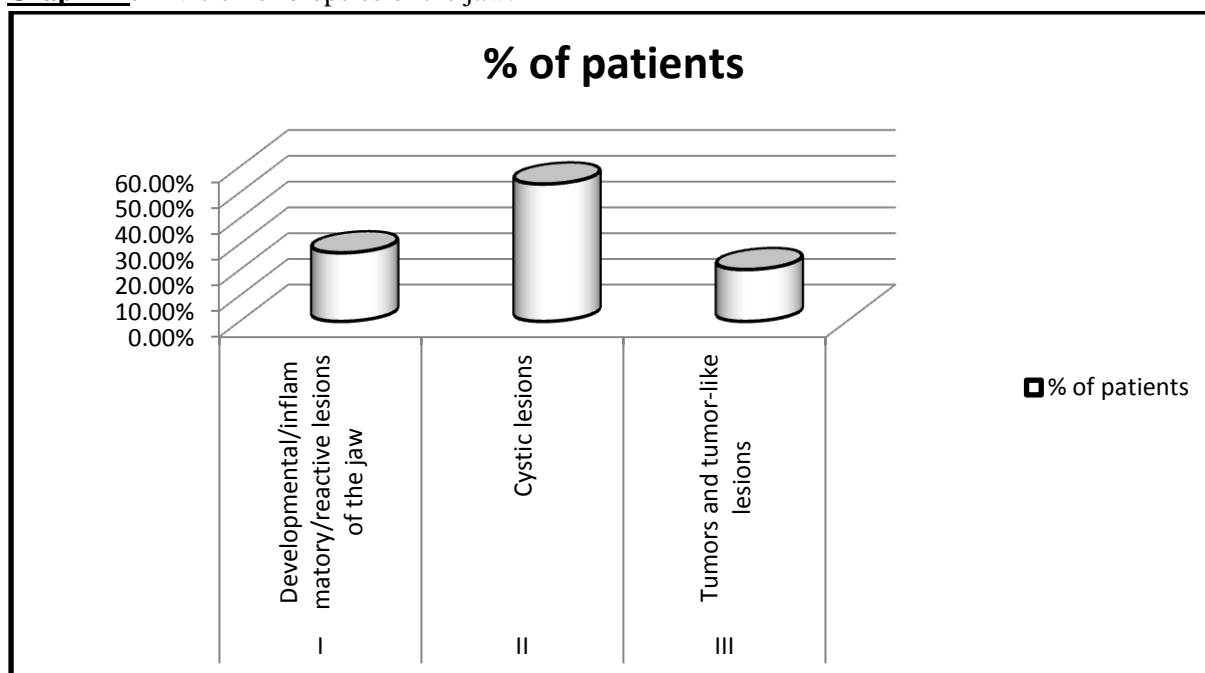
Only conventional radiographs were used in earlier times for the detection and diagnosis of

jaw lesion [10]. Because of the overlapping of bones structures, the study of jaw anatomy with conventional radiography is difficult. Spiral Computed Tomography with the dedicated

software “Dentascan” changed the diagnostic approach in this branch [10, 11]. The Dentascan is a dedicated reconstruction software for the dental diagnostic that allows a multiplanar vision of the jaws [12-14]. The software allows panoramic reconstruction from the CT axial view and vertical-seriate orthogonal or paraxial (tomograms), giving detailed images of the alveolar and dental bone and of the anatomy of the jaws. In the middle eighties, Dentascan was introduced basically for the field of dental implantology. With time, its use has become a routine procedure and has attained gold standards [13]. Used also in other fields, such as the evaluation of expansive lesions; Dentascan is currently under development in order to define a correct diagnostic [10, 14]. Different bones are involved by expansive lesions of maxillary bone. Division between benign and malignant pathologies forms the first important division while division between odontogenic tissue and periskeletal soft tissues forms the second division. Division between cystic or solid lesions forms another important class of divisions. We aimed to assess the frequency of all biopsied jaw lesions and compare the clinical diagnoses and final diagnoses to evaluate the importance of biopsy procedures. In our study, more than 50% of the cases were of odontogenic cysts. It's necessary as well to consider metastatic lesions that are not frequent but could involve the jaws. CT images often allow the differentiation of benign lesions and cysts from malignant lesions; otherwise biopsy is usually necessary to establish the final diagnosis [10, 14]. Although slightly higher in number, studies in the literature show that odontogenic cysts account for approximately 1% to 45% of all lesions [15]. This finding may be related to the profile of our sample, in which most patients were referred to our college from other clinics for surgical procedures that require expertise to do. In addition, it can be assessed as a result of differences in referral practice. 41 years was the mean age in our study, for odontogenic cysts which was in correlation to the result from Johnson, et al. [16] and Meningaud, et al. [17]. A predominance of female patients was seen in our study which was similar to the

results of Johnson, et al. [16], Meningaud, et al. [17], and Sharifian, et al. [18]. The overall maxilla: mandible ratio was approximately same which was consistent with Grossman, et al. [19] and Sharifian, et al. [18]. Radicular cysts were the most biopsied lesions followed by dentigerous cysts and residual cysts in cystic lesions and these data support the data presented by previous studies [20]. In Group 1 lesions, Periapical granuloma (more than 20% of all lesions) was the most common; which is marginally less than the results of Mendez, et al. [21]. This is probably due to conservative treatment protocol of the teeth with periapical lesions or lack of submission of excised specimens by our surgeons. In the present study, tumor or tumor like lesions of the jaws constituted more than 15% of all lesions. This rate is much more than what was reported in previous reports on reviewing, according to the 1992 WHO classification [22-24]. The study revealed that concordance between clinical and histopathological diagnoses of all lesions was approximately 80%. In this study, many of the diagnostic disagreements were in the developmental/ inflammatory/ reactive lesions group. Periapical granuloma, which was provisionally diagnosed as a radicular cyst, constitutes the overwhelming majority of the diagnostic disagreements. These data did not surprise us because of the same pathogenic process they have [25, 26]. In the present study, another tumor/tumor-like lesion that was diagnosed provisionally as cystic lesion was ameloblastoma. Urs et al analyzed the distribution of intra-osseous paediatric jaw lesions (0-16 years) and to correlate the same with the data which has been published in the literature. They showed a relatively higher incidence of odontogenic tumours (26.3%) as compared to those seen in other studies which have been published in literature. From the results, they observed a preponderance of odontogenic pathosis in the paediatric age group [27].

**Graph - 1:** Division of biopsies of the jaw.



## Conclusion

From the above results, it can be concluded that a collaboration of histopathological details and radiographic findings should be done along with the clinical history to reach the final diagnosis. Relying wholly on single parameter for attaining the diagnosis will increase the risk of false results.

## References

1. Avelar RL, Antunes AA, Carvalho RW, Bezerra PG, Oliveira Neto PJ, Andrade ES. Odontogenic cysts: a clinicopathological study of 507 cases. *J Oral Sci.*, 2009; 51: 581–586.
2. Servato JP, de Souza PE, Horta MC, Ribeiro DC, de Aguiar MC, de Faria PR, Cardoso SV, Loyola AM. Odontogenic tumours in children and adolescents: a collaborative study of 431 cases. *Int J Oral Maxillofac Surg.*, 2012; 41: 768–773.
3. Zuniga MD, Mendez CR, Kauterich RR, Paniagua DC. Paediatric oral pathology in a Chilean population: a 15-year review. *Int J Paediatr Dent.*, 2013; 23: 346–351.
4. Correa L, Frigerio ML, Sousa SC, Novelli MD. Oral lesions in elderly population: a biopsy survey using 2250 histopathological records. *Gerodontology*, 2006; 23: 48–54.
5. Akinmoladun VI, Akintububo OB, Adisa AO, Ojo EO, Ayuba D. Evaluation of the histopathology of orofacial lesions in a North-East Nigerian tertiary centre. *Ann Afr Med.*, 2013; 12: 105–109.
6. Jones AV, Franklin CD. An analysis of oral and maxillofacial pathology found in adults over a 30-year period. *J Oral Pathol Med.*, 2006; 35: 392–401.
7. Ali MA. Biopsied jaw lesions in Kuwait: a six-year retrospective analysis. *Med Princ Pract.*, 2011; 20: 550–555.
8. Franklin CD, Jones AV. A survey of oral and maxillofacial pathology specimens submitted by general dental practitioners over a 30-year period. *Br Dent J.*, 2006; 200: 447–450.
9. Coleman GC, Nelson JF. Principles of oral diagnosis. Saint Louis: Mosby-Year Book; 1993.
10. Abrahams JJ. Dental CT Imaging: a look at the jaw. *Radiology*, 2001; 219: 334–345.

11. Preda L, Rodriguez Y, Baena R, et al. La Tomografia Computerizzata nell'implantologia: aspetti tecnici e metodologici. *La Radiologia Medica*, 1999; 98: 447-453.
12. Abrahams JJ, Frisoli JK, Dembner J. Anatomy of the jaw, dentition, and related region. *Semin Ultrasound CT MR*, 1995; 16: 453-467.
13. Abrahams JJ. The role of diagnostic imaging in dental implantology. *Radiol Clin North Am.*, 1993; 31: 163-180.
14. Au-yeung K.M., Ahuja A.T., Ching A.S.C., Metreweli C. DentaScan in Oral Imaging. *Clinical Radiology*, 2001; 56: 700-713.
15. Jones AV, Craig GT, Franklin CD. Range and demographics of odontogenic cysts diagnosed in a UK population over a 30-year period. *J Oral Pathol Med.*, 2006; 35: 500-7.
16. Johnson NR, Savage NW, Kazoullis S, Batstone MD. A prospective epidemiological study for odontogenic and non-odontogenic lesions of the maxilla and mandible in Queensland. *Oral Surg Oral Med Oral Pathol Oral Radiol.*, 2013; 115: 515-22.
17. Meningaud JP, Oprean N, Pitak-Arnop P, Bertrand JC. Odontogenic cysts: A clinical study of 695 cases. *J Oral Sci.*, 2006; 48: 59-62.
18. Sharifian MJ, Khalili M. Odontogenic cysts: A retrospective study of 1227 cases in an Iranian population from 1987 to 2007. *J Oral Sci.*, 2011; 53: 361-7.
19. Grossmann SM, Machado VC, Xavier GM, Moura MD, Gomez RS, Aguiar MC, et al. Demographic profile of odontogenic and selected nonodontogenic cysts in a Brazilian population. *Oral Surg Oral Med Oral Pathol Oral Radiol Endod.*, 2007; 104: e35-41.
20. Nuñez-Urrutia S, Figueiredo R, Gay-Escoda C. Retrospective clinicopathological study of 418 odontogenic cysts. *Med Oral Patol Oral Cir Bucal.*, 2010; 15: e767-73.
21. Mendez M, Carrard VC, Haas AN, Lauxen Ida S, Barbachan JJ, Rados PV, et al. A 10-year study of specimens submitted to oral pathology laboratory analysis: Lesion occurrence and demographic features. *Braz Oral Res.*, 2012; 26: 235-41.
22. Luo HY, Li TJ. Odontogenic tumors: A study of 1309 cases in a Chinese population. *Oral Oncol.*, 2009; 45: 706-11.
23. Ladeinde AL, Ajayi OF, Ogunlewe MO, Adeyemo WL, Arotiba GT, Bamgbose BO, et al. Odontogenic tumors: A review of 319 cases in a Nigerian teaching hospital. *Oral Surg Oral Med Oral Pathol Oral Radiol Endod.*, 2005; 99: 191-5.
24. Buchner A, Merrell PW, Carpenter WM. Relative frequency of central odontogenic tumors: A study of 1,088 cases from Northern California and comparison to studies from other parts of the world. *J Oral Maxillofac Surg.*, 2006; 64: 1343-52.
25. Lia RC, Garcia JM, Sousa-Neto MD, Saquy PC, Marins RH, Zucolotto WG. Clinical, radiographic and histological evaluation of chronic periapical inflammatory lesions. *J Appl Oral Sci.*, 2004; 12: 117-20.
26. Ikeshima A, Ozawa M, Yamamoto H, Araki M, Sairenji E. Differential diagnosis between cyst and tumor. Dentigerous cyst and ameloblastoma containing teeth. *J Nihon Univ Sch Dent.*, 1990; 32: 19-26.
27. Urs AB, Arora S, Singh H. Intra-Osseous Jaw Lesions in Paediatric Patients: A Retrospective Study. *Journal of Clinical and Diagnostic Research*, 2014; 8(3): 216-220.