


Case Report

Rare occurrence of fungal thyroiditis - A case report

Pavani B^{1*}, Indrasen Reddy K², Ranga Reddy S³, Sridhar Reddy D⁴

¹Consultant Pathologist, ²Consultant General Physician, ^{3,4}Consultant ENT Surgeons
Ozone Hospitals, Kothapet, Hyderabad, Telangana, India

*Corresponding author email: pavanikiran71@yahoo.com

	International Archives of Integrated Medicine, Vol. 3, Issue 12, December, 2016. Copy right © 2016, IAIM, All Rights Reserved. Available online at http://iaimjournal.com/	
	ISSN: 2394-0026 (P)	ISSN: 2394-0034 (O)
	Received on: 01-12-2016	Accepted on: 07-12-2016
	Source of support: Nil	Conflict of interest: None declared.
How to cite this article: Pavani B, Indrasen Reddy K, Ranga Reddy S, Sridhar Reddy D. Rare occurrence of fungal thyroiditis - A case report. IAIM, 2016; 3(12): 156-158.		

Abstract

Fungal thyroiditis is extremely rare and its true incidence still happens to be the tip of an iceberg. We present here the case of an immunocompetent 35-year-old woman who presented with a left thyroid nodular goiter, and an incidental detection of *Aspergillus* infection. The accurate diagnosis of thyroid *Aspergillosis* is important, since there is every need to prevent further complications due to the occurrence of a disseminated disease. We report a case of 35-year-old woman presenting with a solitary left thyroid nodule.

Key words

Aspergillosis, Nodular goitre, Fungal thyroiditis.

Introduction

Fungal thyroiditis is extremely rare. We present the case of an immunocompetent 35-year-old woman who presented with a left thyroid nodular goiter, and a concomitant *Aspergillus* infection.

Case report

We have reported here a case of 35-year-old woman presenting with a solitary left thyroid nodule. There was no relevant family history.

During her initial visit to our institution, the patient was in good condition, her blood pressure was 120/80 mm Hg, and her pulse was 80/min and regular. The patient was clinically euthyroid, and the rest of the examination was unremarkable, with the exception of 6 cm firm smooth mass on the left side of the thyroid that moved with swallowing. Thyroid function tests gave normal results. Fine-needle aspiration biopsy (FNA) of the nodule was consistent with nodular goiter. The patient is a village resident,

maintains a general grocery store. Thyroid ultrasound revealed nodular goitre features with no evidence of malignancy. She underwent thyroid nodulectomy in our hospital with a working diagnosis of benign nodular goiter. Macroscopic examination of the surgical specimen revealed a dark brown partly lobulated thyroid mass with a total weight of 25 g, measuring 6 × 5 cm. The capsular surface was soft and dark brown. Cut surface was tan to grayish brown with colloid filled microcystic areas and an occasional grayish white 1x1 cm solid nodule. No necrosis, papillary masses or a gross cystic change was discernible.

Histopathologic findings showed predominant features of a benign adenomatous goiter. Some of the sections on H and E (**Figure - 1**), periodic acid Schiff and silver methenamine were positive for fungal hyphae that divided at 45° into branches, and conidia were detected next to the thyroid capsule, finding their way into the thyroid parenchyma. In addition, remarkable ischemic changes were observed along with few Psammoma bodies' and focal presence of optically clear nuclei (**Figure - 2**). The latter features prompted us to search for an occult papillary carcinoma, which were later attributed due to degenerative associated changes. No papillae or the intranuclear inclusions were identified. There were no multinuclear giant cells, eosinophils, micro abscesses or granulomatous reaction. The patient remained asymptomatic and euthyroid till the last follow-up visit, i.e. 3months after completion of surgical&medical therapy.

Discussion

Mycoses /fungal infections are considered as a recognized consequence of an immunocompromised state, including neutropenia, exposure to high-dose corticosteroids, the presence of intravascular catheters and prolonged exposure to broad-spectrum antibiotics. The spectrum of fungal infections can range from an asymptomatic infection to disseminated diseases. Fungal

thyroiditis per se is quite a rare entity, more so in an immunocompetent host. Most reported fungal infections of the thyroid have occurred concurrently with systemic infections in immunocompromised hosts, some of which had a pre-existing thyroid disease as reported by Berger, et al. [3]. Preexisting thyroid diseases such as simple goiter, nodular goiter, adenoma, autoimmune thyroiditis, and carcinoma etc, appear to be the most common predisposing condition for thyroid infections [1]. To the best of our knowledge this is the first case report of *Aspergillus* thyroiditis arising in an immunocompetent patient. Women appear to be more predisposed to infections of the thyroid gland [2]. *Aspergillus fumigatus* is the most pathogenic of the molds, to cause an invasive disease. Other species of *aspergillus* include *A. flavus*, *A. terreus*, and *A. Niger*. These pathogens grow as molds in the environment and as hyphal forms within tissues. Inhalation of fungal spores or localized colonization of the skin may usually perpetuate infections, nonetheless there were no respiratory or skin manifestations in our patient. Most patients with *Aspergillus* thyroiditis have disseminated infection, primarily with lung compromise. Late diagnosis and treatment, severity of immunosuppressive state and thyroid hormone overload contribute to extremely high mortality rates [4]. Isolated reports of thyroid involvement have been described in the setting of disseminated candidiasis, coccidioidomycosis, and pseudallescheriasis and *H. capsulatum*. Ante-mortem diagnosis of fungal thyroiditis is made by direct microscopy and culture of a fine-needle aspirate, or/and biopsy in most cases [5]. In our case the diagnosis of fungal thyroiditis was made postoperatively after histopathological examination. Tissue culture technique takes weeks for definitive results and most fungi require special fungal media for growth. Histopathologic diagnosis with its distinctive characteristics could yield faster presumptive diagnosis [6], as well as to help distinguish between truly invasive tissue disease versus contamination or colonization.

Figure – 1: Histopathological analysis showing diffuse fungal spores and non-pigmented hyphae displaying acute-angle morphology of *Aspergillus* species among the thyroid acini (H and E stain, 40X).

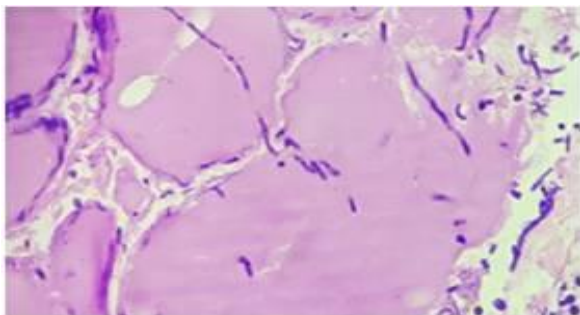
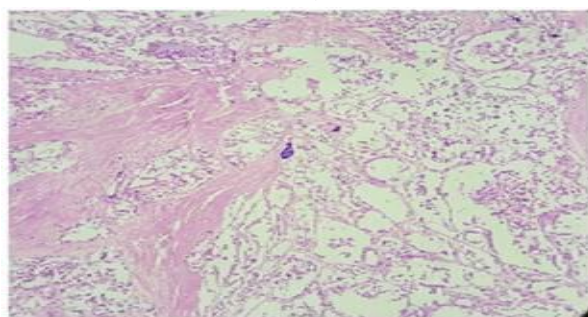


Figure – 2: Coagulative necrosis and psammoma bodies (H and E stain, 40X).



Conclusion

This case serves to alert clinicians to the possibility of infectious thyroiditis and reinforces the high risk of aspergillosis in an immunocompetent patient, with thyroid disease. Though a rare entity, all patients with thyroid lesions should be carefully scanned to exclude a hidden infectious thyroiditis entity to prevent life threatening complications. Early diagnosis of invasive aspergillosis is a challenge and careful analysis of sufficient number of tissue sections forms a prerequisite. This case also emphasizes the need for thorough investigation of all thyroid lesions, to establish a precise statistical data over incidental fungal thyroiditis cases.

References

1. Xiao-Ji Lin, Rong-Xin Yao, Mu-Qing He, Bao-Ling Zhu and Wen-Jian Guo. Treatment of fungal myositis with intra-lesional and intravenous itraconazole: a case report. *Journal of Medical Case Reports*, 2013; 7: 132. DOI: 10.1186/1752-1947-7-132.
2. Luciano Z. Goldani, Clóvis Klock, Ada Diehl, Ane C. Monteiro, Ana Luiza Maia. Histoplasmosis of thyroid. *J Clin Microbiol.*, 2000; 38(10): 3890–3891.
3. Herbrecht R, Denning DW, Patterson TF, et al. Invasive Fungal Infections Group of the European Organization for Research and Treatment of Cancer and the Global Aspergillus Study Group: Voriconazole versus amphotericin B for primary therapy of invasive aspergillosis. *N Engl J Med.*, 2002; 347: 408-415.
4. M. L. Sion, M. C. Armenaka, I. Georgiadis, G. Paraskevopoulos, I. Nikolaidis. *Aspergillus fumigatus* abscesses of the thyroid with obstruction of the esophagus. *Thyroid*, 2004; 14(9): 786–788.
5. I Torres AM, Agrawal S, Peters S, Khurana K, Feiglin D, Schroeder E, Izquierdo R. Invasive aspergillosis diagnosed by fine-needle aspiration of the thyroid gland. *J Clin Microbiol.*, 2000; 38(10): 3890–3891.
6. L. Z. Goldani, A. P. Zavascki, A. L. Maia. Fungal thyroiditis: an overview. *Mycopathologia*, 2006; 161(3): 129–139.