


Original Research Article

# Clinical study of pedicled sternocleidomastoid muscle flap interposition for cervical tracheo oesophageal fistula repair at a tertiary care hospital

P.S. Ganesh Babu<sup>1\*</sup>, T.M Balakirshnan<sup>2</sup>, Ramadevi<sup>3</sup>

<sup>1</sup>Assistant Professor, <sup>2</sup>Assistant Professor, <sup>3</sup>Professor and Head IRRH and Department of Plastic Surgery, Govt Stanley, Medical College, Chennai, Tamil Nadu, India

\*Corresponding author email: [Psganeshbabu1970@Gmail.Com](mailto:Psganeshbabu1970@Gmail.Com)

	International Archives of Integrated Medicine, Vol. 4, Issue 9, September, 2017. Copy right © 2017, IAIM, All Rights Reserved. Available online at <a href="http://iaimjournal.com/">http://iaimjournal.com/</a>	
	ISSN: 2394-0026 (P)	ISSN: 2394-0034 (O)
	Received on: 30-07-2017	Accepted on: 12-08-2017
	Source of support: Nil	Conflict of interest: None declared.
<b>How to cite this article:</b> P.S. Ganesh Babu, T.M Balakirshnan, Ramadevi. Clinical study of pedicled sternocleidomastoid muscle flap interposition for cervical tracheo oesophageal fistula repair at a tertiary care hospital. IAIM, 2017; 4(9): 105-109.		

## Abstract

**Introduction:** Tracheo Oesophageal Fistula (TEF) is a major cause of morbidity and mortality necessitating complex clinical evaluation and decision making for optimal management. It is best treated in a specialty tertiary care setting by a multidisciplinary team approach. In acquired non-malignant causes of airway-oesophageal fistulas, the patients suffer from significant morbidity due to recurrent pulmonary sepsis. These diseases are complex and mandate critical preoperative evaluation for optimal management. Prolonged endotracheal intubation combined with a nasogastric tube may lead to a TEF. This results from pressure necrosis generated by a ventilating cuff in the trachea and a prolonged feeding tube in the esophagus.

**Aim of the study:** To study the results of function preserving pedicled perforator based sternocleidomastoid muscle as an inter position flap after primary repair of cervical trachea-oesophageal fistula.

**Materials and methods:** The study was conducted from the period of one year from 2015-2016 at IRRH and Plastic Surgery Department of Government Stanley Medical College, Chennai. Totally 15 patients were included in the study. Patients with clinical presentation were evaluated, a pre operative

investigation like Bronchoscopy, OGD MRI, CECT of the neck was taken. All patients with tracheal oesophageal fistula in the cervical region following corrosive poisoning (organophosphates) on prolonged intubation who under went closure with the pedicled sternocleidomastoid muscle as an interposition flap.

**Results:** All patients diagnosed with Tracheo oesophageal fistula following corrosive poisoning on prolonged intubation were included. (N = 15). The study period was from 2015 to 2016. Patient's demographic data and clinical course were closely monitored and recorded. All Patients recovered well. Oral feeding started (liquids) on 4<sup>th</sup> post-operative day after doing gastro Graffin study, and solids on the 10th day. No recurrence in 1 year follows up.

**Conclusion:** In our technique, we maintained the intramuscular cock screw perforators from the transverse cervical artery. This constant anatomy favored us to use sternal head component separate from the clavicular head and interposed them between the repaired trachea and esophagus. Preserving the clavicular head of SCM maintains the form and function of the muscle. The vascularized muscle flap prevents both tracheal and oesophageal strictures and stenosis.

## Key words

Pedicled Sternocleidomastoid Muscle Flap, Cervical Tracheo Oesophageal Fistula, Gastrograffin.

## Introduction

First reported the use of the sternocleidomastoid (SCM) muscle in head and neck reconstruction was by Jiano in 1908 in which it was transposed to a paralyzed face to restore dynamic reanimation. Owens in 1955 is credited with being the first to report the musculocutaneous flap based on the SCM. Bakamjian modified Owens flap by extending the skin territory below the level of the clavicle. Ariyan identified the inferior vascular supply from the thyrocervical trunk and successfully transferred an inferiorly based flap [1]. The problem of donor site contour deformity was addressed by Alvarez et al who reported the use of split SCM musculocutaneous flap in 1983. Alvarez, et al. described a series of cases in which either the sternal head of the clavicular head of the muscle was transferred to the recipient site. They cautioned that this longitudinal split could only be carried out through approximately two-thirds of the muscle's belly in its longitudinal direction [2]. The SCM is a round muscle that originates from the manubrium and the medial aspect of the clavicle. It runs an oblique course in the neck to insert on the mastoid process and the superior nuchal line. Contraction of the SCM leads to tilting of the head, bringing the ipsilateral ear closer to the shoulder [3]. The superficial layer of the deep

cervical fascia splits to provide coverage of the SCM on both its deep and superficial surfaces. Instrumentation of the inflamed phlegmonous upper air way is the single most factor in the development of a tracheoesophageal fistula. Repair should be carried out as soon as possible to protect the airway from inadvertent oesophageal overflow and aspiration. Interposition of the highly vascular sternal head of SCM without compromising the clavicular head acts as a water proof barrier with the promotion of wound healing at repaired tracheal and oesophageal stoma [4]. Sternal head of SCM was interposed between the trachea and esophagus, A well-vascularized tissue interposed between two suture lines, which are relatively ischemic zone's (which lie one over the other) to prevent the occurrence or recurrence fistula is the established principle in plastic surgery [5]. In 15 cases of the variously sized tracheal – oesophageal fistula's repaired in the neck. We used superiorly based pedicled perforator based sternocleidomastoid muscle flap [6].

## Materials and methods

The study was conducted for a period of one year from 2015-2016 at IRRH and Plastic surgery department of the government Stanley medical college, Chennai. Totally 15 patients were

included in the study. Patients with clinical presentation were evaluated, a pre-operative investigation like Bronchoscopy, OGD, MRI, CECT of the neck was taken. All patients with tracheal oesophageal fistula in the cervical region following corrosive poisoning (organophosphates) on prolonged intubation who under went closure of the pedicled sternocleidomastoid muscle as an interposition flap.

#### **Inclusion criteria**

TEF at the Level of Cervical Region, Patients Who had Ingested Corrosive Poisoning (OPC) On Intubation For Prolonged Period.

#### **Exclusion criteria**

Patients who have other causes of tef like congenital, malignancy, trauma. Patients with TEF at the thoracic region.

#### **Operative procedure**

Neck exploration is done through a left longitudinal incision made in the neck parallel anterior border of the sternocleidomastoid muscle, Strap muscle was isolated and divided. Left lobe of thyroid moved to the right side after preserving recurrent laryngeal nerve.

#### **Outline of the operative procedure**

**Step 1:** An Exploratory incision made on the left side of the neck. A longitudinal incision along the anterior border of the sternocleidomastoid muscle.

**Step 2:** Primary closure of the fistulous opening in the oesophageus done using vinyl with intermittent suturing

**Step 3:** Closure is checked for any air leak by pooling water over the closure site

**Step 4:** Trachea closed.

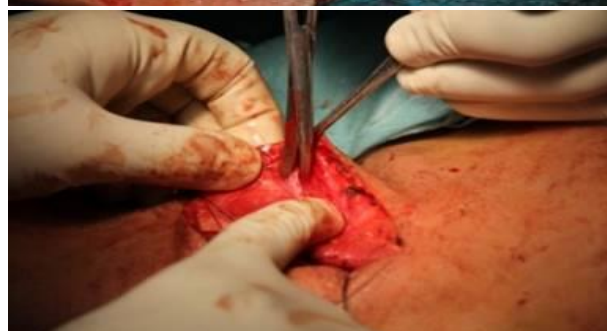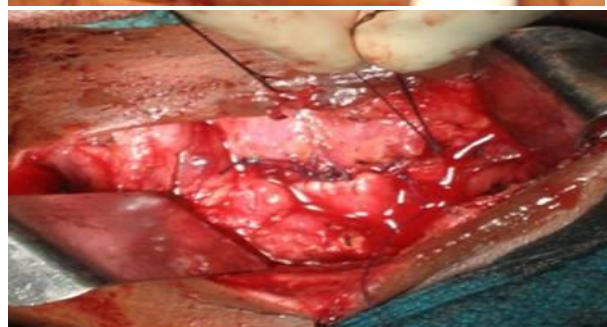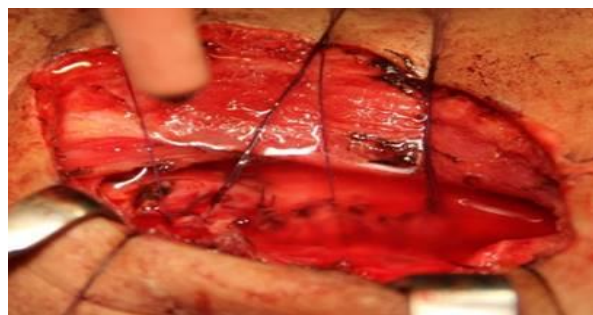
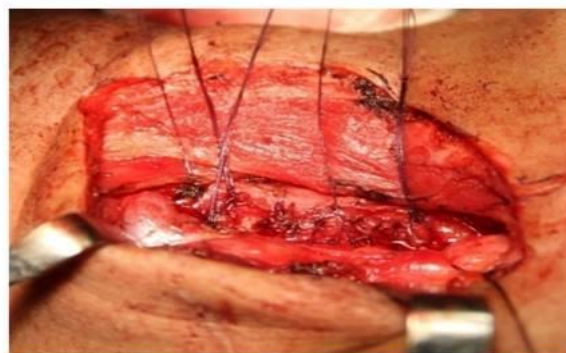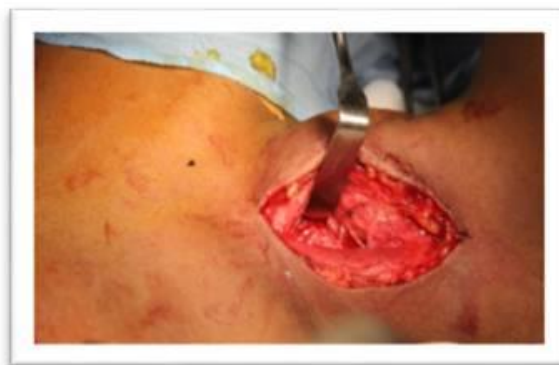**Step 5:** sternocleidomastoid muscle is been elevated

**Step 6:** The clavicular head of the SCM muscle is separated

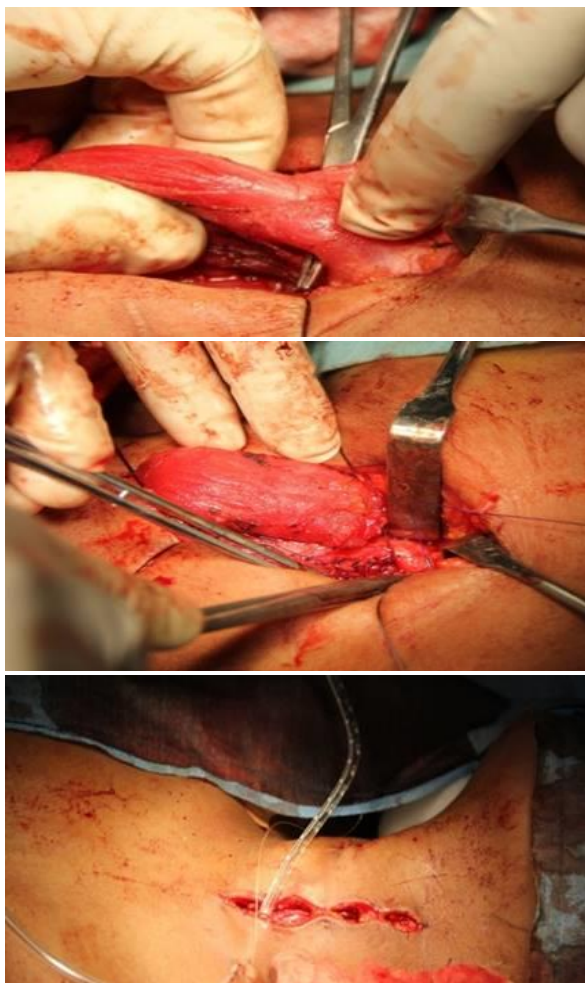
**Step 7:** Muscle is been interposed between the repaired esophagus & trachea

**Step 8:** Wound closed with a suction drain

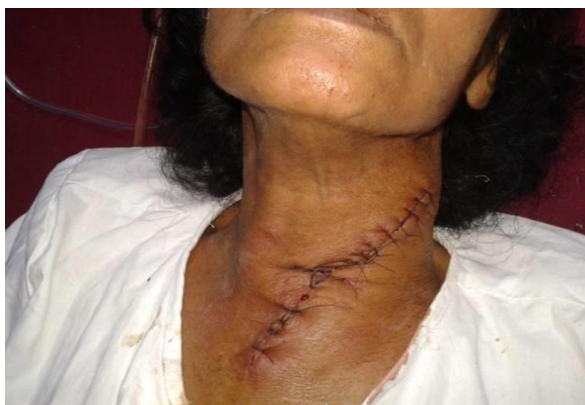**Photo – 1 to 8:** Overview of operative procedure.







**Photo – 9:** First post operative day showing the suture line.



To confirm there is no recurrence of fistula or functional deformity in the neck following function preserving pedicled sternocleidomastoid muscle interposition flap, patient on RT feeding showed no leak. On 4<sup>th</sup> postoperative day, oral feeding started. Barium swallow on 13 postoperative day showed no leak (**Photo – 1 to 9**).

## Results

All cases with TEF due to opo poisoning followed by prolonged intubation. Most of the patients were females between age group 25 to 35 years. Most of the cases were suicidal. The maximum size of the fistula was 3.5x2.5 cm. Most of them presented with respiratory problems like pneumonia, consolidation. All had peri operative nutritional support like peg or Ryle tube feeding, Oral feeding started (liquids) on 4<sup>th</sup> POD after doing gastro Graffin study, and solids on the 10<sup>th</sup> day. No recurrence in 1 year follows up post intubation. TAFs seen in 2<sup>nd</sup> or 3<sup>rd</sup> decades of life following prolonged mechanical ventilation following poisoning by suicidal intention. Single-stage primary repair of both airway and esophageal defects with muscle flap interposition can safely be performed successfully in majority of cases.

## Discussion

Abnormal communication between the trachea and the esophagus due to a benign pathology as in our case, which is presented with a swallow cough sequence, should arouse suspicion, as early diagnosis and repair are essential for a successful treatment [7]. Unlike malignant TEF patients who were ill-nourished and had poor performance status, the patients with benign fistulas were moderately nourished, but had good performance status among the benign TEFs, ischemia and posterior necrosis of the tracheal and esophageal membrane, due to the tracheal and gastric tube cuffs seen in individuals on prolonged mechanical ventilation, are the most common etiologies [8]. Interposition of the highly vascular sternal head of SCM without compromising the clavicular head acts as a water proof barrier with the promotion of wound healing at the tracheal and oesophageal stoma [9]. Due to the etiological diversity and the low frequency of TEFs, there is no consensus in the literature regarding the ideal treatment of this clinical condition and the proposed treatments are various. Majority of cases with benign TEFs were due to the complication of prolonged endotracheal intubation [10]. In all the patients

tracheal and esophageal defects were closed primarily with interposition of the sternocleidomastoid muscle flap between the two organs. The results were positive. The median length of stay in hospital in the postoperative period was found to 16 days [11]. For all cases, we have used only the sternal head of sternocleidomastoid muscle by which we achieved less donor site morbidity by preserving the function of the muscle. In one year follow up there was nil recurrence of the fistula [12].

### **Conclusion**

In our technique, we maintained the intramuscular cock screw perforators from the transverse cervical artery. This constant anatomy favored us to use sternal head component separation from the clavicular head and interposed them between the repaired trachea and esophagus. Preserving the clavicular head of SCM maintains the form and function of the muscle. The vascularized muscle flap prevents both tracheal and oesophageal strictures and stenosis.

### **References**

1. Sabiston and Spencer, Surgery of chest, edition 8, section 1, thoracic surgery, Elsevier, p. 113.
2. Mark Urken, Atlas of head and neck flap, chapter 3, 2<sup>nd</sup> edition, Lippincott Williams and Wilkins, 2012, p. 53.
3. The arterial anatomy of skin flap by Cormack and Lamberty, chapter 7, Churchill Livingstone, 1986, p. 332.
4. Grab's encyclopedia of flaps head and neck, 3<sup>rd</sup> edition, vol 1, chapter 190, Lippincott Williams and Wilkins, 2008, p. 554.
5. Mathes and Nahai, Anatomy and basic techniques head & neck regional flaps, section 5G, p. 357.
6. McCraw & Arnold's Atlas of muscle & musculocutaneous flaps, chapter sternocleidomastoid, page 35.
7. Stephen J Matches, Foad Nahai, Clinical applications for muscle & musculocutaneous flaps, chapter 2, page 38.
8. Couraud L, Bercovici D, Zanotti L, et al. Treatment of often fistulas esophageal - tracheales from réanimation. Ann Chir Thorac Cardiovasc., 1989; 43: 677-681.
9. Couraud L, Ballester ML. Tracheoesophageal fistula Delaisement C. Acquired and STI management. SeminThoracCardiovasc Surg., 1998; 8: 392-399.
10. Wesselhoeft CW Jr, Keshishian JM. Acquired nonmalignant esophagi tracheal and esophagobronchial fistula. Ann Thorac Surg., 1968; 6: 187-95.
11. Mathisen DJ, Grillo HC, Wain JC, Hilgenberg AD. Management of acquired nonmalignant tracheoesophageal fistula. Ann Thorac Surg., 1991; 52: 759-65.
12. Payne DK, Anderson WM, Romero MD, Wissing DR, Fowler M. Tracheoesophageal fistula formation in intubated Patients. Chest, 1990; 98: 161-164.