

Original Research Article


Conventional D.C.R vs D.C.R implant method in chronic dacryocystitis

Manjula Mangane^{1*}, Vishwanath Reddy², Rajashree Reddy³

¹Assistant Professor, ²Professor and Head, ³Associate Professor

Department of Ophthalmology, MR Medical College, Gulbarga, Karnataka, India

*Corresponding author email: drmanjulamangane@gmail.com

	International Archives of Integrated Medicine, Vol. 4, Issue 11, November, 2017. Copy right © 2017, IAIM, All Rights Reserved. Available online at http://iaimjournal.com/	
	ISSN: 2394-0026 (P)	ISSN: 2394-0034 (O)
	Received on: 29-10-2017	Accepted on: 08-11-2017
	Source of support: Nil	Conflict of interest: None declared.
How to cite this article: Mangane M, Reddy V, Reddy R. Conventional D.C.R vs D.C.R implant method in chronic dacryocystitis. IAIM, 2017; 4(11): 259-263.		

Abstract

Background: Chronic dacryocystitis is the commonest cause of lacrimal passage obstruction indicates inflammation of lacrimal sac. Dacryocystorhinostomy (DCR) is the preliminary choice of surgical procedure in which lacrimal sac is connected with nasal mucosal flap by bypassing nasolacrimal duct.

Objectives: This comparative study described and evaluated the effectiveness of conventional D.C.R method and D.C.R implant method in chronic dacryocystitis cases.

Materials and methods: The present comparative study consisted of 200 patients with complaint of watering, pus discharge and diagnosed as chronic dacryocystitis. Out of which 160 cases were followed up for a period of 3-6 months. Study cases were operated by using "Pawar implant".

Results: Bleeding occurred during operation was much more in conventional D.C.R. (53.3%) method than D.C.R. implant method (7.7%). Complete patency of nasolacrimal duct was observed in 125 cases i.e. 76 cases in D.C.R. implant method, 35 cases in Conventional D.C.R. method and 14 cases in D.C.R implant after D.C.T done. Partial patency of naso lacrimal duct was observed in 22 cases and failure of patency was seen in 11 cases.

Conclusion: D.C.R implant (Pawar Implant) method is secure, minimal time consuming, needs little incision, little bony ostium and less painful surgical modality for chronic dacryocystitis than conventional D.C.R method.

Key words

Chronic dacryocystitis, Dacryocystorhinostomy (DCR), Pawar Implant, Conventional DCR method.

Introduction

Dacryocystitis is a common eye disease causes inflammation of lacrimal sac, which is usually unilateral and occurs secondary to obstruction of the nasolacrimal duct [1]. Dacryocystorhinostomy (DCR) is a preliminary choice of surgical procedure by which lacrimal fluid is diverted in to the nasal cavity through an artificial opening made at the levels of the lacrimal sac [2, 3]. Conventional DCR is the most preferred surgical procedure for nasolacrimal duct obstruction which has drawbacks like hemorrhage, time consuming and requires large size (12-14mm) ostium. To overcome these drawbacks, new surgical procedure have come in to existence like implant DCR, conjunctival DCR, endonasal DCR and canalicular DCR to treat chronic dacryocystitis. To minimize complications associated with convention DCR, Dr. M.D Pawar introduced intracystic silicone implant between lacrimal sac and nasal cavity [4, 5].

With the above facts that the present study was designed to assess the efficacy of conventional D.C.R with D.C.R implant in chronic dacryocystitis cases.

Materials and methods

The present comparative study was conducted in department of ophthalmology, MR Medical College, Gulbarga during 2015 to 2016. A total two hundred patients with complaint of watering, pus discharge and diagnosed as chronic dacryocystitis were considered. A detailed history of symptoms, associated diseases of nose and sinuses were noted and local examination of lacrimal excretory system, nose and sinuses under specific details were conducted. Radiological examination of PNS by X-ray, Schirmer test and dacryocystogram was performed based on necessity. A complete haemogram, cardiovascular examination and respiratory examination was performed. Depends on the investigations and fitness patient is operated by conventional D.C.R or D.C.R implants. In present study, two hundred cases of

chronic dacryocystitis were operated and used “Pawar implant”, out of which 160 cases were followed up for a period of 3-6 months.

Based on operated method, patients were divided in to following two groups:

Group 1: consists of 45 cases of chronic dacryocystitis were operated by conventional method of dacryocystorhinostomy. Group 1 cases again sub divided in to 2 sub-groups as follows sub-group (i) consisted of 4 patients having bilateral chronic dacryocystitis and sub-group (ii) consisted of 41 patients having unilateral chronic dacryocystitis.

Group 2: consisted of 115 cases of chronic dacryocystitis were operated by D.C.R. implant method. Group 2 cases again sub-divided into 3 sub-groups as follows- sub-group (i) – consisted of 10 cases of chronic dacryocystitis having bilateral involvement, Sub-group (ii) – consisted of 80 cases of chronic dacryocystitis were unilateral involvement occurred and Sub-group (iii) – consisted of 25 cases where already D.C.T. was done.

Results

In present study, two hundred cases of chronic dacryocystitis were operated and used “Pawar implant”, out of which 160 cases were followed up for a period of 3-6 months. Results were depicted in **Figure – 1** and **Table – 1 to 6**.

Discussion

Dacryocystitis is the commonest cause of lacrimal passage obstruction indicates inflammation of lacrimal sac [7]. The ancient treatment modality for this condition was excision of sac, whereas in modern era, most preferable surgical choice is dupuy dutemps [8]. D.C.R (Dacryocystorhinostomy) is the preliminary choice of surgical procedure for chronic dacryocystitis which involves removal of bone adjacent to the nasolacrimal sac and incorporating the lacrimal sac with the lateral nasal mucosa in order to bypass the nasolacrimal duct obstruction [9]. This study was organized to

evaluate the efficacy of conventional D.C.R with D.C.R implant in chronic dacryocystitis.

In present study, highest incidence of dacryocystitis was found in the age group of 21-30 years in both genders (Figure - 1). This difference was due to the fact that specific

infections are common in males while females are suffered from chronic irritation due to smoke and their daily household activities [10]. An anatomic study performed by using radiological methods, diameter of nasal canal in women was found to be relatively smaller than those encountered in men [11].

Figure - 1: Age and sex of cases.

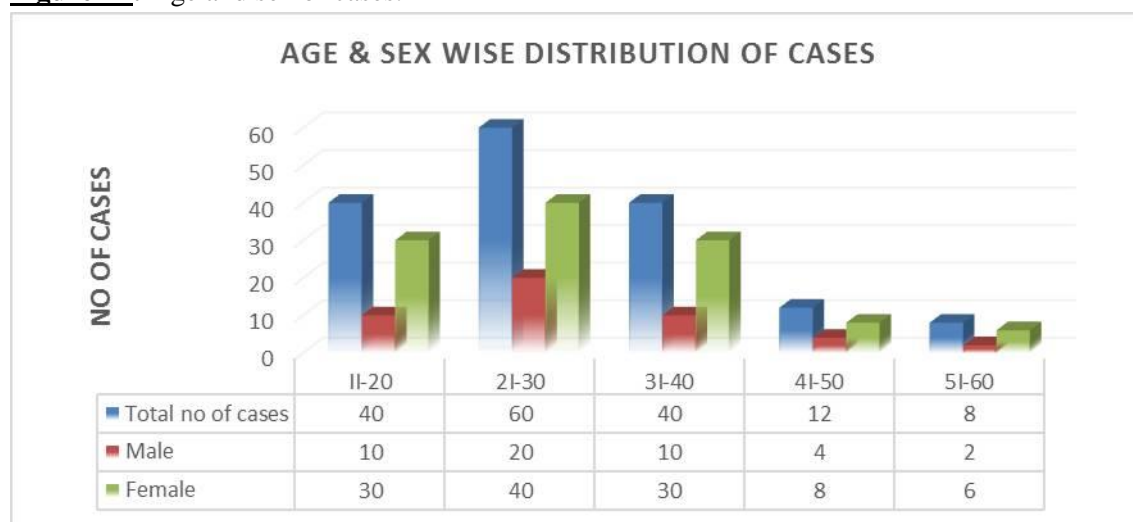


Table - 1: Side involvement of eye.

Type of operation	No. of cases	Side of eye involved		
		Right Eye	Left Eye	Both eyes
Conventional D.C.R.	45	15	26	4
D.C.R. implant method	90	32	48	10
D.C.R implant after D.C.T	25	9	10	5

Table - 2: Presenting symptoms in total cases.

Presenting symptoms	No. of patients	Percentage
Watering	106	66.25%
watering + swelling in sac area	5	3.12%
Mucopurulent discharge	27	16.9%
Mucopurulent discharge + swelling over sac	8	5%
Mucopurulent discharge + watering	9	5.62%
Mucopurulent discharge + Fistula in sac area	5	3.12%

Table - 3: Associated diseases with chronic dacryocystitis.

Associated diseases	Percentage
Conjunctivitis	68%
Deviated nasal septum	20%
Hypertrophied nasal mucosa	76%
Maxillary sinusitis	39%
Trachoma	69%

Table - 4: Incidence of bleeding during surgical procedure.

Mode of surgery	Total No. of cases	No. of cases where bleeding occurred during operation
Conventional D.C.R	45	24 (53.3%)
D.C.R implant method	90	7 (7.7%)
D.C.R implant after D.C.T	25	5 (20%)

Table - 5: Incidence of obstruction of bony opening during operative procedure.

Type of operation	Total no. of cases	Occlusion occurred
Conventional D.C.R	45	8 (17.7)
D.C.R implant method	90	-
D.C.R implant after D.C.T	25	5 (20%)

Table - 6: Patency of naso lacrimal duct.

Mode of operation	No. of cases	Patency of nasolacrimal duct					
		Complete patency		Partial patency		No patency	
		Number	%	Number	%	Number	%
Conventional D.C.R	45	35	77.7%	7	15.5%	3	7.5%
D.C.R implant method	90	76	84.4%	9	10%	5	5.5%
D.C.R implant after D.C.T	25	14	56%	6	24%	3	12%

Among total chronic dacryocystitis cases, 121 (75.6%) cases had unilateral involvement and 14 cases had bilateral involvement of the eye (**Table - 1**). Left eye was most affected in unilateral involvement with the unknown reason. Studies suggested the left eye was most commonly affected than right side with an unknown cause [12]. In addition to chronic dacryocystitis, 106 cases had watering and 27 cases had mucopurulent discharge. The most common associated symptoms are mucopurulent discharge with watering in 83.1% cases (**Table - 3**).

In this study, due to obstruction of bony opening drainage occluded in 8 (17.7%) cases in conventional D.C.R. method, in which deviated nasal septum was associated. No such occlusion of drainage was reported in D.C.R. implant method, but 5 (20%) cases were reported where D.C.T. was already done (**Table - 3**). Bleeding occurred during operation was much more in conventional D.C.R. (53.3%) method than

D.C.R. implant method (7.7%) (**Table - 4**). Studies suggested that high rates of haemorrhage during surgery are major drawback of conventional D.C.R [13].

Complete patency of nasolacrimal duct was observed in 125 cases i.e. 76 cases in D.C.R. implant method, 35 cases in Conventional D.C.R. method and 14 cases in D.C.R implant after D.C.T done. Partial patency of naso lacrimal duct was observed in 22 cases and failure of patency was seen in 11 cases (**Table - 6**).

Conclusion

Diseases of conjunctival sac, nose and para-nasal sinuses also contribute in the obstruction of nasolacrimal passage. The mobility of patients was observed earlier where D.C.R. implant method was adopted than the conventional D.C.R. method. Bleeding occurred during operation was much more in conventional D.C.R. (53.3%)

method than D.C.R. implant method (7.7%). Conventional D.C.R. method is a time consuming process than D.C.R. implant method. The patency of naso-lacrimal duct was observed. Much better results are seen in D.C.R. implant method than conventional D.C.R. method.

References

1. Leong SC, MacEwen C, White PS. A systemic review of outcomes after dacryocystorhinostomy in adults. *American journal of rhinology & allergy*, 2010 Jan 1; 24(1): 81-90.
2. Jones LT. The cure of epiphora due to canalicular disorders, trauma and surgical failures on the lacrimal passages. *Trans Am Acad Ophthalmol Otolaryngol.*, 1962; 66: 506.
3. Trimarchi M, Giordano Resti A, Bellini C, Forti M, Bussi M. Anastomosis of nasal mucosal and lacrimal sac flaps in endoscopic dacryocystorhinostomy. *Eur Arch Otorhinolaryngol.*, 2009; 266: 1747-52.
4. Lele SS, Pawar MD, Sune PG. A comparative study between implant DCR and Conventional DCR in the case of blockage of Nasolacrimal duct. 60th annual conference of AIOS 2002, proceedings, p. 508-10.
5. Pawar MD, Patil SN. *acta xxv concilium ophthalmologic*, 1987; 1988-92. .
6. Marcet, Marcus M., Andrew KT Kuk, Paul O. Phelps. Evidence-based review of surgical practices in endoscopic endonasal dacryocystorhinostomy for primary acquired nasolacrimal duct obstruction and other new indications. *Current opinion in ophthalmology*, 2014; 25(5): 443-448.
7. Duke elder S, Macfaul PA. Disease of lacrimal passage in System of ophthalmology. St Louis: CV Mosbv, 1974, p. 674-770.
8. Tsirbas A, Davis G, Wormald PJ. Revision dacryocystorhinostomy: a comparison of endoscopic and external techniques. *Am J Rhinol.*, 2005; 19: 322-5.
9. Wormald PJ. Powered endoscopic dacryocystorhinostomy. *Otolaryngol Clin N Am.*, 2006; 39: 539-49.
10. Savino G, Battendieri R, Traina S. External vs endonasal dacryocystorhinostomy: has the current view changed? *Acta Otorhinolaryngologica Italica*, 2014; 34: 29-35.
11. Francis IC, Stapleton F, Wilcsek G. Symptom assessment in patients with functional and primary acquired nasolacrimal duct obstruction before and after successful dacryocystorhinostomy surgery: a prospective study. *Br J Ophthalmol.*, 2007; 91: 1671-4.
12. Mukerjee P.K., Jain P.C. Irritation of nasolacrimal duct with polythene tube. *Ind. J. Ohthalmol.*, 1972; 20: 16.
13. Fayet B, Racy E, Assouline M. Complications of standardized endonasal dacryocystorhinostomy with unciformectomy. *Ophthalmology*, 2004; 111: 837-45.