


Original Research Article

# Ovarian tumors - Incidence and histopathological spectrum in tertiary care center, Valsad

Amita S Patel<sup>1</sup>, Jignasha M Patel<sup>2\*</sup>, Kamlesh J Shah<sup>3</sup>

<sup>1</sup>Assistant Professor, <sup>2</sup>Associate Professor, <sup>3</sup>Professor and Head  
Department of Pathology, GMERS Medical College, Valsad, Gujarat, India

\*Corresponding author email: [dr.jignashapatel@gmail.com](mailto:dr.jignashapatel@gmail.com)

	International Archives of Integrated Medicine, Vol. 5, Issue 2, February, 2018. Copy right © 2018, IAIM, All Rights Reserved. Available online at <a href="http://iaimjournal.com/">http://iaimjournal.com/</a> ISSN: 2394-0026 (P)                      ISSN: 2394-0034 (O)
	Received on: 30-01-2018                      Accepted on: 05-02-2018 Source of support: Nil                      Conflict of interest: None declared.
	<b>How to cite this article:</b> Amita S Patel, Jignasha M Patel, Kamlesh J Shah. Ovarian tumors - Incidence and histopathological spectrum in tertiary care center, Valsad. IAIM, 2018; 5(2): 84-93.

## Abstract

**Introduction:** Ovarian tumors are now the one of the leading cause of death involving a wide spectrum of clinical, morphological and histopathological diagnosis. It frequently does not result in symptoms until the tumor has spread extensively and pose difficulties to clinicians.

**Objectives:** The aim was to study the incidence and histopathological spectrum of ovarian tumors according to WHO classification in different age group and its clinical correlation.

**Materials and methods:** A study was undertaken during a period of May 2011 to December 2017. The tumors were classified according to WHO classification after thorough examination of H&E slides. Data of clinical presentation of patient was also recorded in each case.

**Results:** There were total 162 cases were studied, amongst which surface epithelial tumors were the commonest variety accounting for 126(77.7%) cases, followed by Germ cell tumors 30(18.5%) cases and Sex-cord stromal tumors 6(3.8%) cases. Benign tumors (93.2%) were more common than malignant (6.2%) and borderline (0.6%). Among benign tumors, serous cystadenoma (57.4%) were the most common followed by mucinous cystadenoma (16%) and mature teratoma (16%). Most of the ovarian tumors were unilateral (89.5%) with left sided predominance (49.4%). Majority of benign tumors presented with cystic consistency (67.9%) and mixed consistency (4.3%) in malignant tumors. The age range was 4 year to 70 years. Abdominal pain (48.8%) was the commonest clinical presentation.

**Conclusion:** Ovarian tumors were found to occur in wide range of age with bimodal peak for malignant tumors. Benign tumors were more common across the all age group. An accurate histopathological diagnosis and staging is important for therapeutic and prognostic purpose.

## Key words

---

Ovarian tumors, Histopathological distribution, Clinical presentation, Bilaterality.

## Introduction

---

Ovaries are paired organs situated on either side of the uterus in the pelvis and the common yet complex site for occurrence of neoplasm in women [1]. The ovaries consist of totipotent sex cells and multipotent mesenchymal cells which play an important role in a wide morphological spectrum of neoplasms involving a variety of histopathological diagnosis ranging from tumors arising from epithelial tissues, connective tissue, germ cells, embryonic cells and metastatic non-ovarian tumors [2, 3].

Ovarian cancer is the sixth most common cancer (age standardized incidence rate: 6.6/100,000) and the seventh leading cause of cancer deaths (age standardized mortality rate: 4.0/100,000) among women worldwide [4, 5]. According to the population-based cancer registries in India, ovarian cancer is the third leading site of cancer among women next to cervix and breast cancer and comprising up to 8.7% of cancer in different parts of the country [4, 5]. The ovarian tumor has the highest fatality-to-case ratio to all the gynecologic cancers [6].

The overall 5 year survival rate is less than 50% because of lack of specific screening test and its asymptomatic nature so early diagnosis is difficult [7].

About 80% of ovarian tumors are benign and occur in young women between the ages of 20 and 45 whereas 20% are malignant tumors common in older women between ages of 40 and 65 having poor prognosis [8, 9]. The risk factors are not much clear but the incidence is high in postmenopausal women, unmarried women or in married women with low parity, family history and heritable mutation [1]. Factors that decrease risk include oral contraceptives, tubal ligation and breast feeding. Only 10-15% is discovered in pre-menopausal women [6].

Tumor markers like Serum HCG, serum CA125, serum alpha – fetoprotein, placental alkaline phosphatase and lactate dehydrogenase, newer diagnostic techniques like FNAC, ultrasonography and proper clinical evaluation are useful tools for early diagnosis. The definitive diagnosis and typing of tumor however is by histopathological study. Screening of ovarian tumor may be improved by molecular genetic study and accordingly new therapeutic modalities have been established.

The aim of this study was to study the incidence, histopathological spectrum according to WHO classification and clinical correlation of ovarian tumors.

## Materials and methods

---

The present retrospective study was carried out in the Department of Pathology, GMERS Medical College, Valsad from May 2011 to December 2017. A total 162 ovarian masses were studied within this period, which were received either as solitary specimens, or as a part of total abdominal hysterectomy specimens. Only the specimens of ovarian tumors under WHO classification were considered in this study. The normal ovaries and the ovaries with other findings like follicular cyst, cystic follicles, surface inclusion cysts, hemorrhagic inclusion cysts, ectopic pregnancy and endometriosis were excluded from the study.

A detailed history, clinical examination, relevant laboratory investigation were obtained from the patients, histopathology requisition forms and wherever required from the medical record section.

The excised specimens of ovaries were fixed in 10% formalin. The tumors were weighed and measured, and their exterior examined. From cysts, up to 3 sections of 3 mm were taken and from solid tumors, one section for each

centimeter was taken especially from areas with papillary appearance and any unusual area (hemorrhagic, calcification or necrotic area). Also one section of non - neoplastic ovary was taken where it was identifiable. After sectioning tissues were processed. After processing, paraffin blocks were made. The tissue sections of 5mm were cut and stained by Hematoxylin and Eosin. The sections were cleared by xylene and mounted on a glass slide. These slides were then examined under a light microscope for a histopathological diagnosis. The histopathological diagnosis was based on morphologic features and the tumors were classified according to WHO classification.

## Results

A retrospective study of ovarian tumors was carried out at the Department of Pathology, GMERS Medical College, Valsad, Gujarat, from May 2011 to December 2017. A total of 162 cases were studied out of which 151(93.2%) cases were benign tumor, 1(0.6%) case was borderline tumor and 10(6.2%) cases were malignant tumor (**Table - 1**). These tumors were classified according to WHO classification and categorized into 4 main groups. Surface epithelial tumors constituted majority of the ovarian neoplasm with 126(77.7%) cases, followed by Germ cell tumor which constituted 30(18.5%) case, Sex cord - stromal tumors 6(3.8%) cases and Metastatic tumors were not found in our study (**Table - 2**).

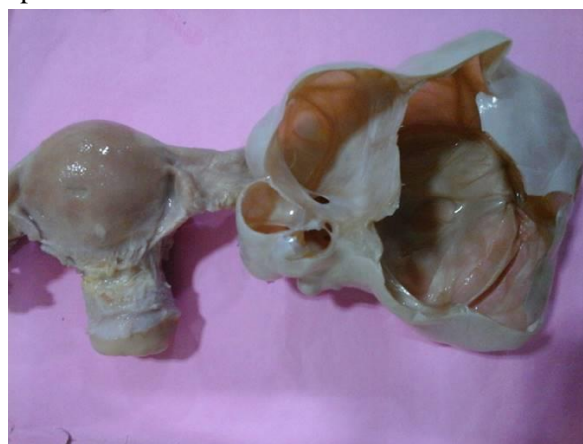**Table - 1:** Incidence of various ovarian tumors.

Nature of tumor	Total no	%
Benign	151	93.2
Borderline	1	0.6
Malignant	10	6.2
Total no.	162	100

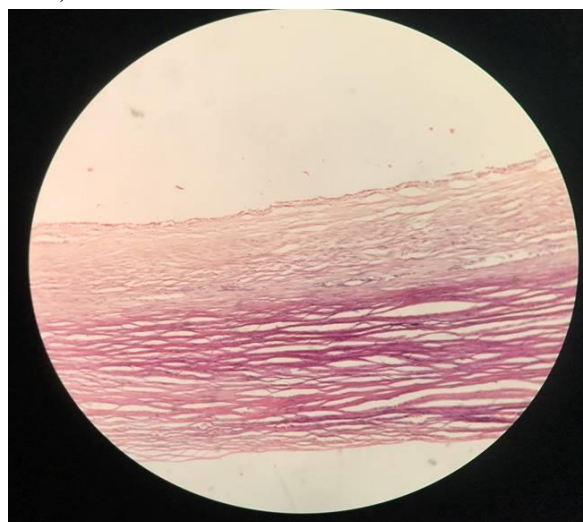
Out of 126 cases of surface epithelial tumors, serous tumors comprised about 95(75.4%), mucinous tumors about 30(23.8%) and transitional cell tumor 1(0.8%) case.

Out of 126 cases of surface epithelial tumors, serous cystadenoma (**Figure - 1, 2**) was the most common benign tumor comprised about 93(73.8%) cases then mucinous cystadenoma 26(20.6%) cases. Other benign tumor reported was benign brenner tumor 1(0.8%) case. 1(0.8%) case of borderline mucinous cystadenoma with low malignant potential was reported. Malignant surface epithelial tumor comprised serous cystadenocarcinoma about 2(1.6%) cases and mucinous cystadenocarcinoma (**Figure - 3, 4**) about 3(2.4%) cases.

**Figure - 1:** Serous cystadenoma ovary, gross specimen.



**Figure - 2:** Serous cystadenoma (H&E stain, 10X).



Out of 30 cases of germ cell tumors 26(16%) cases were of benign mature teratoma (**Figure - 5, 6**), 2(1.3%) cases of Dysgerminoma, 1(0.6%)

case of immature teratoma and 1(0.6%) case of yolk sac tumor.

sex cord-stromal tumors 5(3.1%) cases were fibroma and 1(0.6%) case was granulosa cell tumor.

Sex cord- stromal tumors comprised only 6(3.8%) cases of all ovarian tumors. In 6 cases of

**Table - 2:** Histopathological spectrum of ovarian tumors according to WHO classification.

Histopathological diagnosis	Nature of tumor	Types	No. of cases	%
Surface epithelial - stromal tumor	Serous	Benign	93	57.4
		Borderline	0	0
		Malignant	2	1.3
	Mucinous	Benign	26	16
		Borderline	1	0.6
		Malignant	3	1.9
	Endometrioid	Benign	0	0
		Borderline	0	0
		Malignant	0	0
	Transitional cell tumor (Brenner tumor)	Benign	1	0.6
		Borderline	0	0
		Malignant	0	0
Epithelial-stromal	Adenosarcoma	0	0	
Sex cord - stromal tumor	Granulosa - theca cell tumor		1	0.6
	Fibroma – thecomas		5	3.1
	Sertoli- Leydig cell tumor		0	0
	Other sex cord stromal tumors		0	0
Germ cell tumor	Immature teratoma		1	0.6
	Mature teratoma		26	16
	Dysgerminoma		2	1.3
	Yolk sac tumor		1	0.6
	Mixed germ cell tumor		0	0
Metastatic non ovarian tumors	-		0	0
Total			162	100

Age range from 4 to 70 years with majority of cases included among 31-40 years age group, 55(34%) cases with mean age is 38 year. The youngest patient was a 4 year female child with immature teratoma, and the oldest patient was 70 years female, a case of serous cystadenocarcinoma (**Table - 3**).

consistency (110 cases; 67.9% of total lesions) while few cases had both solid and cystic consistency. One case in borderline group was cystic grossly while malignant lesions were solid (3 cases; 1.9%) and mixed (7 cases; 4.3%) in consistency (**Table - 4**).

Gross examination of the specimens revealed that majority of the tumors were cystic 111(68.5%) cases followed by mixed 41(25.3%) cases and solid which comprise 10(6.2%) cases. Majority of the benign lesions were cystic in

Based on site of involvement, majority of tumors were unilateral 145(89.5%) cases. Involvement of left ovary (80 cases; 49.4%) was more common than the right (65 cases; 40.1%). Bilaterality was seen in 17(10.5%) cases. The bilateral tumors were serous cystadenoma (10),

mature cystic teratoma (4), mucinous cystadenoma (2) and mucinous cystadenocarcinoma (1). Bilaterality was seen in 16 (94.1%) benign cases and 1(5.9%) malignant case (**Table - 5**). Comparing the clinical presentation of patients, we found out that the most common clinical presentation was pain in abdomen in 79(48.8%) cases followed by mass in the lower abdomen 34(20.9%) cases and menorrhagia in 31(19.1%) cases. Postmenopausal bleeding was seen in 3(1.9%) cases (**Table - 6**).

**Table - 3:** Age distribution among ovarian tumors.

Age range (years)	Benign tumors		Borderline tumors		Malignant tumors		Total	
	Cases No.	%	Cases No.	%	Cases No.	%	Cases No.	%
≤10	0	0	0	0	1	0.6	1	0.6
11-20	8	4.9	0	0	2	1.2	10	6.1
21-30	38	23.5	0	0	0	0	38	23.5
31-40	55	34	0	0	0	0	55	34
41-50	34	20.9	0	0	4	2.6	38	23.5
51-60	12	7.4	1	0.6	2	1.2	15	9.2
≥61	4	2.5	0	0	1	0.6	5	3.1
Total	151	93.2	1	0.6	10	6.2	162	100

**Table - 4:** Consistency of ovarian tumors.

Consistency	Benign tumors	Borderline tumors	Malignant tumors	Total (%)
Cystic	110	1	0	111 (68.5%)
Solid	7	0	3	10 (6.2%)
Cystic and solid (mixed)	34	0	7	41 (25.3%)

**Table - 5:** Site of involvement of ovarian tumors.

Laterality of tumor	Unilateral		Bilateral
	Right	Left	
Benign tumors	62	73	16
Borderline tumors	0	1	0
Malignant tumors	3	6	1
Total	65 (40.1%)	80 (49.4%)	17 (10.5%)

**Table - 6:** Clinical presentation of patients with ovarian tumors.

Clinical presentation	No. of patients	%
Abdominal pain	79	48.8
Abdominal mass	34	20.9
Menorrhagia	31	19.1
Abdominal pain + mass	9	5.5
Abdominal pain + menorrhagia	4	2.4
Post-menopausal bleeding	3	1.9
Dysmenorrhea	1	0.6
Uterine prolapse	1	0.6
Total	162	100

**Table - 7:** Comparison of percentage incidence of ovarian tumors in various studies.

Authors	Benign tumors	Borderline tumors	Malignant tumors
Sawant A, et al. [2]	75.7%	6.06%	18.2%
Singh S, et al. [8]	80.8%	1.6%	20%
Thakkar N, et al. [9]	84.5%	2.3%	13.2%
Couto, et al. [12]	80.7%	2.3%	16.9%
Maheshwari V, et al. [13]	71.7%	4.4%	23.7%
Pilli, et al. [14]	76%	2.8%	21.2%
Gupta N, et al. [15]	72.9%	22.9%	4.2%
Badge A, et al. [16]	74%	5%	21%
Wills V, et al. [17]	91.1%	1.8%	7.1%
Mankar D, et al. [18]	63.0%	5.8%	31.1%
Puttaveerachary A, et al. [19]	84%	4%	12%
Present study	93.2%	0.6%	6.2%

**Table - 8:** Comparison of different histopathological types of ovarian tumors.

Authors	Surface epithelial tumor	Germ cell tumor	Sex cord-stromal tumor
Sawant A, et al. [2]	84.8%	9.1%	6.1%
Singh S, et al. [8]	69.1%	25.8%	4.1%
Pilli, et al. [14]	71%	21%	7%
Gupta N, et al. [15]	65.6%	23.9%	8.3%
Kancherla J, et al. [20]	80%	16%	4%
Bhagyalakshmi A, et al. [21]	80.2%	14.2%	4.1%
Ahmed Z, et al. [22]	63.5%	27.1%	5.8%
Tejeswini V, et al. [23]	85.2%	9.7%	3.9%
Present study	77.7%	18.5%	3.8%

**Table - 9:** Comparison of laterality of ovarian tumors in various studies.

Authors	Laterality	
	Unilateral	Bilateral
Thakkar N, et al. [9]	88.4%	11.6%
Couto F, et al. [12]	91.2%	8.8%
Prabakar B, et al. [26]	90.9%	9.1%
Prakash A, et al. [27]	90.8%	9.2%
Miska R, et al. [28]	95.5%	4.505
Present study	89.5%	10.5%

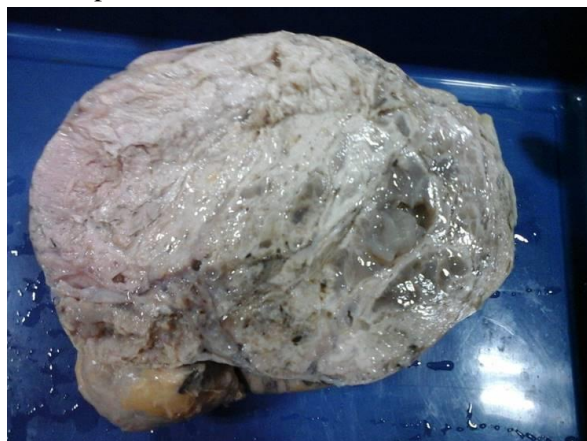## Discussion

Ovarian neoplasm has become increasingly important not only because of its large variety of histomorphological patterns but more because they have gradually increased the mortality rate in female genital cancers because of its vague symptoms and diagnosed in advanced stage. The

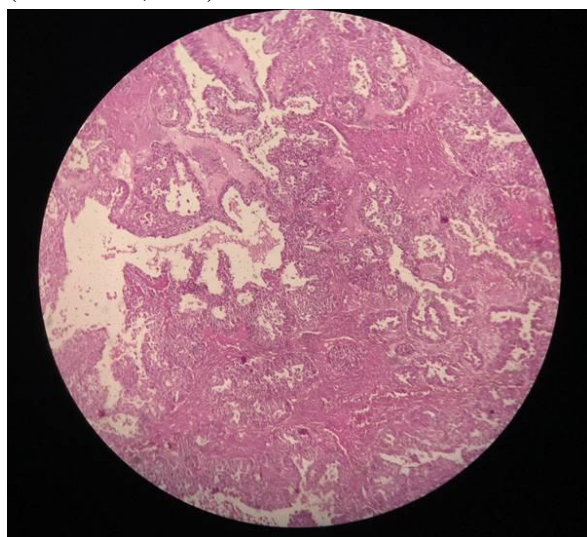
incidence, clinical appearance and the behavior of the different types of ovarian tumors is extremely variable. It is generally impossible to diagnose the nature of the ovarian tumor just by clinical or gross examination, although it provides important diagnostic clues in formulating a differential diagnosis. Hence, one has to depend on the microscopic appearance of the tumor for accurate typing of the ovarian tumors [10, 11].

A total of 162 cases of ovarian tumors were documented in this study period, out of which benign tumors comprised of 151(93.2%) cases, borderline tumor 1(0.6%) cases and malignant tumors 10(6.2%) cases. Almost similar results were seen in many different studies where benign tumors were more common than malignant tumors [2, 8, 9, 12-19] (Table- 7).

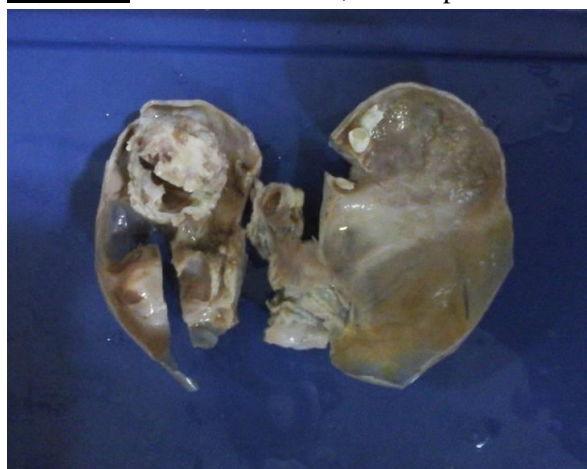**Figure - 3:** Mucinous cystadenocarcinoma - Gross specimen.



**Figure - 4:** Mucinous cystadenocarcinoma ovary (H&E stain, 10X).



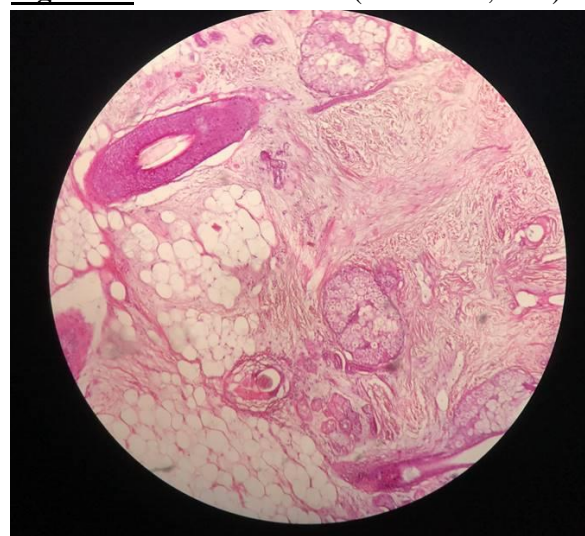
**Figure - 5:** Mature teratoma, Gross specimen.



Ovarian tumors were classified according to WHO classification. Among the different

histopathological patterns, Surface epithelial tumors constituted majority of the ovarian neoplasm with 126(77.7%) cases, followed by Germ cell tumors of 30(18.5%) cases and Sex cord stromal tumors were in 6(3.8%) cases. Metastatic tumor was not found in present study. This agrees with Sawant A, et al. [2], Singh S, et al. [8], Pilli, et al. [14] and others [15, 20-23] (Table - 8).

**Figure - 6:** Mature teratoma (H&E stain, 10X).



In western country, serous tumors account for about 30.0% of all ovarian neoplasm, out of which 60.0% are benign, 10.0% are borderline and 30% are malignant. Similarly mucinous tumors account for 12.0-15.0% of all ovarian tumors. Approximately 75.0% mucinous tumors are benign, 10.0% are borderline and 15.0% are malignant [24]. In this study serous tumors constituted 58.7% of all ovarian tumors. This figure was 48%, 42.9% and 32.7% other studies [14, 25, 26]. Mucinous tumors here comprised 18.5% of all ovarian tumors whereas these figures were 30%, 25.5% and 25.0% in other studies [14, 25, 26].

Among the serous tumors, serous cystadenoma constituted 57.4% was the most common benign tumor and serous cystadenocarcinoma was 1.3%. It is similar to the findings reported by Maheshwari V, et al. [13], Wills V, et al. [17] and Ahmad, et al. [22].

From mucinous tumors, cystadenoma constituted 16% was the second common surface epithelial tumor, 1.9% cystadenocarcinoma and 0.6% with borderline pathology in this study which were similar to results of Maheshwari V, et al. [13] and Wills V, et al. [17]. In present study 1(0.6%) case of benign brenner tumor was also diagnosed.

In this study germ cell tumors accounted the second most common tumor 18.5% of all ovarian tumors, similar to the findings of many other studies listed in table-8. Among 30 cases of germ cell tumors, mature teratoma was the commonest about 16% of all ovarian tumors which is equal to mucinous cystadenoma (16%). Among malignant tumors, immature teratoma had the youngest group of patients comprising 0.6% and other 1.3% of dysgerminoma and 0.6% of yolk sac tumor was reported as malignant germ cell tumor. This result correlated with studies by Thakkar N, et al. [9], Prabakar B, et al. [26], Prakash A, et al. [27] and Miska R, et al. [28].

Sex cord-stromal tumors comprises of only 3.8% of total ovarian tumors, of which 3.1% of fibroma and 0.6% of granulosa cell tumor. The incidence was very close to the finding of Thakkar N, et al. [9].

Ovarian tumor were unilateral in 89.5% of cases and bilateral in 10.5% of cases which is correlated with studies by Thakkar N, et al. [9], Couto F, et al. [12], Prabakar B, et al. [26] and Miska R, et al. [28]. Involvement of left ovary (49.4%) was more common than the right (40.1%) this coinciding with the findings of other study done by Couto F et al [12]. Among all benign tumors, majority were unilateral (83.3%) and most of malignant tumors were also unilateral (5.5%) which were similar to the studies by Thakkar N, et al. [9], Prabakar B, et al. [26], Prakash A, et al. [27] and Miska R, et al. [28] (**Table - 9**).

Majority of the ovarian tumors were grossly cystic in 68.5% cases followed by cystic and solid mixed tumors in 25.3% cases and 6.1%

cases were solid tumors. Majority of the tumors in benign groups were cystic (67.9%). Mixed consistency was common in the malignant tumor (4.3%). These findings were correlated with studies done by Thakkar N, et al. [9] and Miska R, et al. [28].

In present study, maximum numbers of patient were from age group of 31 to 40 years of age (34%). Kancherla, et al. [20] and Jha, et al. [29] showed majority of ovarian tumors, among 31-40 years of age. Benign tumors were most commonly reported in reproductive age group from 20 to 40 years of age and malignant surface epithelial tumors were reported in more than 40 years of age group, while malignant germ cell tumors were reported in younger age group from 1 to 20 years of age.

In present study, almost half of the patients (48.8%) had complained of vague abdominal pain followed by mass in abdomen (20.9%) and menorrhagia (19.1%). 7.9% of patients presented with combination of abdominal pain, abdominal mass and menorrhagia. Other clinical findings in present study were post-menopausal bleeding (1.9%), dysmenorrhea (0.6%) and uterine prolapse (0.6%). These findings are in concordance with studies done by Thakkar N, et al. [9] and Prakash A, et al. [27].

## **Conclusion**

Benign ovarian tumors were more common than malignant and seen in all age groups with predominance between 31 to 40 years. Based on histopathology, surface epithelial tumor were the most common variant- serous tumors, then mucinous tumor followed by germ cell tumors. Incidences of malignant tumor were quite low then other studies. Vague abdominal pain was the single most common clinical presentation. So correlation of clinical examination, radiological findings and gross morphology can give important clues for diagnosis. Hence here is the crucial role of the microscopic appearance of the tumor for further management. Currently, a major goal of ovarian cancer research is to



develop an effective screening test that can detect the disease at its earliest stages, which would ultimately result in decreased mortality. This study has shown the occurrence of younger and elder age groups in the primary malignant ovarian tumors. Hence this study emphasizes that in a young female with ovarian mass the possibility of malignancy should not be neglected. The classification of ovarian tumor is primarily morphologic but is meant to reflect current concepts of embryogenesis and histogenesis of this complex organ.

## References

1. Christopher P Crum. The female genital tract. In: Kumar, Abbas, Facusto editors Robbins and Cotton Pathologic Basis of Disease. 7<sup>th</sup> edition. India: Elsevier; 2004, p. 1093-1104.
2. Sawant A, Mahajan S. Histopathological Study of Ovarian Lesions at a Tertiary Health Care Institute. MVP Journal of Medical Sciences, 2017; 4(1): 26–29.
3. Padubidri VG, Daftery SN. Disorders of ovary. In: Howkins & Bourne. Shaw's. Textbook of Gynecology. 13<sup>th</sup> edition, Churchill Livingstone, London; 2004, p. 352-485.
4. Basu P, De P, Mandal S, Ray K, Biswas J. Study of 'patterns of care' of ovarian cancer patients in a specialized cancer institute in Kolkatta, eastern India. Indian J Cancer, 2009; 46(1): 28–33.
5. Mondal SK, Banyopadhyay R, Nag DR, Roychowdhury S, Mondal PK, Sinha SK. Histologic pattern, bilaterality and clinical evaluation of 957 ovarian neoplasms: A 10-year study in a tertiary hospital of eastern India. J Can Res Ther., 2011; 7: 433–7.
6. Berek JS, Thomas GM, Ozols RF. Ovarian Cancer. Practical gynecologic oncology, 3rd ed. Baltimore, MD: Lippincott Williams & Wilkins; 2000.
7. Schiff M, Becker TM, Smith HO, et al. Ovarian cancer incidence and mortality in American Indian, Hispanic, and non-Hispanic white women in New Mexico. Cancer Epidemiology, Biomarkers & Prevention, 1996; 5(5): 323-7.
8. Singh S, Saxena V, Khatri S, et al. Histopathological Evaluation of Ovarian Tumors. Imperial Journal of Interdisciplinary Research, 2016; 2(4): 435-9.
9. Thakkar N, Shah S. Histopathological Study of Ovarian Lesions. International Journal of Science and Research, 2015; 4(10): 1745-9.
10. Bhattacharya MM, Shinde SD, Purrandare VN. A clinicopathological analysis of 270 ovarian tumors. J Postgrad Med., 1980; 26: 103-7.
11. Agrawal P, Kulkarni DG, Cahkrabarti PR, et al. Clinicopathological Spectrum of Ovarian Tumors: A 5-Year Experience in a Tertiary Health Care Center. Journal of Basic and Clinical Reproductive Sciences, 2015; 4(2): 90-96.
12. Couto F, Nadkarni NS, Rebello MJ. Ovarian Tumours in Goa-A clinicopathological study. Journal of Obstetrics and Gynaecology of India, 1993; 43(3): 408- 12.
13. Maheshwari V, Tyagi SP, Saxena K. Surface epithelial tumors of ovary. Indian J Pathol Microbiol., 1994; 37(10): 75 -85.
14. Pilli GS, Suneeta KP, Dhaded AV, Yenni VV. Ovarian tumours: a study of 282 cases. J Indian Med Assoc., 2002; 100(7): 420-4.
15. Gupta. N, Bisht. D. Retrospective and prospective study of ovarian tumors and tumor like lesions. Indian journal of Pathol Microbiol., 2007; 50(30): 525-527.
16. Badge SA, Sulhyan KR, Gosavi AV. Histopathological Study of Ovarian Tumors. Indian Medical Gazette, 2013; 147(9): 345-351.
17. Wills V, et al. A study on clinicohistopathological patterns of

- ovarian tumors. *Int J Reprod Contracept Obstet Gynecol.*, 2016; 5(8): 2666-2671.
18. Mankar DV, Jain GK. Histopathological profile of ovarian tumours: A twelve year institutional experience. *Muller Journal of Medical Sciences and Research*, 2015; 6(2): 107-111.
  19. Puttaveerachary AK, Doddaiah NS, Govindshetty AM, et al. A histopathological study of ovarian lesions. *J. Evolution Med. Dent. Sci.*, 2017; 6(70): 4987-4990.
  20. Kancherla J, Kalahasti R, Sekhar KPAC, Yarlagadda SB, Devi SP. Histomorphological Study of Ovarian Tumors: An Institutional Experience of 2 Years. *Int J Sci Stud.*, 2017; 5(3): 232-235.
  21. Bhagyalakshmi A, Sreelekha A, Sridevi S, Chandralekha J, Parvathi G, Venkatalakshmi K. Prospective study of histomorphological patterns of ovarian tumors in a tertiary care centre. *Int J Res Med Sci.*, 2014; 2: 448-56.
  22. Ahmad Z, Kayani N, Hasan SH, Muzaffar S, Gill MS. Histological pattern of ovarian neoplasm. *J Pak Med Assoc.*, 2000; 50: 416-9.
  23. Tejeswini V. Study of morphological patterns of ovarian neoplasms. *J Dent Med Sci.*, 2013; 10: 11-6.
  24. Scully RE, Young RH, Clement PB. *Atlas of Tumor Pathology; Third series, Fascicle 23.* Washington, DC: Armed Forces Institute of Pathology; 1998.
  25. Malli M, Vyas B, Gupta S, Desai H. A histological study of ovarian tumors in different age groups. *Int J Med Sci Public Health*, 2014; 3: 338-341.
  26. Prabhakar BR, Maingi K. Ovarian tumours-prevalence in Punjab. *Indian J Pathol Microbiol.*, 1989; 32: 276-81.
  27. Prakash A, Chinthakindi S, Duraiswami R, Indira.V. Histopathological study of ovarian lesions in a tertiary care center in Hyderabad, India-a retrospective five-year study. *Int J Adv Med.*, 2017; 4: 745-9.
  28. Misra RK, Sharma SP, Gupta U, Gaur R, Misra SD. Pattern of ovarian neoplasm in eastern U.P. *Journal of obstetrics and Gynaecology*, 1990; 41(2): 242-246.
  29. Jha R, Karki S. Histological pattern of ovarian tumors and their age distribution. *Nepal Med Coll J.*, 2008; 10: 81-5.