


Original Research Article

Study to compare CT and MRI evaluation in cerebral venous thrombosis

P. Madhu¹, M. Santhosh Kumar^{2*}

^{1,2}Assistant Professor, Department of Radiodiagnosis, Government Medical College, Nizamabad, Telangana, India

*Corresponding author email: drmadhu.mdrd@gmail.com

	International Archives of Integrated Medicine, Vol. 5, Issue 4, April, 2018. Copy right © 2018, IAIM, All Rights Reserved. Available online at http://iaimjournal.com/	
	ISSN: 2394-0026 (P)	ISSN: 2394-0034 (O)
	Received on: 11-03-2018	Accepted on: 17-03-2018
	Source of support: Nil	Conflict of interest: None declared.
How to cite this article: P. Madhu, M. Santhosh Kumar. Study to compare CT and MRI evaluation in cerebral venous thrombosis. IAIM, 2018; 5(4): 59-67.		

Abstract

Introduction: Cerebral venous thrombosis possible causal factors and clinical manifestations are many and varied; imaging plays a primary role in the diagnosis.

Aim: The purpose of study was to compare CT and MRI findings, in evaluation of parenchymal abnormalities, recanalization.

Materials and methods: It was prospective study done in 42 patients all patients with clinical suspicion of CVT, intracranial vascular malformation, and/or with intracranial hemorrhage of unclear etiology undergone a standardized MR imaging protocol, including the study protocol sequences.

Results: Cerebral venous thrombosis was more common in the females; 24(57.2%) out 42 members. 20(47.6%) members had cerebral venous thrombosis. Staging chart showed majority of cases come to hospital at subacute stage; 33 (78.5%) cases. A total of 32 cases out of 42 underwent both CT and MRI. Cerebral venous thrombosis detected by MRI was 100 % in our study and diagnosed 32 out of 32 cases but CT failed to pick up the lesions in six cases. 11 Sites of thrombosis identified in these patients, Superior sagittal sinus thrombosis was most commonly involved in 78.5% cases (33 out 42). Thrombosis identified with clot on T1WI as hyper intense on 78% cases (33 out 42), Iso intense in 11% (5 out 42) and No signal intensity in 9% (4) cases. On T2 WI, hyper intense in (59%) 25 case out 42 cases, iso intensity in (19%) 8 cases, no signal intensity in 9 cases (21%). On FLAIR, clot appears on hyper signal intensity in 28 % (12 case out 42), iso intensity in 26 % (11 case in 42), no signal intensity in (45%) 19 cases. On DWI clot appears on hyper signal intensity in 26% (11) cases, is intensity in 21% (9) cases, no signal intensity in 52% (22) cases. With follow up 9 cases with complete recanalization, 2 cases with partial recanalization, no change in only one case.

Conclusion: MR imaging should be used as routine imaging modality for cerebral venous thrombosis.

Key words

Cerebral venous thrombosis, Magnetic resonance imaging, Computed tomography.

Introduction

Cerebral venous thrombosis is a relatively uncommon but serious neurologic disorder that is potentially reversible with prompt diagnosis and appropriate medical care. Because the possible causal factors and clinical manifestations of this disorder are many and varied, imaging plays a primary role in the diagnosis. Magnetic resonance imaging, un-enhanced computed tomography, unenhanced time-of-flight MR venography, and contrast material enhanced MR venography and CT venography are particularly useful techniques for detecting cerebral venous and brain parenchymal changes that may be related to thrombosis. To achieve an accurate diagnosis, it is important to have a detailed knowledge of the normal venous anatomy and variants, the spectrum of findings (venous sinus thrombi and recanalization, parenchymal diffusion or perfusion changes or hemorrhage), other potentially relevant conditions (deep venous occlusion, isolated cortical venous thrombosis, idiopathic intracranial hypertension), and potential pitfalls in image interpretation.

Thrombosis of the cerebral veins and sinuses is a distinct cerebrovascular disorder that, unlike arterial stroke, most often affects young adults and children. The symptoms and clinical course are highly variable. A teenager who has had recent headaches after starting oral contraception, a woman who has had seizures after delivery in the obstetrical ward, and a comatose man with a dilated pupil in the emergency room all may have sinus thrombosis. The estimated annual incidence is 3 to 4 cases per 1 million populations and up to 7 cases per 1 million among children. About 75 percent of the adult patients are women. During the past decade, increased awareness of the diagnosis, improved neuroimaging techniques, and more effective treatment have improved the prognosis. More than 80 percent of all patients now have a good neurologic outcome.

This review summarizes recent insights into the pathogenesis of sinus thrombosis, risk factors, and clinical and radiologic diagnosis and discusses the current evidence and controversies about the best treatment. This clinical entity was first described in the early 1800's by the French physician Ribes at the autopsy of a patient with a history of delirium and seizures. In this case, the sagittal sinus was involved [1]. In more recent studies (ISCVT study), the superior sagittal sinus (SSS) is most commonly involved (62%), transverse sinus (TS) (42%), the straight sinus (SS) (18%) and the cavernous sinus (CS) (1.3%). Both the SSS and TS are involved in 30% of cases. Approximately 0.5% of all strokes are complicated by concomitant cerebral venous sinus thrombosis [2]. Recently, several studies have emphasized the value of MRI in evaluation of cerebral venous thrombosis. The purpose of study is to compare CT and MRI findings, in evaluation of parenchymal abnormalities, recanalisation.

Materials and methods

It was prospective study done at Osmania General Hospital, tertiary care center in all patients with clinical suspicion of CVT, intracranial vascular malformation, and/or with intracranial hemorrhage of unclear etiology undergone a standardized MR imaging protocol, including the study protocol sequences. The numbers of patients proposed to be included in the study are forty two.

CT Images of the brain were obtained on a Toshiba, Asteion TSX-021A Spiral CT Unit. Matrix size of 512x512 and slice section of 5 mm. MR examinations were performed on a 1.5T MR scanner (GE Health care). Patients underwent the following sequences in the stated order: T2W images, T1W images, DW images, GRE images, 2D TOF MRV, followed by a single intravenous dose (0.1 mmol/kg) of gadolinium administered with a power injector at

a rate of 3 mL/s, simultaneous with the start of the acquisition of the dynamic 3D MRV sequence.

Images of all patients were reviewed independently by 2 experienced radiologists blinded to the patients' names and clinical or other imaging findings. Each observer viewed MR/MRV modalities per patient separately (T2W images, T1W images, DW images GRE images, TOF MRV). In this manner, image analysis was divided into separate sessions for each MR/MRV technique that grouped the studies in a random patient order.

Six predefined venous segments were evaluated: the superior sagittal sinus, the straight sinus, both lateral sinuses including the region from transverse sinus to the jugular bulb, and right and left cortical venous segments defined as any cortical vein of the right and left hemispheres, respectively.

These segments were classified into 5 categories according to the presence or absence of CVT:

- 1 = Definitely or almost definitely absent,
- 2 = Probably absent,
- 3 = Uncertain,
- 4 = Probably present,
- 5 = Definitely or almost definitely present.

All sequences including static MRV source images were analyzed on a 3D workstation allowing for multi planar reformations and targeted MIPs. For the dynamic MRV part, automatically generated sagittal and coronal whole-brain MIP images were analyzed first. Second, if the patency of a vein was unclear, the observers had the additional opportunity to assess any individual venous phase in freewheeling 3D mode.

The diagnostic criteria for CVT were as: On T2W images, isointense or hyper intense signal intensity inside a cerebral vein lacking a normal flow signal intensity void; On GRE images, a typical magnetic susceptibility effect was only regarded as a positive sign if the lumen of an

affected venous segment was encompassed by a strong hypointense signal intensity that was enlarged compared with adjacent normal veins [2]. On TOF MRV images, a lack of normal venous flow signal intensity was considered positive.

To rule out the possibility of an anaplastic or hypoplastic sinus, source images were analyzed. On the static part of combo-4D MRV, an intraluminal hypointense or isointense filling defect was considered positive. Along with these images, the dynamic part was assessed to exclude the possibility of enhancing chronic thrombosis imitating a patent vein. Here, the following discrepant findings between dynamic and static MRV were considered indicative of chronic CVT: a chronic venous thrombosed segment shows lacking or irregular contrast enhancement at predominantly early venous phases of dynamic MRV, either with or without further increase of the enhancement at later venous phases, but it reveals a normal appearing contrast enhancement on static VIBE MRV images.

Results

Total 42 subjects with cerebral venous thrombosis are studied. Sex distribution showed cerebral venous thrombosis was more common in the female population in our study, 24(57.2%) members of female population out of 42 members. Average incidence of cerebral venous thrombosis in this study was between 20-30 years, 20(47.6%) members had cerebral venous thrombosis out of 42 was between 21-30 years. Majority of cases came to hospital at subacute stage. This study revealed 33 (78.5%) cases in subacute stage out of 42, five cases are in acute stage and only Four cases (9.5%) were in chronic stage (**Table – 1**).

A total of 32 cases out of 42 underwent both CT and MRI. Cerebral venous thrombosis detected by MRI was 100% in our study and diagnosed 32 out of 32 cases but CT failed to pick up the lesions in six cases (**Figure – 1**).

Table - 1: Demographic details in study subjects.

Variable	Total no of patients	%
Gender		
Male	18	42.8
Female	24	57.2
Total	42	100
Age (Years)		
<10	1	2.3
11-20	8	19
21-30	20	47.6
31-40	5	12
41-50	5	12
>51	3	7.1
Staging		
Acute	5	12
Subacute	33	78.5
Chronic	4	9.5

Figure - 1: Detection rate.

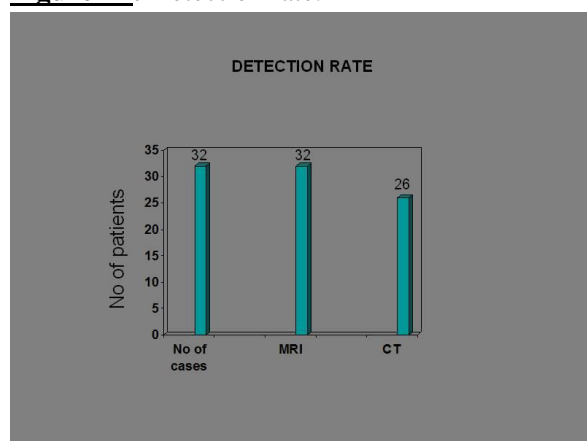


Table - 2: Site of thrombosis.

Site	Total no of patients	%
Superior sagittal sinus	33	78.5
Transverse	20	47.6
Straight	8	19
Cavernous	2	4.7
Vein of Galen	1	2.3
SSS+TS	14	33.3

11 Sites of thrombosis identified in these patients, Superior sagittal sinus thrombosis was most commonly involved in 78.5% cases (33 out 42), Transverse sinus involved in 47.6% (20cases), Straight sinus 19% (8 cases),

cavernous sinus 4.7% (2 cases), Vein of galen in 2.3%(one case) and both SSS +TS are involved in 33% (14cases) as per **Table - 2**.

MRI performed within 3-7 days of onset of symptoms in majority of cases.11 sites of thrombosis identified in these subjects, with clot appearing on T1WI as hyperintense on 78% cases(33 out 42), Iso intense in 11%(5 out 42) and No signal intensity in 9% (4) cases. On T2 WI, hyperintense in (59%) 25 case out 42 cases, iso intensity in(19%)8 cases, no signal intensity in 9 cases (21%). On FLAIR, clot appears on hyper signal intensity in 28 % (12 cases out 42), iso intensity in 26 % (11 cases in 42), no signal intensity in (45%) 19 cases. On DWI clot appears on hyper signal intensity in 26 % (11) cases, iso intensity in 21 % (9) cases, no signal intensity in 52%(22) cases (**Figure – 2**).

In this study, out 40 cases (2 cases death),12 cases were followed up after 4-6 months, CT / MRI done for follow up cases, revealed 9 cases with complete recanalization, 2 cases with partial recanalization, no change in only one case (**Figure – 3**). Images of study were as per **Figure – 4**.

Discussion

Forty two patients diagnosed of cerebral venous thrombosis were examined with both CT and MR imaging at our hospital. The ages of the patients ranged from 1year to 70 years (mean 30 years) with peak incidence being in the age group of 21 to 30 years. This data is agreed by most of the previous studies done earlier. Cerebral venous thrombosis is a relatively uncommon but serious neurologic disorder that is potentially reversible with prompt diagnosis and appropriate medical care. Because the possible causal factors and clinical manifestations of this disorder are many and varied, imaging plays a primary role in the diagnosis. MRI, un-enhanced computed tomography, unenhanced time-of-flight MR venography, and contrast material enhanced MR venography are particularly useful techniques for detecting cerebral venous and brain parenchymal

changes. Thrombosis of the cerebral veins and the subsequent disruption of the blood-brain barrier and thrombosis of the cerebral sinuses contribute to intracranial hypertension. Thrombosis of the cerebral veins increases the venous pressure, reduces the capillary perfusion pressure, and increases the cerebral blood volume. Collateral flow pathways are recruited, and the resultant high pressure leads to a disruption in the blood-brain barrier and resultant vasogenic edema. A drop in cerebral perfusion pressure and blood flow additionally leads to the failure of the Na/K ATPase dependent pump, an

important indirect regulator of intracellular water content, and cytotoxic edema follows. All patients with clinical suspicion of CVT, intracranial vascular malformation, and/or with intracranial hemorrhage of unclear etiology undergo a standardized MR imaging protocol, including the study protocol sequences. Patients underwent the following sequences in the stated order: T2W images, T1W images, DW images, GRE images, 2D TOF MRV, followed by a single intravenous dose of gadolinium administered with a power injector at a rate of 3 ml/s.

Figure - 2: Frequency of different MRI aspects of the thrombus.

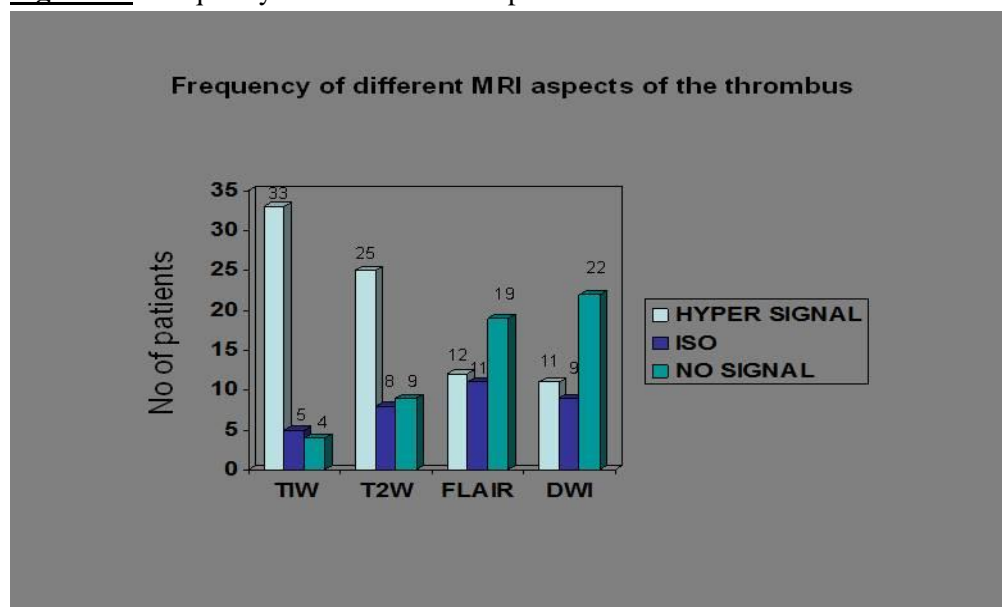


Figure - 3: Recanalization rate in study.

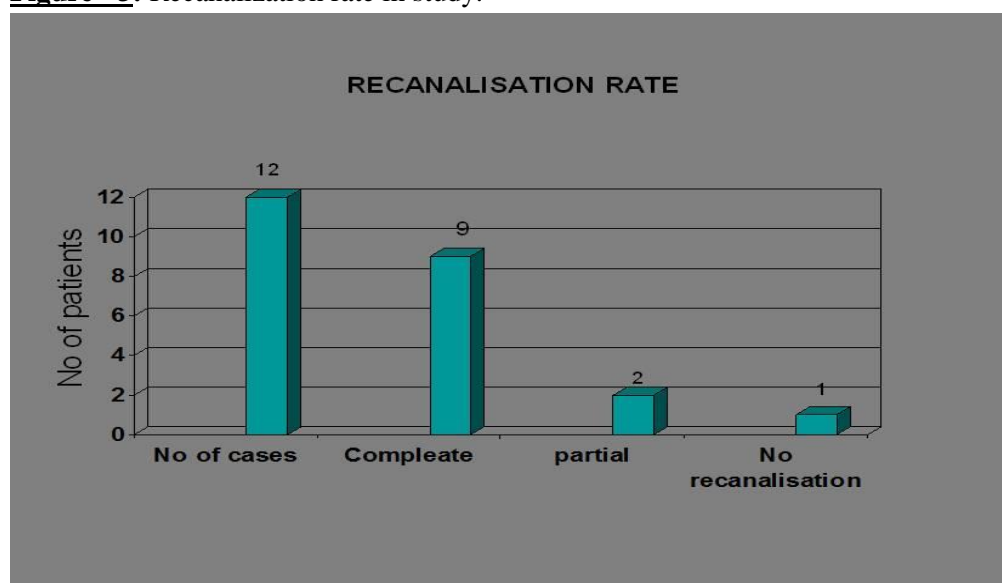
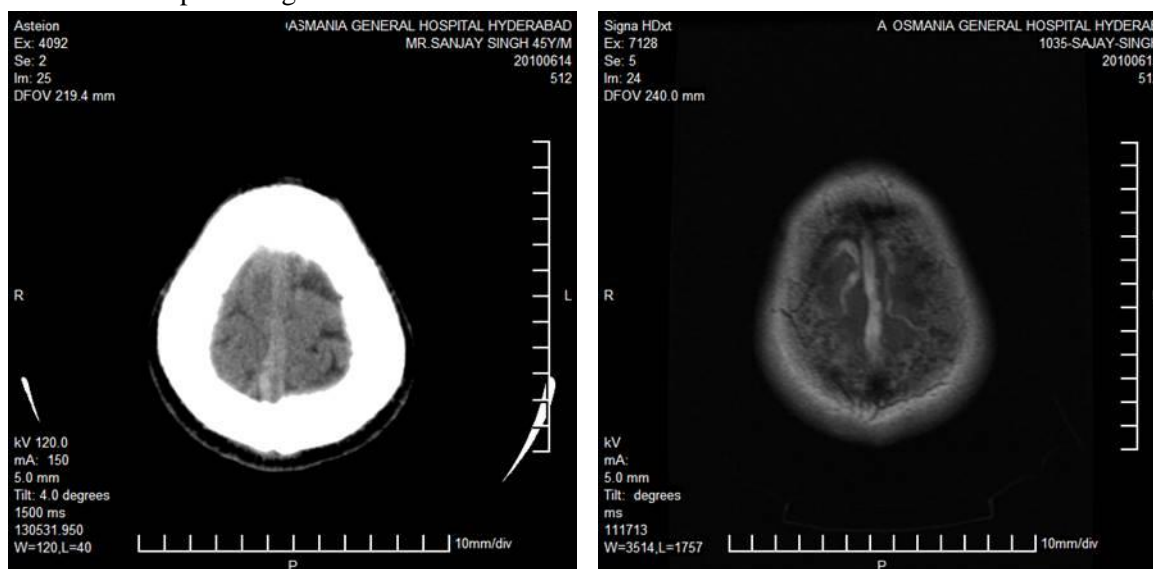


Figure - 4: Images in study.

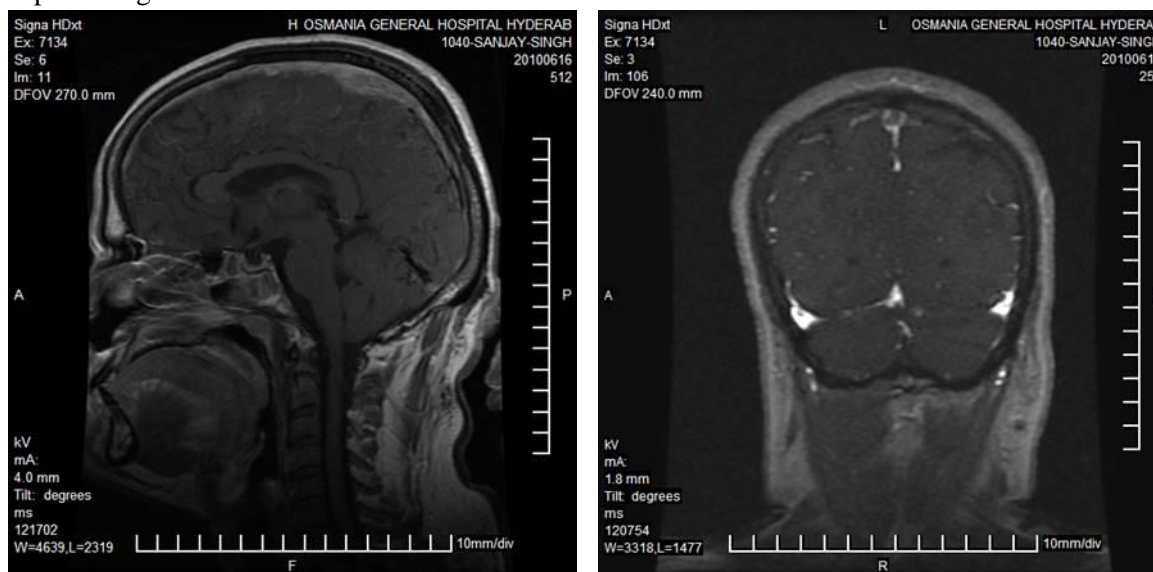
4a) C.T. scan: Hyperdensity noted Superior sagittal sinus – Thrombosis.

4b) MRI Brain Axial Section - Linear altered signal intensity lesion, which is hyperintense on T1WI noted in the superior sagittal sinus and cortical veins.



4c) MRI crosssectional: Altered signal intensity lesion, which is hyperintense on T1WI, hypointense with surrounding hyperintensity noted on T2WI,

4d) Coronal section MRV - On contrast administration filling defect in the superior sagittal sinus – superior sagittal sinus thrombosis.



Images of all patients were reviewed independently by 2 experienced radiologists blinded to the patients' names and clinical or other imaging findings. All sequences including static MRV source images were analyzed on a 3D workstation allowing for multi planar reformations and targeted MIP. In previous studies, Eleven out of 42(25%) CVTs were imaged at the acute stage (range, 1–2days), 21

out of 42 (50%) at the subacute stage (range, 3–11days), and 10 out of 42 (25%) CVTs were imaged at the chronic stage (range, 44 days–7 years). In this study, 5 cases out of 42 are in acute stage, 33 cases are subacute stage, only 4 cases in chronic stage. On T2W images, isointense or hyperintense signal intensity inside a cerebral vein lacking a normal flow signal intensity void is seen; On GRE images, a typical

magnetic susceptibility effect was only regarded as a positive sign, if the lumen of an affected venous segment was encompassed by a strong hypointense signal intensity that was enlarged compared with adjacent normal veins; On TOF MRV images, a lack of normal venous flow signal intensity was considered positive.

Ahmed Idbaih, et al. [3] studied the sensitivity of conventional MRI sequences in cerebral venous thrombosis (CVT), to detect clot in the sinuses or veins is incomplete and largely depends on the time elapsed since thrombus formation. They concluded that sensitivity of T1-weighted spin echo image (T1SE) sequences to detect clot in the sinuses or veins was estimated at 90% between day 1 and day 3, which was much higher than that of T2SE, FLAIR or DWI during there as first week of clinical onset. Thrombosed cortical veins, even in the absence of visible occlusion on magnetic resonance venography, were detected more frequently with T1SE (78%) than with FLAIR or DWI (<40%). In our study reveals clot appears as hyper signal in (78%) 33 cases out of 42 cases on T1W, On T2WI 59% cases (25 out of 42) appear as hyper signal. On flair no signal in 45% cases, On DWI no signal in 52% cases (22 cases out of 42 cases).

John N. Fink, et al. [4] examines the relationship of LST and mastoid air sinus abnormalities systematically. They performed a retrospective clinical and radiological review of a series of 26 patients with cerebral venous thrombosis. Mastoid abnormalities were detected ipsilateral to 9 of 23 thrombosed lateral sinuses (39%) and 0 of 29 unaffected lateral sinuses. They concluded that the mastoid changes observed are likely to be due to venous congestion as a consequence of LST, not mastoiditis. In our study, 3 cases of Mastoid abnormalities were detected ipsilateral to 20 thrombosed lateral sinuses. To rule out the possibility of an anaplastic or hypoplastic sinus, source images were analyzed. Our study has shown that when using 2D-TOF MR venography, flow gaps in non-dominant transverse sinuses can be observed in up to 25% (10 out of 42) of patients with

normal MR imaging findings, and that such flow gaps should therefore be judged with caution when the diagnosis of dural sinus thrombosis is in question. Cavernous sinus thrombosis is usually a late complication of an infection of the central face or paranasal sinuses. Other causes include bacteremia, trauma, and infections of the ear or maxillary teeth.

The most common signs of CST are, sinusitis or a midface infection (most commonly furuncle) for 5-10 days, Headache is the most common presentation symptom and usually precedes fevers, periorbital edema, and cranial nerve signs. Without effective therapy, the patient rapidly develops mental status changes including confusion, drowsiness, and coma from CNS involvement and/or sepsis. Death follows shortly thereafter. Increased venous pressure may cause breakdown of the blood brain barrier and vasogenic edema or may cause reduced cerebral blood flow and cytotoxic edema. Unlike conventional MR images, diffusion weighted (DW) MR images can differentiate between vasogenic and cytotoxic edema. Because DW images have both T2 and diffusion components, vasogenic edema may appear hypointense, isointense, or slightly hyperintense on DW images, but it always produces hyperintensity on ADC images.

The priority of treatment in the acute phase is to stabilize the patient's condition and to prevent or reverse cerebral herniation. This may require the administration of intravenous mannitol, surgical removal of the hemorrhagic infarct, or decompressive hemi craniectomy. The most obvious treatment option is anticoagulation with heparin to arrest the thrombotic process and to prevent pulmonary embolism, which may complicate sinus thrombosis. In patients who have symptoms of chronic intracranial hypertension only, the first priority is to rule out a space-occupying lesion. If there are no contraindications, a lumbar puncture is then performed to measure the cerebrospinal fluid pressure. Then start of treatment with Oral acetazolamide, for lower the

intracranial pressure, to relieve headache, and to reduce papilloedema.

Except for spontaneous abortions, other complications rarely occurred during or after new pregnancies. These findings strongly support the evidence that past CVT (including puerperal CVT) is not a contraindication to pregnancy. R W Baumgartner, et al. [5] in their study 33 consecutive patients presenting with cerebral venous thrombosis. Cerebral MRI and MRV were done at four months and repeated after 12 months if venous thrombosis persisted. 27 patients (82%) had no residual deficits. After four months, all deep cerebral veins and cavernous sinuses, 94% of superior sagittal sinuses, 80% of straight sinuses, 73% of jugular veins, 58% of transverse sinuses, and 41% of sigmoid sinuses had recanalised. In our study reveals 9 cases complete recanalisation out of 12 cases, In two cases are partially recanalised, no change in one case.

Cross sectional TOF MRV was chosen for evaluation of cerebral venous recanalisation. This represents the standard imaging technique for cerebral venous thrombosis. Recanalisation only occurs within the first four months following cerebral venous thrombosis and not thereafter, irrespective of oral anticoagulation. Recanalisation of cerebral venous thrombosis in patients treated with warfarin is accomplished within the first four months. Late recanalisation was not observed in this study, irrespective of the use of oral anticoagulants.

Recently several studies have emphasized the value of MR imaging as the diagnostic modality in the cerebral venous thrombosis [6-8]. One of the advantages of MR imaging is in its ability to pick up the lesions even in any stage. The greater impact of MR imaging is in the evaluation of cerebral venous thrombosis, which has been one of most significant limitation of CT. In our study the accuracy of venous thrombosis by CT was much less compared to MR imaging. Hence it is possible to infer from this prospective study that MRI is superior to CT in the evaluation of

cerebral venous thrombosis. Overall, on comparison, the accuracy rates of CT and MR imaging for parenchymal abnormality, MRI is superior to CT in our study. To rule out the possibility of an anaplastic or hypoplastic sinus, source images were analyzed, Our study has shown that when using 2D-TOF MR venography, flow gaps in non-dominant transverse sinuses can be observed in up to 25% (10 out of 42) of patients with normal MR imaging findings, and that such flow gaps should therefore be judged with caution when the diagnosis of dural sinus thrombosis is in question.

Conclusion

The ages of the patients ranged from 1 year to 70 years (mean 30 years) with peak incidence being in the age group of 21 to 30 years. This data is agreed by most of the previous studies done earlier. Cerebral venous thrombosis is a relatively uncommon but serious neurologic disorder, imaging plays a primary role in the diagnosis of CVT. MRI, un-enhanced computed tomography, unenhanced time-of-flight MR venography, and contrast material enhanced MR venography are particularly useful techniques for detecting cerebral venous and brain parenchymal changes. CT has been used with several limitations, one of the most frequent and significant errors that arise with use of CT is false positive diagnosis of cerebral venous thrombosis.

MR imaging has several advantages over CT such as, Diffusion weighted (DW) MR images can differentiate between vasogenic and cytotoxic edema. Because DW images have both T2 and diffusion components, vasogenic edema may appear hypointense, isointense, or slightly hyperintense on DW images, but it always produces hyperintensity on ADC images. Cross sectional TOF MRV was chosen for evaluation of cerebral venous recanalisation. This represents the standard imaging technique for cerebral venous thrombosis. recanalisation only occurs within the first four months following cerebral

venous thrombosis and not thereafter, irrespective of oral anticoagulation. Our study shows that advantages of MR imaging over computed tomography for detecting the cerebral venous thrombosis. At this point we conclude that MR imaging should be used as routine imaging modality for cerebral venous thrombosis.

References

1. Ribes MF. Des recherches faites sur la phlébite. *Rev Med Franc Etrang.*, 1825; 3: 5-41.
2. Each JL, Strub WM, Gaskill-Shipley MF. Cerebral venous thrombus signal intensity and susceptibility effects on gradient recalled-echo MR imaging. *AJNR Am J Neuroradiol.*, 2007; 28: 940-45.
3. Ahmed Idbaih, Monique Boukobza, et al. MRI of Clot in Cerebral Venous Thrombosis: High Diagnostic Value of Susceptibility-Weighted Images *Stroke*, 2006; 37: 991-995.
4. John N. Fink, David L. McAuley, et al. Mastoid Air Sinus Abnormalities Associated With Lateral Venous Sinus Thrombosis: Cause or Consequence? *Stroke*, 2002; 33: 290-292.
5. R W Baumgartner, A Studer, M Arnold, et al. Recanalisation of cerebral venous thrombosis. *J Neurol Neurosurg Psychiatry*, 2003; 74: 459-461.
6. Karina J. Kersbergen, Linda S., et al. Anticoagulation Therapy and Imaging in Neonates With a Unilateral Thalamic Hemorrhage Due to Cerebral Sinovenous Thrombosis. *Stroke*, 2009; 40: 2754-2760.
7. Patrícia Canhão, et al. Causes and Predictors of Death in Cerebral Venous Thrombosis. *Stroke*, 2005; 36: 1720-1725.
8. José M. Ferro, Patrícia Canhão, et al. Prognosis of Cerebral Vein and Dural Sinus Thrombosis: Results of the International Study on Cerebral Vein and Dural Sinus Thrombosis (ISCVT). *Stroke*, 2004; 35: 664-670.