

Case Report


Hailey – Hailey Disease: Case Report of a rare disease

R. L. Sharma¹, Rekha Sharma^{2*}

¹Associate Professor and Head, Department of Dermatology, Sikkim Manipal Institute of Medical Sciences, Affiliated to Sikkim Manipal University, P.O. Tadong East Sikkim, India

²Junior Resident, Department of Dermatology, Sikkim Manipal Institute of Medical Sciences, Affiliated to Sikkim Manipal University, P. O. Tadong East Sikkim, India

*Corresponding author email: dj_rekha@yahoo.co.in

	International Archives of Integrated Medicine, Vol. 5, Issue 7, July, 2018. Copy right © 2018, IAIM, All Rights Reserved. Available online at http://iaimjournal.com/ ISSN: 2394-0026 (P) ISSN: 2394-0034 (O)	
	Received on: 12-06-2018 Source of support: Nil	Accepted on: 20-06-2018 Conflict of interest: None declared.
How to cite this article: R. L. Sharma, Rekha Sharma. Hailey – Hailey Disease: Case Report of a rare disease. IAIM, 2018; 5(7): 94-98.		

Abstract

Hailey–Hailey disease also known as Familial benign chronic pemphigus is a relatively uncommon disease characterized by painful erosions, vesicles, pustules and scaly erythematous plaques on the neck, axillae, groins and perineum. A case of 27 years old male with history of recurrent, itchy, erythematous, papules and vesicles over the groins presented to the dermatology OPD. A clinical diagnosis of Hailey – Hailey disease was made which was confirmed later by histopathological examination. He was treated with tacrolimus ointment and showed a remarkable improvement.

Key words

Hailey – Hailey, Autosomal dominant, Sikkim, Dilapidated brick wall.

Introduction

Familial benign chronic pemphigus (Hailey–Hailey disease) is a blistering dermatosis, which is inherited as an autosomal dominant trait and usually presents itself around the third or fourth decades. The first onset of HHD generally occurs between 20 and 40 years of age [1]. Painful erosions, vesicles, pustules and scaly erythematous plaques appear on the sites of friction such as the neck, axillae, groins and

perineum [2]. Hailey- Hailey disease is characterized by mutations in the gene that encodes for the golgi-associated Ca²⁺ ATPase (ATP 2C1) leading to abnormal intracellular Ca²⁺ signalling, resulting in acantholysis in stratum spinosum [3]. The condition is clinically characterized by the presence of flaccid vesiculopustules, crusted erosions or expanding circinate plaques. Various treatment modalities have been tried for this clinically resistant

condition but the result with these treatments is not long lasting.

What was known: Hailey – Hailey disease is an autosomal dominant genodermatosis. It is relatively an uncommon disease in India.

Case report

A 27 years old male patient with seven years history of recurrent, itchy, erythematous, papules and vesicles with sometimes burning sensations mainly over the groins presented to the dermatology OPD. The patient had been treated in the past with both topical and systemic antifungal agents as well as antibiotics and he got temporarily relieved of his symptoms but it appeared time and again. The patient's father and other 4 relatives in three consequent generations were affected by the clinically similar problem. There was no seasonal influence. Physical examination showed multiple erythematous, macerated plaques with fissures, peripheral vesicles and crusts were found over hyperpigmented base in the genital area, inguinal folds and the inner aspect of upper thigh in both the sides. There were also multiple post inflammatory hyperpigmented macules of previous lesions. **Figure - 1** shows the lesion of the patient and **Figure - 2** shows the lesion of patient's father. Neck, axillary folds, antecubital fossae, palms and soles, nails, mucous membranes etc., were not involved. All the routine hematological and biochemical investigations were normal. KOH smear for dermatophytes and candida was negative. A 4 mm punch biopsy specimen was taken from the affected site in the groin. It demonstrated suprabasilar clefting with acantholytic cells lining and within the clefts. Widespread partial acantholysis at different levels of the epidermis giving rise to the 'dilapidated brick wall' appearance. **Figure - 3** shows the histopathological finding. With all these clinicopathological findings, a diagnosis of Hailey- Hailey disease was confirmed in this patient. He was treated with tacrolimus ointment and showed a remarkable improvement.

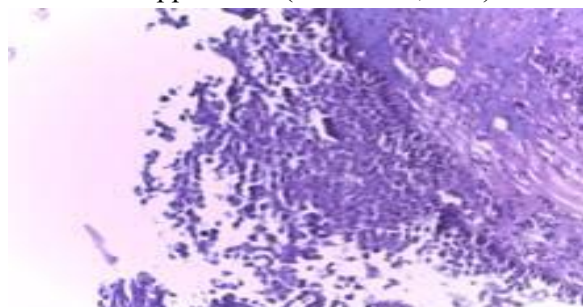
Figure - 1: Erythematous macerated plaques with fissures and crusts in the perineum.

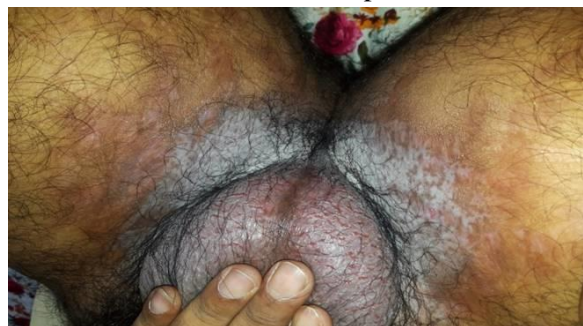

Figure - 2: Post lesional hyperpigmentation in the groin.



Figure - 3: Partial acantholysis at different levels of the epidermis giving rise to the 'dilapidated brick wall' appearance (H&E stain, 40X).



Discussion

Hailey-Hailey disease is a relatively uncommon disease in India and its prevalence is 1:50,000 [4]. It is an autosomal dominant inherited genodermatosis with incomplete penetrance and was first described in 1939 by the Hailey brothers [5]. It is a chronic disabling disease with recurrent remissions and relapses. Family history is obtained in about two-thirds of the patients. It involves abnormal keratinocyte adhesion in supra basal layers of epidermis due to defect in gene ATP2C1 on chromosome 3q 21-24 which

encodes Ca²⁺ ATPase [6]. The Ca²⁺ homeostasis plays a major role in epidermal cell to cell adhesions. The characteristic clinical features are recurrent, fragile, vesicles and erosions in the intertriginous areas especially the axillary folds, groins, submammary folds and neck folds. Skin lesions mostly present between second to fourth decade of life and can be pruritic, painful and malodorous [7]. A positive family history of HHD is present in many patients [8]. Some female patients may experience a premenstrual worsening of their disease, suggesting a role of sex hormones [9]. They leave behind post inflammatory hyperpigmentation without scarring. Sometimes lesions can also appear on scalp, antecubital or popliteal fossa, and trunk. Conjunctiva, mucosa, and vulva involvement is rarely seen. Longitudinal white lines on the fingernails and fine palmer pits are observed. Atypical variants are hyperkeratotic, verrucous, lichenified, papular, papulovesicular and vesiculopustular forms. The disease can be exacerbated by friction, heat, sweating, physical trauma, infection, stress and UV light. It has tendency of remission and exacerbations. Rare consequence of HHD is squamous cell carcinoma [10]. Differential diagnosis includes Intertrigo, Eczema, Darier's disease, Pemphigus vegetans, fungal infection, Psoriasis, extramammary Paget's disease and Acanthosis nigricans. Histopathological examination reveals widespread suprabasal acantholysis with loss of intercellular bridges, which result in 'dilapidated brick wall' appearance. Direct immunofluorescence tests are negative. The diagnosis of HHD is often delayed. In our patients, the time from disease onset to diagnosis was 7 years.

In the management of HHD patients, general measures should not be overlooked. Simple measures should be tried to reduce skin friction and keep flexures dry, including weight loss if appropriate, loose cool clothing, absorbent pads in skin folds and treatment of any possible infections [11]. The treatment of Hailey-Hailey disease is very challenging. Numerous therapies have been tried in the past ranging from topical

and systemic antibiotics, antimycotics, methotrexate, corticosteroids, dapsone, thalidomide, cyclosporine, retinoids, botulinum toxin A, resorting to surgical and CO₂ laser therapies in severe and refractory cases but all these therapies have offered only short-term control of disease [12]. It can be successfully treated by excision of the lesional skin followed by split-thickness grafting. The success of surgery is attributed to the removal of adnexal structures and a decrease in sweating and maceration. Surgical excision provided definite relief from an otherwise disabling disease and a satisfactory improvement in life-style [13-15]. Botulinum toxin (axillary or inframammary) may also help by reducing sweating [15-17]. There are very few recent reports of use of topical tacrolimus in Hailey-Hailey disease. Topical tacrolimus was found to be effective in the treatment of HHD [18]. The exact mechanism of action of tacrolimus in Hailey-Hailey disease is not clear however it has been suggested that tacrolimus like cyclosporine targets a calcium-activated phosphatase called calcineurin, thereby blocking the expression of cytokines, leading to recovery of ATP2C1 expression to levels sufficient to maintain homeostasis in the epidermis [19].

So the management of HHD is challenging. At present, there is no reported cure for HHD. The treatment is primarily aimed at symptomatic relief.

Conclusion

We present a case of familial benign chronic pemphigus (Hailey–Hailey disease), which started in the second decade with painful bullous and erosive lesions and scaly erythematous plaques which appeared at the sites of friction. The patient's father and other 4 relatives in three consequent generations were affected by the same disease. In the presented case topical and systemic antibiotics, antimycotics and corticosteroids were applied with a transient result. We have demonstrated a good effect with topical tacrolimus treatment. Topical tacrolimus

can be an effective alternative treatment for Hailey-Hailey disease for long-term control of disease.

Acknowledgement

We like to express our thanks to Dr. Amlan Gupta, Professor and Head, Department of Pathology, SMIMS for the histopathological diagnosis of the disease.

References

1. Zhao QF, Hasegawa T, Komiyama E, Ikeda S. Hailey-Hailey disease: A review of clinical features in 26 cases with special reference to secondary infections and their control. *Dermatologica Sinica*, 2017; 35: 7-11.
2. Yordanova I, Gospodinov D, Chavdarova V, Popovska S. Familial Benign chronic Pemphigus (Hailey-Hailey disease). *Journal of IMAB-Annual proceeding (Scientific papers)*, 2007; 13(1): 60-62.
3. Hassan Iffat, Keen Abid. Hailey Hailey disease: A case report. *Our Dermatol online*, 2012; 3(2): 116-118.
4. Vasudevan B, Verma R, Badwal S, Neema S, Mitra D, Sethumadhavan T. Hailey-Hailey disease with skin lesions at unusual sites and a good response to acitretin. *Indian J Dermatol Venereol Leprol.*, 2015; 81: 88–91.
5. Hailey H, Hailey H. Familial benign chronic pemphigus. *Arch Dermatol.*, 1939; 39: 679-685.
6. Persić-Vojinović S, Milavec-Puretić V, Dobrić I, Rados J, Spoljar S. Disseminated Hailey-Hailey disease treated with topical tacrolimus and oral erythromycin: Case report and review of the literature. *Acta Dermatovenerol Croat.*, 2006; 14: 253–7.
7. Burge SM. Hailey - Hailey disease: the clinical features, response to treatment and prognosis. *Br J Dermatol.*, 1992; 126: 275.
8. James WD, Berger TG, Elston DM. Familial benign chronic pemphigus (Hailey-Hailey Disease) In: James WD, Berger TG, Elston DM, editors. *Andrews' Diseases of the Skin: Clinical Dermatology*. 10th ed. Toronto: Elsevier Inc; 2006, p. 559–60.
9. Szigeti R, Chao SC, Szász O, Tészás A, Kosztolányi G, Kellermayer R. Premenstrual exacerbation in calcium ATPase disorders of the skin. *J Eur Acad Dermatol Venereol*, 2007; 21: 412.
10. Holst VA, Fair KP, Wilson BB, Patterson JW. Squamous cell carcinoma arising in Hailey- Disorders of epidermal maturation and keratinization. In: Weedon D. *Skin Pathology 2nd edition*, Churchill Livingstone; 2002, p. 298-299.
11. Prateek K, Banwarilal MR, Chaudhary SS, Garg M. Hailey Hailey disease-a rare case report. *Int J Res Dermatol.*, 2016; 2: 36-9.
12. Freiman A, Hakim MD, Billick RC. Hailey-Hailey Disease (Benign Familial Pemphigus): Carbon Dioxide Laser Therapy. *McGill J Med.*, 2002; 6: 100–3.
13. Aubert JP, Folchetti G, Berbis P, Magalon G. Surgical treatment of Hailey- Hailey disease or benign chronic familial pemphigus. Apropos of a case of submammary localization. *Ann Chir Plast Esthet.*, 1993; 38(5): 568-571.
14. Crotty CP, Scheen SR 3rd, Masson JK, Winkelmann RK. Surgical treatment of familial benign chronic pemphigus. *Arch Dermatol.*, 1981; 117(9): 540-542.
15. Lapiere JC, Hirsh A, Gordon KB, Cook B, Montalvo A. Botulinum toxin type A for the treatment of axillary Hailey–Hailey disease. *Dermatol Surg.*, 2000; 26: 371–4.
16. Konrad H, Karamfi lov T, Wollina U. Intracutaneous botulinum toxin A versus ablative therapy of Hailey–Hailey disease - A case report. *J Cosmet Laser Ther.*, 2001; 3: 181–4.
17. Kang NG, Yoon TJ, Kim TH. Botulinum toxin type A as an effective adjuvant

- therapy for Hailey–Hailey disease. *Dermatol Surg.*, 2002; 28: 543.
18. Sand C, Thomsen HK. Topical tacrolimus ointment is an effective therapy for Hailey-Hailey disease. *Arch Dermatol.*, 2003; 139: 1401-2.
19. Mayuzumi N, Ikeda S, Kawada H, Ogawa H. Effects of drugs and anticytokine antibodies on expression of ATP2A2 and ATP2C1 in cultured normal human keratinocytes. *Br J Dermatol.*, 2005; 152: 920–4.