

## Case Report


# Histopathological and radiological findings of desmoid tumor of abdominal cavity

Muthu Saravanan A<sup>1</sup>, I. Gurubharath<sup>2\*</sup>

<sup>1</sup>Second-year Postgraduate Student, <sup>2</sup>Professor and Head

Department of Radio-Diagnosis, Shri Sathya Sai Medical College and Research Institute, Kancheepuram, Tamil Nadu, India

\*Corresponding author email: [kavinilangovan@yahoo.co.in](mailto:kavinilangovan@yahoo.co.in)

	International Archives of Integrated Medicine, Vol. 5, Issue 10, October, 2018.	
	Copy right © 2018, IAIM, All Rights Reserved.	
	Available online at <a href="http://iaimjournal.com/">http://iaimjournal.com/</a>	
	ISSN: 2394-0026 (P)	ISSN: 2394-0034 (O)
	Received on: 22-09-2018	Accepted on: 30-09-2018
	Source of support: Nil	Conflict of interest: None declared.
<b>How to cite this article:</b> Muthu Saravanan A, I. Gurubharath. Histopathological and radiological findings of desmoid tumor of abdominal cavity. IAIM, 2018; 5(10): 147-152.		

## Abstract

Desmoid tumors are rare slow growing, monoclonal, fibroblastic proliferation characterized by variable and often unpredictable clinical outcome, sometimes with aggressive infiltration of adjacent tissue but with no metastatic potential. Desmoids are histologically benign. On a molecular study level, they have been characterized by mutations in the  $\beta$ -catenin gene, APC (Adenomatous Polyposis Coli) gene or the CTNNB1. Gene studies are useful when the pathological diagnosis is difficult. Application of various multidisciplinary assessments along with multimodality treatment forms the basis of management for these patients. In selected asymptomatic patients, watchful waiting might be the most appropriate management. But for patients with desmoid located in other sites like the mesentery or at the head and neck region which might present with serious complications, thus requiring a more aggressive approach of treatment. In this article, we reported a 28-year-old female with a desmoid tumor of the anterior abdominal wall who underwent surgical resection. Preoperative evaluation was done using abdominal ultrasound, computed tomography, and magnetic resonance imaging. The histopathological examination of the resected specimen revealed a desmoid tumor. Because of the heterogeneity of the desmoid tumors, treatment needs to be individualized. However, complete surgical resection with negative margins seems to be the treatment of choice for this tumor entity and postoperative radiotherapy can help reduce the local recurrence rate.

## Key words

Desmoids tumors, Ultrasound, Magnetic resonance imaging (MRI), Computed tomography (CT).

## Introduction

Desmoid tumors are cytologically bland fibrous neoplasms originating from the musculoaponeurotic structures throughout the body. Desmoid tumors are benign neoplasm originating from the muscle aponeurosis and classified as deep fibromatoses [1]. They constitute 3% of all soft tissue tumors and 0.03% of all soft tissue neoplasm [2]. They are locally aggressive but lack any malignant potential [3]. This local infiltration causes compression of surrounding structures. High recurrence rate exists. Desmoid tumors can lead to death in cases with restricted surgical access [4]. Desmoid tumors are considered to be the most common cause of morbidity and mortality in post-colectomy patients with FAP (Familial Adenomatous Polyposis) [5]. Molecular studies have demonstrated desmoids in FAP as clonal neoplasm arising from mutations in or changes in APC alleles [6-8]. Cytogenic data provides additional evidence for the malignant potential of these lesions [9]. Desmoid tumors are commonly noted in the anterior abdominal wall, the proximal extremities, and the mesentery of the intestine (FAP) Grey-Turner's sign refers to bruising of the area between the last rib and top of the hip and is a sign of retroperitoneal hemorrhage. Cullen's sign is superficial edema and bruising in the subcutaneous fatty tissue around the umbilicus. Causes include acute pancreatitis, ruptured ectopic, aortic rupture, and coagulopathies [10]. In sporadic cases, they occur in sites of post-trauma scars or irradiation.

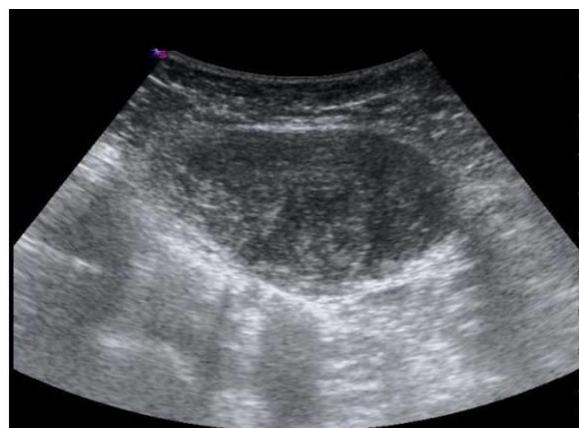## Case report

A 28-year-old female presented with complaints of painless swelling/lump in the anterior abdominal wall. There was no history of any previous abdominal surgeries done. The blood investigations were normal. Further evaluation was done using abdominal ultrasound, computed tomography, and magnetic resonance imaging. The histopathology of the resected lesion revealed a desmoid tumor. Written consent was obtained from parents or guardians before analysis Study period was between 2017-2018 in

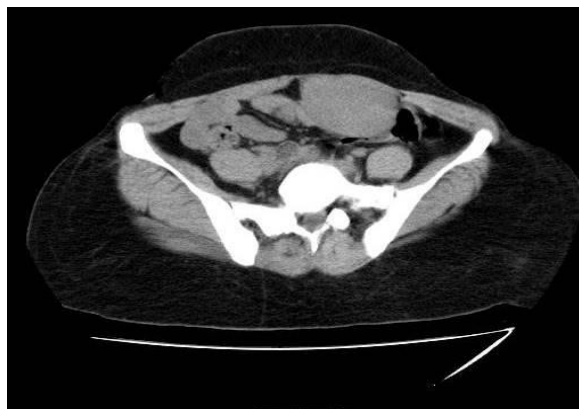the department of radiology and imaging sciences, Shri Sathya Sai Medical College and Research Institute.

USG, CT and MRI findings were as per **Photo – 1 to 3**. On microscopic examination of the resected specimen, section studied shows a tumor mass composed of long, fascicles of spindle cells with ovoid or tapering nuclei, vesicular chromatin, small nucleoli, and indistinct cytoplasm. The tumor cells were admixed with abundant collagen and hyalinization. Few foci show tumor cells infiltrating the adjacent striated muscle and entrapping atrophic muscle fibers. Numerous dilated blood vessels were seen (**Photo – 4**). All these features are consistent with desmoids a tumor.

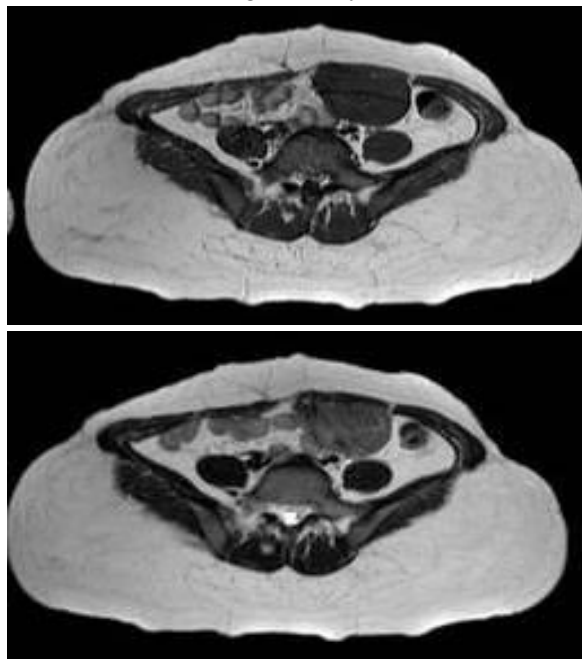
**Photo – 1:** USG B-mode image showing a well-defined homogeneously hypoechoic masses in the left rectus abdominis muscle.



**Photo – 2:** CT abdomen axial image showing a well-circumscribed homogenous mass of soft tissue density, seen arising from the left rectus abdominis muscle.



**Photo – 3:** MRI shows a well-defined lobulated soft tissue lesion measuring 11.4X5.4X3cm noted in the left anterior abdominal wall involving the left rectus abdominis muscle. Superiorly, the lesion extends to the level of supraumbilical region and inferiorly up to the level of bladder. The lesion appears hypointense on T1WI and heterogeneously intense on T2WI.



## Results

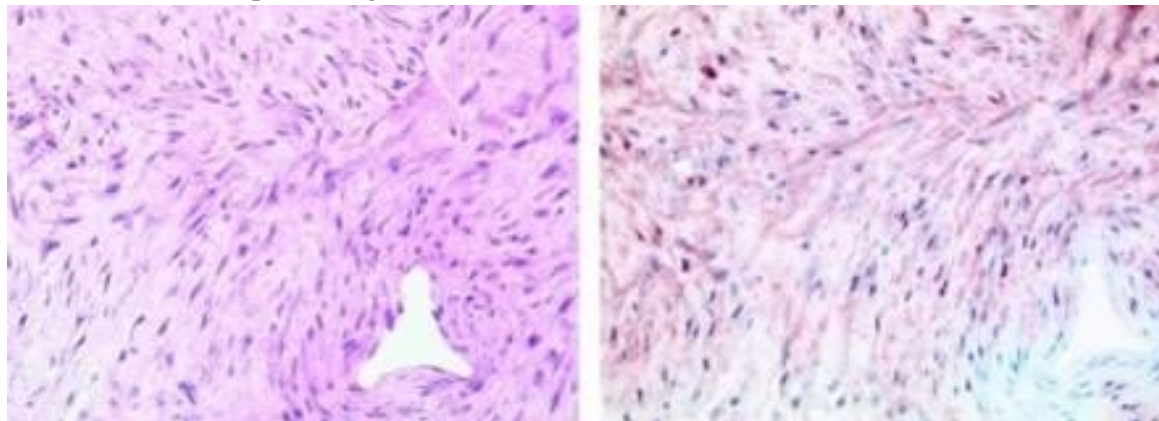
Desmoid tumors are benign fibromatoses, originating from muscle aponeurosis and fascia with an infiltrating growth [11]. They are located primarily either abdominally or intraabdominal [1], meanwhile sporadic cases describe a localization within the chest wall [12] or retroperitoneum [13]. The desmoid tumor is often associated with Familial Adenomatous Polyposis (FAP) [14], female sex and sometimes with surgical trauma [15]. It has a high prevalence in pregnant women [16]. Recurrences occur in up to 45% of cases depending upon the size of tumors, mode of treatment and on the negative resection margins [17]. CT scan isolates the tumor and excludes any metastasis. MRI shows tumor hypointensity on T1WI and variable signal intensity on T2WI, depending on the collection of mucoid structures. Therefore, a differentiation from the rest of the solid tumors is not possible using morphological criteria [18].

Histology is the method which shows spindle cells arranged in long fascicles of variable cell-density with a few mitoses. Also, there is the absence of atypical nucleus-separations. Diffuse cell infiltrations of adjacent structures are noted. Immunohistochemical muscle cell markers like actin can help in differentiating desmoid tumors from fibrosarcoma [19, 20]. Therapeutic options are [21], hormone-therapy [22], anti-inflammatory treatment and chemotherapy [23] are ineffective and are done for patients for whom surgery cannot be done. The indication and effectiveness of adjuvant radiation are not yet proven. In an analytical study, significantly better local recurrence control was achieved with radiation and surgical resection in contrast to resection only. However, higher complication is associated with radiation therapy [24]. Other studies show a progress in the tumor even after radiation therapy [25] and a high local recurrence rate [26]. Due to the chromosomal aberrations and germline mutations of the APC alleles Bright-Thomas et al. did a pre-clinical study for desmoid treatment in FAP with gene transfer [27]. After the success of transgene expression, more work is needed to effects clinically on gene therapy and work on animal models. The most effective treatment of smaller desmoid tumors is the resection with negative margins, although it may not prevent local recurrence. However, in FAP patients, massive mesenteric lesions occur in post-colectomy patients. Nonsurgical treatment in these patients has a varied and unpredictable outcome [10, 21, 28, 29]. Middleton, et al. gave a report on successful short-term surgery in four cases of intra-abdominal tumors where treatment was inefficient without the surgery [28]. In conclusion, we need many therapeutic choices to treat abdominal tumors. Surgery will always aim at radical tumor resection with free margins, which, depends on the localization of surgery and may leave major soft tissue defect behind [28, 30, 31]. In spite of the fact, abdominal wall full-thickness surgery can be re-establish with direct sutures [4, 32]. Reconstruction with synthetic materials can be used in major abdominal wall defects [33]. Albeit, et al., conducted a study on the reconstruction of the

abdominal wall with a Bard Composix-Mesh in patients with post small tumor resection with tumor-free margins. Recent literature data recommends, muscle flaps for abdominal wall

defect coverage [30, 32], moreover, the prosthetic material is likely susceptible to the bacterial infection and other complications [34, 35].

**Photo – 4:** Microscopic findings.



**Conclusion**

Thus, the treatment of desmoid tumors is difficult to understand. Non-surgical treatment resulted in various unpredictable outcomes. It is a treatment option reserved for patients with unresectable lesions or as an adjuvant therapy. Radical resection with clear margins is the mainstay treatment with a good prognosis but with minimal risk of local recurrence. The response can take months and continue for years.

**Acknowledgments**

The authors would like to thank the Professors, Assistant Professors, and radiological imaging technique staffs of Shri Sathya Sai Medical College and Research Institute, for helping them a major role in research work.

**References**

1. Biermann JS. Desmoid tumors. *Curr Treat Options Oncol.*, 2000; 1: 262–266.
2. Micke O, Seegenschmiedt MH. German Cooperative Group on Radiotherapy for Benign Diseases. Radiation therapy for aggressive fibromatosis (desmoid tumors): Results of a national Patterns of

- Care Study. *Int J Radiat Oncol Biol Phys.*, 2005; 61: 882–891.
3. Bertario L, Russo A, Sala P, et al. Hereditary Colorectal Tumor Registry. Multiple approaches to the exploration of genotype-phenotype correlations in familial adenomatous polyposis. *J Clin Oncol.*, 2003; 21: 1698–1707.
4. Clark SK, Phillips RK. Desmoids in familial adenomatous polyposis. *Br J Surg.*, 1996; 83: 1494–1504.
5. Janinis J, Patriki M, Vini L, et al. The pharmacological treatment of aggressive fibromatosis: A systematic review. *Ann Oncol.*, 2003; 14: 181–190.
6. Pignatti G, Barbanti-Bròdano G, Ferrari D, et al. Extraabdominal desmoid tumor. A study of 83 cases. *Clin Orthop Relat Res.*, 2000; 375: 207–213.
7. Knudsen AL, Bülow S. Desmoid tumor in familial adenomatous polyposis. A review of the literature. *Fam Cancer*, 2001; 1: 111–119.
8. Casali PG, Blay JY. ESMO/CONTICANET/EUROBONET Consensus Panel of Experts. Soft tissue sarcomas: ESMO clinical practice guidelines for diagnosis, treatment, and follow-up. *Ann Oncol.*, 2010; 21(suppl 5): v198–v203.



9. Okuno S. The enigma of desmoid tumors. *Curr Treat Options Oncol.*, 2006; 7: 438–443.
10. Stoeckle E, Coindre JM, Longy M, et al. A critical analysis of treatment strategies in desmoid tumors: A review of a series of 106 cases. *Eur J Surg Oncol.*, 2009; 35: 129–134.
11. Carlson JW, Fletcher CD. Immunohistochemistry for beta-catenin in the differential diagnosis of spindle cell lesions: Analysis of a series and review of the literature. *Histopathology*, 2007; 51: 509–514.
12. Wu X, Petrovic V, Torode IP, et al. Low-grade fibromyxoid sarcoma: Problems in the diagnosis and management of a malignant tumor with bland histological appearance. *Pathology*, 2009; 41: 155–160.
13. Bartuma H, Möller E, Collin A, et al. Fusion of the FUS and CREB3L2 genes in a supernumerary ring chromosome in low-grade fibromyxoid sarcoma. *Cancer Genet Cytogenet.*, 2010; 199: 143–146.
14. Wehrli BM, Weiss SW, Yandow S, et al. Gardner-associated fibromas (GAF) in young patients: A distinct fibrous lesion that identifies unsuspected Gardner syndrome and risk for fibromatosis. *Am J Surg Pathol.*, 2001; 25: 645–651.
15. Dumont AG, Rink L, Miettinen M, et al. Coexistence of gastrointestinal stromal tumor (GIST) with desmoids tumor (DT): Case series of 22 patients [abstract 10052] *J Clin Oncol.*, 2010; 28(15 suppl): 711s.
16. Coffin CM, Hornick JL, Fletcher CD. Inflammatory myofibroblastic tumor: Comparison of clinicopathologic, histologic, and immunohistochemical features including ALK expression in atypical and aggressive cases. *Am J Surg Pathol.*, 2007; 31: 509–520.
17. Swartz RD. Idiopathic retroperitoneal fibrosis: A review of the pathogenesis and approaches to treatment. *Am J Kidney Dis.*, 2009; 54: 546–553.
18. Lazar AJ, Tuvin D, Hajibashi S, et al. Specific mutations in the beta-catenin gene (CTNNB1) correlate with local recurrence in sporadic desmoid tumors. *Am J Pathol.*, 2008; 173: 1518–1527.
19. Dômont J, Salas S, Lacroix L, et al. High frequency of beta-catenin heterozygous mutations in extra-abdominal fibromatosis: A potential molecular tool for disease management. *Br J Cancer*, 2010; 102: 1032–1036.
20. Miyaki M, Konishi M, Kikuchi-Yanoshita R, et al. Coexistence of somatic and germ-line mutations of the APC gene in desmoid tumors from patients with familial adenomatous polyposis. *Cancer Res.*, 1993; 53: 5079–5082.
21. Vasen HF, van der Luijt RB, Slors JF, et al. Molecular genetic tests as a guide to surgical management of familial adenomatous polyposis. *Lancet*, 1996; 348: 433–435.
22. Wallis YL, Morton DG, McKeown CM, et al. Molecular analysis of the APC gene in 205 families: Extended genotype-phenotype correlations in FAP and evidence for the role of APC amino acid changes in colorectal cancer predisposition. *J Med Genet.*, 1999; 36: 14–20.
23. Melis M, Zager JS, Sondak VK. Multimodality management of desmoid tumors: How important is a negative surgical margin? *J Surg Oncol.*, 2008; 98: 594–602.
24. Nakayama T, Tsuboyama T, Toguchida J, et al. Natural course of desmoid-type fibromatosis. *J Orthop Sci.*, 2008; 13: 51–55.
25. Lev D, Kotilingam D, Wei C, et al. Optimizing treatment of desmoid tumors. *J Clin Oncol.*, 2007; 25: 1785–1791.
26. Spear MA, Jennings LC, Mankin HJ, et al. Individualizing management of

- aggressive fibromatoses. *Int J Radiat Oncol Biol Phys.*, 1998; 40: 637–645.
27. Merchant NB, Lewis JJ, Woodruff JM, et al. Extremity and trunk desmoid tumors: A multifactorial analysis of outcome. *Cancer*, 1999; 86: 2045–2052.
  28. Gronchi A, Casali PG, Mariani L, et al. Quality of surgery and outcome in extra-abdominal aggressive fibromatosis: A series of patients surgically treated at a single institution. *J Clin Oncol.*, 2003; 21: 1390–1397.
  29. Bonvalot S, Eldweny H, Haddad V, et al. Extra-abdominal primary fibromatosis: Aggressive management could be avoided in a subgroup of patients. *Eur J Surg Oncol.*, 2008; 34: 462–468.
  30. Bertagnolli MM, Morgan JA, Fletcher CD, et al. Multimodality treatment of mesenteric desmoid tumors. *Eur J Cancer*, 2008; 44: 2404–2410.
  31. Baumert BG, Spahr MO, von Hochstetter A, et al. The impact of radiotherapy in the treatment of desmoid tumors. An international survey of 110 patients. A study of the Rare Cancer Network. *Radiat Oncol.*, 2007; 2: 1–12.
  32. Jelinek JA, Stelzer KJ, Conrad E, et al. The efficacy of radiotherapy as postoperative treatment for desmoid tumors. *Int J Radiat Oncol Biol Phys.*, 2001; 50: 121–125.
  33. Nuyttens JJ, Rust PF, Thomas CR, Jr, et al. Surgery versus radiation therapy for patients with aggressive fibromatosis or desmoid tumors: A comparative review of 22 articles. *Cancer*, 2000; 88: 1517–1523.
  34. Guadagnolo BA, Zagars GK, Ballo MT. Long-term outcomes for desmoid tumors treated with radiation therapy. *Int J Radiat Oncol Biol Phys.*, 2008; 71: 441–447.
  35. Deyrup AT, Tretiakova M, Montag AG. Estrogen receptor-beta expression in extraabdominal fibromatosis: An analysis of 40 cases. *Cancer*, 2006; 106: 208–213.