

Original Research Article


# Study of profile of cases and complications of ileal perforation at KMCH, Katihar

Prabhat Ranjan<sup>1\*</sup>, Md. Arif Ansari<sup>2</sup>

<sup>1</sup>Ex-Senior Resident, <sup>2</sup>Professor

Department of Surgery, Katihar Medical College, Katihar, Bihar, India

\*Corresponding author email: [dr.prabhatranjanmch97@gmail.com](mailto:dr.prabhatranjanmch97@gmail.com)

	International Archives of Integrated Medicine, Vol. 6, Issue 2, February, 2019. Copy right © 2019, IAIM, All Rights Reserved. Available online at <a href="http://iaimjournal.com/">http://iaimjournal.com/</a>	
	ISSN: 2394-0026 (P)	ISSN: 2394-0034 (O)
	Received on: 25-01-2019	Accepted on: 05-02-2019
	Source of support: Nil	Conflict of interest: None declared.
<b>How to cite this article:</b> Prabhat Ranjan, Md. Arif Ansari. Study of profile of cases and complications of ileal perforation at KMCH, Katihar. IAIM, 2019; 6(2): 74-78.		

## Abstract

**Background:** Bowel perforation is an important cause of acute abdomen. It carries high morbidity and mortality.

**Materials and methods:** The present descriptive study included 48 patients with ileal perforation admitted at the department of surgery. Data regarding clinical features, management and complications was noted.

**Results:** Mean age of the patients was  $34.4 \pm 8.8$  years with male preponderance. Abdominal pain and distension (100%) and constipation (87.5%) were the common symptoms seen. Single perforation was commoner (64.6%) than multiple perforations. It was caused by typhoid in 39.6% cases, due to tuberculosis in 16.7%, due to injury in 10.4% and other causes in 33.3% cases. Surgical site infection was the commonest complication.

**Conclusion:** Ileal perforation is caused by typhoid or tuberculosis in majority of the cases and presents with pain abdomen and distension. Rates of infection are high in these cases.

## Key words

Complications, Descriptive Study, Ileal Perforation, Profile.

## Introduction

Bowel perforation is one of the common surgical emergencies. It is the fifth most common cause of acute abdomen [1]. Typhoid and tuberculosis are the major causes in this area. Other causes include infective (Histoplasma, E. histolytica,

cytomegalovirus etc.), inflammatory (Wagener's granulomatous) and drug-induced (NSAIDs). The cases in which cause cannot be ascertained are termed as non-specific ones [2]. Various surgeries have been advocated including primary

repair, primary ileostomy, repair with ileostomy etc. [3].

Ileal perforation leads to peritonitis and causes high rates of morbidity and mortality. Poor outcome is associated with late presentation of the disease, lack of diagnostic facilities and inadequate healthcare services [4].

Regular monitoring of factors related to this condition and measurement of outcome is useful in understanding the pathophysiology and better management of the illness. Hence, this study was undertaken.

### **Aim and objectives**

The present study was conducted to assess the clinical and pathological features of Ileal perforations among patients admitted in the Surgery ward of Katihar Medical College, Katihar.

### **Materials and methods**

The present study was descriptive cross-sectional in nature conducted at the Department of Surgery, Katihar Medical College, Katihar. Patients admitted in the department and presenting with clinical features of bowel perforation were critically evaluated and advised for exploratory laparotomy. The patients who had ileal perforation confirmed during surgery were included in the present study. The patients who did not have ileal perforation or who had perforation of some other viscus were excluded. A total of 48 patients were studied.

Detailed history was taken from all the cases and general and systemic examination was done. Laboratory investigations for finding the cause and assessing the condition of the patient included complete blood count, Blood Culture and sensitivity, Widal test, Blood Urea, Serum Creatinine and Electrolytes and Urine routine. Radiological investigations included Chest X-Ray PA view, Abdominal X-Ray in erect posture and USG abdomen.

The patients were actively resuscitated before surgery. General anesthesia was given for emergency exploratory laparotomy. Abdomen was opened by midline incision. The perforation was located, biopsy was taken from the edge of perforation for histopathological examination and the perforation was closed in two layers. This was followed by thorough peritoneal lavage using 2-3 liters of normal saline. In the presence of stricture, either primary resection and anastomosis or stricturoplasty was done. Wound was then closed in layers.

The cases were carefully followed up under observations for post-operative complications e.g. surgical site infection, fever, anastomotic leak and wound dehiscence. Anti-Salmonella medicines were given in the cases in which Widal test was positive or there were intra operative findings. Patients were discharged after 5 days in uncomplicated cases.

Pre-structured proforma was used for data collection. Details regarding socio- demographic profile, signs and symptoms, findings of different investigations, observations during surgery, histopathological report and surgical outcome were recorded. Data entry was done in Microsoft Excel 2007 and analyzed using SPSS v 16.0. Informed consent was taken in all the cases and confidentiality of records was maintained.

### **Results and Discussion**

The present study included 48 patients with ileal perforation. **Table - 1** shows the profile of these cases. Mean age of the patients was  $34.4 \pm 8.8$  years. Number of males was more than females (Ratio of 3.4:1). All the patients suffered from abdominal pain and distension (100%). 87.5% had constipation, 68.8% had fever and 47.9% suffered from vomiting.

About two-third (68.8%) patients were presented early within 72 hours. Single perforation was seen in 64.6% cases while the remaining (35.4%) had more than one perforation.

**Table - 2** shows that ileal perforation was caused by typhoid in 39.6% cases, due to tuberculosis in 16.7%, due to injury in 10.4% and other causes in 33.3% cases (**Chart – 1**). **Table - 3** shows the complications of ileal perforation surgery. Surgical site infection was seen in 35.4% cases, chest infection in 25%, anastomotic leak in 12.5% and intra-abdominal abscess in 10.4% cases.

**Table – 1:** showing profile of ileal perforation cases (N=48).

Characteristic	Frequency	%	95% CI
Age (Mean ± SD)	34.4 ± 8.8 years	-	31.9 – 36.9 years
Sex			
- Male	37	77.1 %	52.3-100 %
- Female	11	22.9 %	9.4-36.4 %
Presenting complain			
- Abdominal pain	48	100 %	71.7-100 %
- Constipation	42	87.5 %	61-100 %
- Distension	48	100 %	71.7-100 %
- Fever	33	68.8 %	45.3-92.3 %
- Vomiting	23	47.9 %	28.3-67.5 %
Time of presentation			
- Early presenters (<72 hrs)	33	68.8 %	45.3-92.3 %
- Late presenters (>72 hrs)	15	31.3 %	15.5-47.1 %
No. of perforations			
- Single	31	64.6 %	41.9-87.3 %
- Multiple	17	35.4 %	18.6-52.2 %

**Table – 2:** showing aetiology of ileal perforation (N=48).

Cause	Frequency	%	95% CI
Typhoid	19	39.6%	21.8-57.4 %
TB	8	16.7%	5.1-28.3 %
Injury	5	10.4%	1.3-19.5 %
Others	16	33.3%	17-49.6 %

**Table – 3:** showing complications after surgery for ileal perforation (N=48).

Complication	Frequency	%	95% CI
Wound infection	17	35.4%	18.6-52.2 %
Chest infection	12	25%	10.9-39.1 %
Anastomotic leak	6	12.5%	2.5-22.5 %
Intraabdominal abscess	5	10.4%	1.3-19.5 %

Kappikeri, et al. [5] found that typhoid was the most common cause of perforation (45%), followed by non-specific causes (42.5%), tuberculosis (7.5%) and traumatic injury (5%). Simple closure of perforation was done in 30% patients, resection – anastomosis was done in 20% and ileostomy proximal to simple closure/

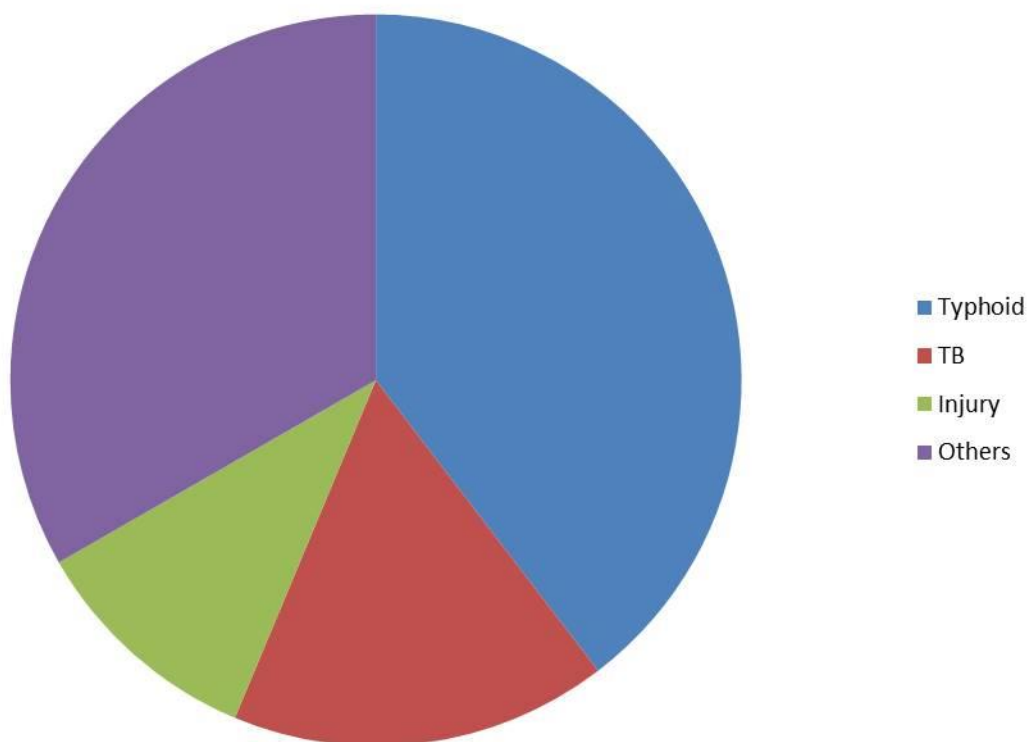
resection-anastomosis was done in 50%. Postoperative complication rate was 60% with 10% mortality. They performed simple two layered closure of perforation in patients with single perforation of up to 2cm with minimal contamination. In patients with large perforations >2cm, multiple perforations, diseased unhealthy

bowel, extensive peritoneal contamination, resection anastomosis was done.

Poornima, et al. [6] observed that there were 81.3% males and 18.7% females among patients with ileal perforation. Typhoid (82.8%),

nonspecific inflammation (9.4%), and tuberculosis (7.8%) were the major causes. These cases were mainly managed by simple closure of the perforation (74.6%) and primary resection and anastomosis (25.4%).

**Chart -1 showing aetiology of ileal perforation**



Shah, et al. [7] found that typhoid was the most common cause of nonspecific ileal perforations. The mean age of the patients in the study was 33 years. Male to female ratio of 5:1 was seen. Time between onset of pain and surgical intervention was between 10 and 96 h. 84% of the cases had single ileal perforations with 72% being located within 30 cm from ileocecal junction.

Jain, et al. [8] found male to female ratio of 6.3:1 with mean age of 36.4 years. Abdominal pain and distension were seen in all the patients. 71% patients had a single perforation with 97% perforations confined to ileum. Overall complication rate was 44.3% with surgical site infection being the most common one. The mortality rate was 17.1%. It was associated with

duration of illness of more than 48 hours, higher number of perforations and postoperative complications.

Mittal, et al. [2] compared the outcome of primary repair with loop ileostomy in ileal perforation cases. The rate of postoperative complications was higher in group A as compared to group B with 6 (20%) patients landed up in peritonitis secondary to leakage from primary repair requiring reoperation as compared to 2 (6.67%) in ileostomy closure. A ratio of 1:1.51 days was observed between hospital stay of group A to group B.

The findings of the present study as well as the above discussion indicate that the ileal

perforation is common in males. Presence of pain abdomen and abdominal distension must arouse suspicion of bowel perforation. Appropriate tests, mainly radiology must be done to rule out the same. Adequate management of typhoid is helpful in preventing perforations which account for one-third of all cases [9]. The risk of surgical site infection is high in these cases and proper preventive measures must be taken for that.

### **Conclusion**

The ileal perforation is commonly seen in third and fourth decade of life with high male preponderance. Abdominal pain and distension are seen in all cases. About one third of the cases present late. Typhoid and tuberculosis account for half of the cases. Surgical site infection is the most common complication observed.

### **References**

1. Wani RA, Parray FQ, Bhat NA, Wani MA, Bhat TH, Farzana F. Non-traumatic terminal Ileal perforation. *World J Emerg Surg.*, 2006; 1: 7.
2. Mittal S, Singh H, Munghate A. A Comparative Study between the Outcome of Primary Repair versus Loop Ileostomy in Ileal Perforation. *Surgery Research and Practice*, 2014; Article ID 729018: 1-4.
3. Talwar S, Sharma RK, Mittal DK, Prasad P. Typhoid enteric perforation. *Aust NZ J Surg.*, 1997; 67: 351-353.
4. Nuhu A, Dahw S, Hamza A. Operative management of typhoid Ileal perforation in children. *African J Pediatr Surg.*, 2010; 7(1): 9-13.
5. Kappikeri VS, Ingalalli VV. Analysis of Outcome of Surgical Management in Ileal Perforation with and Without Ileostomy. *Sch. J. App. Med. Sci.*, 2016; 4(4B): 1199-1207.
6. Poornima R, Venkatesh KL, Goutham MV, Nirmala, Hassan N. Clinicopathological study of Ileal perforation: study in tertiary center. *Int Surg J.*, 2017; 4: 543-9.
7. Shah S, Gandhi JP. Role of ileostomy in enteric perforation. *IJSS Journal of Surgery*, 2015; 1: 10-15.
8. Jain S, Meena LM, Ram P. Surgical management and prognosis of perforation secondary to typhoid fever. *Tropical Gastroenterology*, 2016; 37(2): 123-8.
9. Yashaswi YK, Bhushan V, Prakash P, et al. A descriptive study of surgical management of ileal perforation. *J. Evolution Med. Dent. Sci.*, 2017; 6(80): 5637-5640.