


Original Research Article

Assessment of Extra Dural Hematoma - Factors affecting morbidity, mortality and outcome

P Prahaladu¹, M V Vijaya Sekhar^{2*}, K Satyavara Prasad³, Hemal Chheda⁴

¹Assistant Professor, ²Associate Professor, ³Professor and Head, ⁴Resident
Department of Neurosurgery, Andhra Medical College, Visakhapatnam, India

*Corresponding author email: nsvijayasekhar@gmail.com

	International Archives of Integrated Medicine, Vol. 6, Issue 9, September, 2019. Copy right © 2019, IAIM, All Rights Reserved. Available online at http://iaimjournal.com/ ISSN: 2394-0026 (P) ISSN: 2394-0034 (O)	
	Received on: 28-08-2019	Accepted on: 02-09-2019
Source of support: Nil		
Conflict of interest: None declared.		
How to cite this article: P Prahaladu, M V Vijaya Sekhar, K Satyavara Prasad, Hemal Chheda. Assessment of Extra Dural Hematoma - Factors affecting morbidity, mortality and outcome. IAIM, 2019; 6(9): 102-107.		

Abstract

Background: Extradural hematomas occur in approximately 2% of all patients of head injuries and 5-15% of fatal head injuries. EDH is considered to be one of the most serious conditions of head injury requiring immediate diagnosis and surgical intervention.

Aim and Objectives: The purpose of this study was to evaluate the clinical presentation of patients with extradural hematoma and to decide upon the mode of management and to study the results of the management and the outcome and the factors affecting morbidity and mortality.

Materials and Methods: Patients with EDH admitted in Neurosurgery Department, King George Hospital Andhra Medical College, Visakhapatnam were studied. Study period was one year July 2018 to June 2019. The sample size of the study was 106 patients who fulfill the inclusion and exclusion criteria. All the patients with head injury, diagnosed to have EDH on CT scan were included in the study. The management includes conservative measures and/or surgical intervention. The patients' outcome was assessed during the hospital stay, at discharge and followed up to 6 months after discharge. The various factors were analyzed which are likely to affect the outcome.

Results: Temporo-parietal and temporal region was the most common location of EDH. The most significant factors which influences outcome are - time of surgical intervention, older age group, low GCS and associated injuries on CT scans like contusions and other injuries. The patients were followed after 1, 3 and 6 months.

Conclusion: From this study, it was observed that neurological status of patient at the time of presentation, time of surgical intervention, associated injuries on CT scan and the volumetric details of EDH are the most important factors in management and outcome of EDH.

Key words

Road traffic accidents, Accidental fall, Outcome in EDH, GCS, Associated injuries.

Introduction

Head injury is one of the most important public health problem and challenge due to high morbidity and mortality particularly in young and productive age group. Over 5.56 million accidents occur worldwide per year with 1.2 million deaths annually and 3400 deaths per day, in which India has highest rate of head injury worldwide [1].

Extradural hematomas occur in approximately 2% of all patients of head injuries and 5-15% of fatal head injuries. EDH is considered to be one of the most serious conditions of head injury requiring immediate diagnosis and surgical intervention [2]. Extradural hematoma is abnormal collection of blood between dura and calvarium usually due to torn middle meningeal artery and its branches, but it can be from torn venous sinus or bleeding from fracture lines. It is mostly caused by trauma [3]. Literature shows overall incidence of EDH in Traumatic Brain Injury (TBI) patients has been reported to be in the range of 2.7 to 4%. Traffic related accidents, falls, and Assaults accounts for 53%, 41.5% and 4.7% respectively of all EDH. Among all these patients around 9% require craniotomy [4-6].

Peak incidences of EDH are seen in 2nd decade of life and mean age of EDH patients is between 20-30 years. Extradural hematoma is rare in extremes of ages. Mortality rate vary from 10-40% and is an index of efficiency and alertness of healthcare system in country. Widespread availability of CT scans has increased diagnosis and early intervention of EDH. CT scan also help determining of severity by letting us know the site, size, shape and mass effect along with associated intracranial injuries. Earlier, mortality rate of EDH was 86% [3, 7] which has reduced

to 5-12% [3] due to introduction of CT scan. Commonly used predictors of outcome include Age, Glasgow Coma Scale (GCS), pupillary reaction, brainstem reflexes and CT findings [8, 9]. Neurological status at the time of admission is most important factor for prediction of outcome of patient. Considering all these factors, mode of management is decided whether patient requires surgical or conservative management.

We analyzed 106 presented cases during the one year study period. Based on the factors- GCS, clinical picture and Clot size and midline shift on CT scan, it was decided if management is conservative or surgical intervention.

Materials and methods

The study was conducted in department of neurosurgery of Andhra medical college and tertiary health care hospital between the July 2018 – June 2019. A total of 106 subjects were included in present study after they satisfy inclusion criteria. All head injuries with any size of EDH either in isolation or with combination of other pathologies, any age were included. Those who do not wish to be a part of study were excluded. Also other isolated pathologies on CT scan excluded.

The cases were selected at random and were admitted as surgical emergencies. Written and informed consents taken from all the subjects participating in study. For present study, clinical history i.e., nature of injury, nausea/vomiting, loss of consciousness, lucid interval, convulsions, ENT bleed were taken. Diagnosis confirmed on CT scan in all as a primary diagnostic investigation tool. CT parameters of site, size, clot thickness, clot volume, mass effect in form of subfalcine, uncal and central

herniation, and other associated pathologies recorded.

All patients with GCS < 8 were admitted directly into ICU, Initial resuscitation done if needed.

Indication for surgery:

- EDH volume > 30 ml
- Pupillary asymmetry
- Focal neurological deficits
- Mass effect in CT scan

Informed consent was taken from all patients for - examination, investigation and surgery. All patients with above indications were taken for emergency surgery. Outcome of the patients was assessed immediately by improvement of GCS, clinical improvement in neurological status and using Glasgow Outcome Scale (GOS) after discharge. Discharged patients followed up of at 1, 3 and 6 months and their neurological status was regularly assessed. The results were analyzed (**Figure – 1 to 8**).

Results

In the present study, maximum number of patients having EDH belonged to age group of 21-30 years, followed by 41-50 years age group, least common age group involved being age above 60 years (**Table - 1**).

Table – 1: Age distribution.

Age (in years)	No. of patients	%
<=10	7	6.61
11-20	13	12.26
21-30	32	30.19
31-40	18	16.98
41-50	21	19.81
51-60	12	11.32
61+	3	2.83
Total	106	100

Youngest in the series was 3months age and oldest was 76 years. Out of 106 patients, 90 patients were males and 16 patients were females. Male to female ratio was 5.6:1.

Table – 2: Mode of injury.

Mode of Injury	No. of patients	%
Road traffic accident	55	51.88
Self-fall	44	41.50
Assault	5	4.7
Fall from cot / cradle	2	1.88
Total	106	100

Table – 3: Glasgow Coma Scale.

GCS	No. of patients	%
Mild (13-15)	52	49.06
Moderate (9-12)	18	16.98
Severe (3-8)	36	33.96
Total	106	100

Table – 4: Clinical presentation.

Clinical sign	No. of patients	%
Features of ↑ ICP Bradycardia, HTN, altered sensorium	18	16.98
Anisocoria	10	9.43
Battle sign	5	4.72
Black eye	73	68.87
Scalp swelling	13	12.26

Table – 5: Site of EDH.

Region	No. of patients	%
Temporal/Temporo-parietal	49	46.22
Frontal	18	16.98
Parietal	20	18.86
Fronto-temporal	4	3.77
Occipital / parieto occipital	7	6.6
Fronto-parietal	3	2.83
Posterior Fossa (infratentorial)	5	4.71
Total	106	100

Mode of injury of patients in this study was due to road traffic accidents (55) patients, self-fall 44 and 5 patients were due to assault (**Table - 2**). 2 cases were from fall from cradle/ cot.

Severity of head injury was assessed by Glasgow Coma Score. Majority of patients (52) had GCS

of 14-15 having mild head injury. 18 patients with GCS of 9-13 having moderate head injury and 36 patients had GCS of 3-8 having severe head injury (Table - 3).

Table – 6: Side of EDH.

Side of EDH	No. of patients	%
Right	64	60.38
Left	41	38.68
Bilateral EDH	1	0.94
Total	106	100

Table – 7: CT findings.

CT findings	No. of patients	%
Clot volume >30 ml	43	40.57
Clot volume <30 ml	63	59.43
Midline shift present	23	21.70
Herniation present	12	11.32

Table – 8: Mode of management

Mode of management	No. of patients	%
Conservative	55	51.89
Surgery	51	48.11
Total	106	100

Table – 9: Glasgow outcome score distribution.

Glasgow outcome score	No. of patients	%
Good recovery (5)	76	71.70
Moderate disability (4)	8	7.55
Severe disability (3)	3	2.83
Persistent vegetative state (2)	0	0.00
Dead (1)	19	17.92
Total	106	100

In this study, 18 patients had presented with altered sensorium/ vomiting/ headache/ neurological deficits. Bradycardia, Anisocoria was seen in 10 patients (9.43 %), Battle's sign in 5 patients (4.72 %) and Black eye in 73 patients (68.87 %) (Table - 4). Associated Scalp swelling was in 13 patients. None of the patients presented with lucid interval.

Figure – 1: Right Temporal EDH.

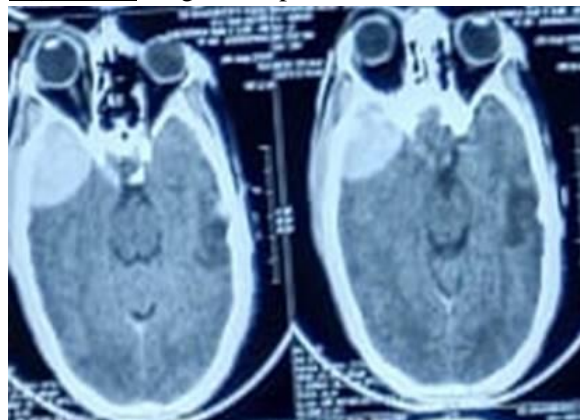


Figure – 2: Associated parietal bone fracture extending into temporal bone.

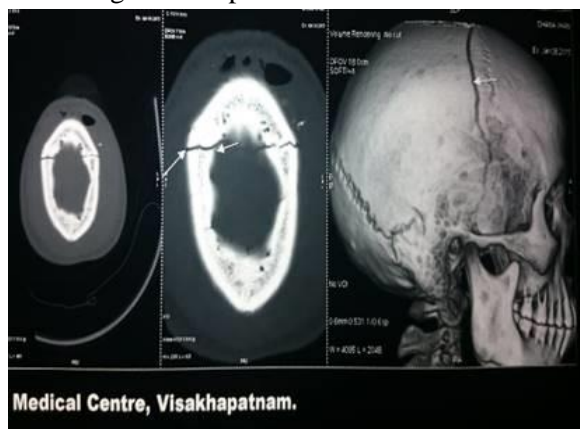
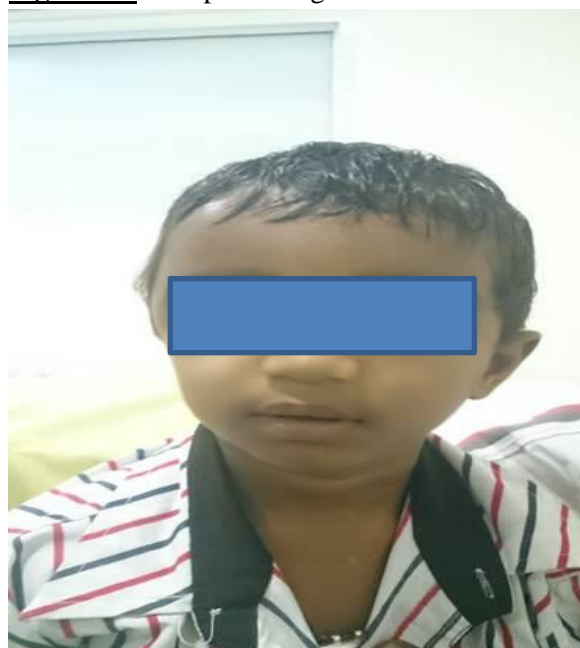
Figure – 3: Scalp swelling.



In the present study, most common site of EDH was Temporal in 27 and temporo-parietal in 22,

followed by parietal in 20, frontal in 18 patients. 4 patients had fronto-temporal region. 6 patients had EDH in occipital and 1 patient had EDH in parieto-occipital subgroups. 3 patients had EDH in fronto-parietal, posterior fossa EDH were 5 patients (Table - 5).

Figure – 4: High Fronto-parietal EDH.

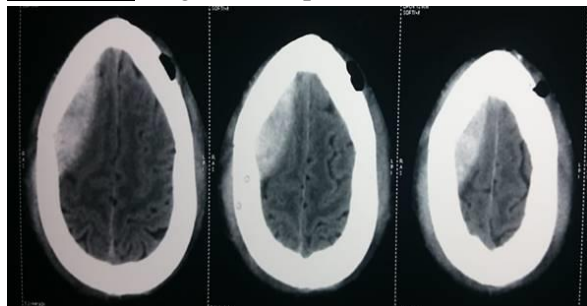


Figure - 5: High parietal right EDH with mass effect.

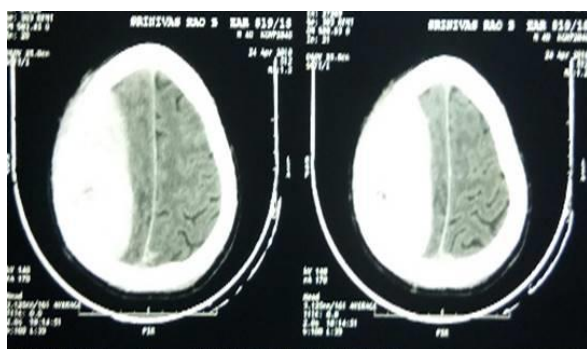
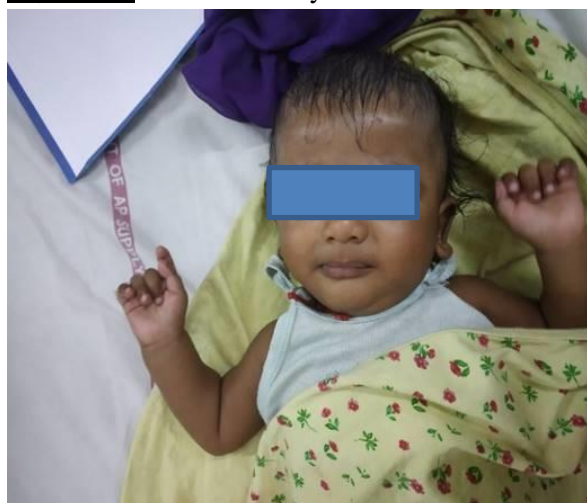
Figure – 6: 3 months baby fall from cot.



In our study, out of 106 patients 64 patients (60.38%) had EDH on right side, 41 patients (38.68%) on left side and 1 patient (0.94%) had Bilateral EDH (Table – 6).

Figure – 7: Posterior fossa EDH right side.

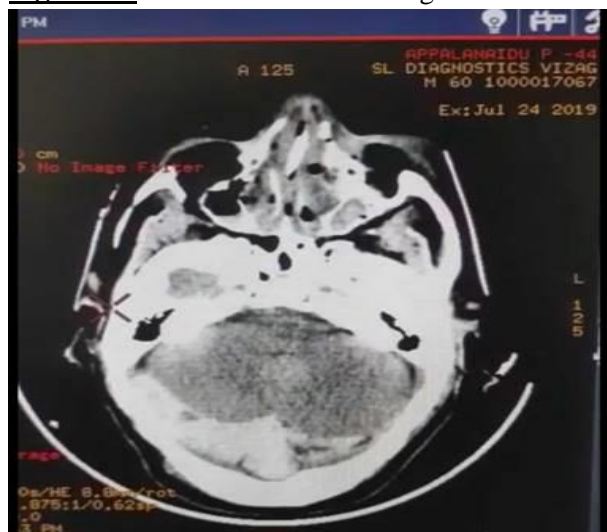
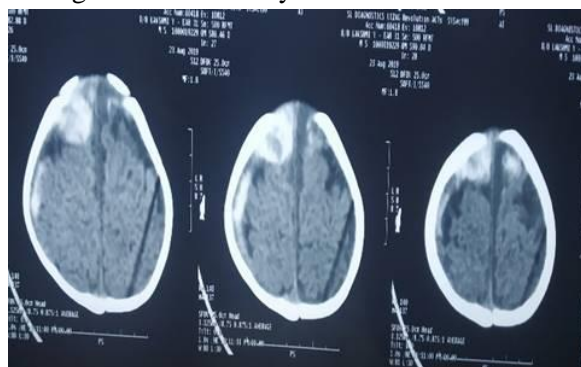


Figure – 8: 3 months baby having EDH, managed conservatively.



CT Brain findings of EDH and its effects were as follows. Clot volume more than 30 ml was found in 43 patient and less than 30 ml in 63 patients. Midline shift was noted in 23 patients. Brain herniation was present in 12 patients (Table - 7). 15 patients have a time delay of more than 6 hours which resulted in poor outcome.

Among 30 patients with EDH, 55 patients (51.89 %) were conservatively managed and 51 patients (48.11%) were managed by surgery (Table - 8).

76 cases improved with no deficits and had a GOS of 5. A total of 19 deaths and no Persistent vegetative state in our study (Table – 9).

Discussion

Head injury is the leading cause of morbidity and mortality. Extradural Hematoma, (EDH) due to bleeding from middle meningeal vessels is a common condition, which can have a good outcome, if intervened early. The availability of Computed Tomography (CT) has increased the diagnosis of extradural hematomas. Earlier, the mortality rates used to be high, around 86%. The same was reduced now by widespread availability of CT scan, and timely surgical intervention to 5 to 12% [4, 10].

Conclusion

From this study, it is observed that neurological status of patient at the of admission and other factors like age, poor GCS, time delay, associated brain injuries/ herniation on CT scan were important prognostic factors determining outcome. Easy detection by widely available CT scans and early intervention improves the outcome.

References

1. Mahapatra AK. Textbook of head injury. 4th edition; CBS publishers, 2014, p. 1.
2. Ramamurthi and Tandon's Manual of Neurosurgery; Jaypee Brothers, 2014, p. 440.
3. Rengachary SS, Ellenbogen RG. Principles in Neurosurgery; 3rd edition, Elsevier, p. 2081.
4. Bullock MR, Chesnut R, Ghajar J, Gordon D, Hartl R, Newell DW, et al. Surgical management of acute epidural hematomas. Neurosurgery, 2006; 58(Supplement): 52-7.
5. Thurman D, Guerrero J. Trends in hospitalization associated with traumatic brain injury. JAMA, 1999; 282: 954-7.
6. Chowdhury NK, Raihan MZ, Chowdhury FH, Ashadullah ATM, Sarkar MH, Hossain SS. Surgical management of traumatic extradural haematoma: Experiences with 610 patients and prospective analysis. Indian Journal of Neurotrauma (IJNT), 2008; 5: 75-9.
7. Bricolo A, Pasut L. Extradural hematoma: Towards zero mortality. A prospective study. Neurosurgery, 1984; 14: 8-12.
8. Navdeep SS, Vikas R, Yashbir D, Grewal SS. Factors predicting outcome in patients with severe head injury: Multivariate analysis. IJNT, 2012; 9: 45-8.
9. Narayan RK, Greenberg RP, Miller JD, Enas GG. Improved confidence of outcome prediction in severe head injury. J Neurosurg., 1981; 54: 751-62.
10. Kuday C, Uzan M, Hanci M. Statistical analysis of the factors affecting the outcome of extradural hematomas: 115 cases. Acta Neurochir (Wein)., 1994; 131: 203-6.