

Original Research Article

Analysis of expression of fascin in oral lichen planus: An immunohistochemical study

Mohammad Ehtisham^{1*}, Sonia Gupta², Sheeba Nissar³, Shahla Khan⁴


¹Senior Lecturer, Department of Oral Pathology, Teerthanker Mahaveer Dental College and Research Centre, Moradabad, U.P., India

²Tutor, Department of Oral Pathology, Govt. Dental College & Hospital, Srinagar (J&K), India

³Senior Lecturer, Department of Periodontics & Oral Implantology, Teerthanker Mahaveer Dental College and Research Centre, Moradabad, U.P., India

⁴Senior Lecturer, Department of Oral Pathology, Institute of Dental studies & Technologies, Modinagar, U.P., India

*Corresponding author email: ehtians@gmail.com

| | | |
|---|---|--------------------------------------|
|  | International Archives of Integrated Medicine, Vol. 7, Issue 8, August, 2020. | |
| | Available online at http://iaimjournal.com/ | |
| | ISSN: 2394-0026 (P) | ISSN: 2394-0034 (O) |
| | Received on: 10-07-2020 | Accepted on: 29-07-2020 |
| | Source of support: Nil | Conflict of interest: None declared. |
| How to cite this article: Mohammad Ehtisham, Sonia Gupta, Sheeba Nissar, Shahla Khan. Analysis of expression of fascin in oral lichen planus: An immunohistochemical study. IAIM, 2020; 7(8): 31-36. | | |

Abstract

Background: Oral lichen planus (OLP) is a T-cell mediated chronic inflammatory oral mucosal disease of unknown etiology. Dendritic cells are thought to be involved in the pathogenesis of the lesion possibly by the recruitment and activation of T-lymphocytes. Fascin is a 55-kd globular actin-cross linking protein that detects the mature dendritic cells.

Aim: To determine the role of dendritic cells in the pathogenesis of oral lichen planus (OLP) by using IHC marker Fascin.

Materials and methods: A retrospective study was conducted on 20 formalin- fixed, paraffin-embedded tissue blocks, including normal oral mucosa (10 cases) and oral lichen planus (10 cases). Immunohistochemical staining was done by using marker Fascin and number of positive cells was observed in the standardized areas of submucosa.

Results: In the present study, increased number of positive cells in the OLP as compared to NOM and the p-value was found to be statistically significant.

Conclusion: Mature dendritic cells are considered to play an important role in the pathogenesis of OLP.

Key words

Mature dendritic cell, Oral Lichen planus, Fascin.

Introduction

Lichen Planus was derived from the Greek word *leikhēn*, meaning "a tree moss" and the Latin word *planus*, meaning "flat" [1]. It was first described by British physician Erasmus Wilson in 1869 and it is thought to affect 0.5-1 per cent of the world's population [2]. Oral lichen planus is a chronic inflammatory disease that affects the skin as well as mucous membrane. Oral lichen planus is the mucosal counterpart of cutaneous lichen planus. It occurs most frequently in the fourth decade of life and affects women more often than men in a ratio of 1.4:1 [3-5]. Clinically, it appears as reticular, papular, plaque-like, erosive, atrophic or bullous types. In the oral cavity, the buccal mucosa, tongue and gingiva are most commonly involved and they may appear weeks or months before the appearance of cutaneous lesions. The skin lesions appear as violaceous, flat-topped papules in ankles, wrist and genitalia however typically, the facial skin is spared [6, 7]. In the oral cavity, the lesion appears as a radiating white, gray, velvety, thread like papules in a linear, annular and retiform pattern forming typical lacy, reticular patches, rings and streaks. A tiny white elevated dot is present at the intersection of white lines known as Wickham striae as compared to striae of Wickham seen in the skin [2, 8, 9].

Both specific and non-specific mechanisms may play an important role in the etiopathogenesis of oral lichen planus. Specific mechanisms comprised of antigen presentation by basement layer keratinocytes and cytotoxic T lymphocyte that resulted in death of antigen-specific keratinocytes, however non-specific mechanisms involved in mast cell degranulation and matrix metalloproteinase activation. These combined mechanisms, then cause T lymphocytes accumulation in the lamina propria underlying the epithelium, intraepithelial T lymphocytes migration, breakdown of basement membrane and keratinocyte apoptosis, all of which are

characteristic features of oral lichen planus [3]. Dendritic cells (DC) play a key role in these immunopathological features with respect to antigens presented to T-cell [10].

Fascin is a 55-kDa actin binding protein that helps in forming actin bundles. They also play an important role in cell transformation and in increasing cell motility. Fascin antibody detect mature dendritic cell, histiocytes, smooth muscle cells, endothelial cells, squamous epithelial cells and the lining of the splenic sinuses [11, 12]. The aim of the present study was to determine the role of dendritic cells in the pathogenesis of oral lichen planus (OLP) by using IHC marker Fascin.

Materials and methods

A retrospective study was conducted on 20 formalin fixed paraffin embedded tissue blocks comprising of 10 cases of normal oral mucosa and 10 cases of oral lichen planus histopathologically diagnosed (using hematoxylin and eosin) and retrieved from archives of the Department of Oral Pathology IDST College, Modinagar and from a private laboratory in Jaipur in the year 2016. These blocks were selected randomly from the archives and histologically (using H & E stained sections) confirmed as normal oral mucosa and oral lichen planus.

Inclusion criteria: Patients with clinically and histopathologically diagnosed OLP and normal healthy subjects were taken as controls.

Exclusion criteria: Patients with OLP on medication for other systemic diseases and pregnant women with OLP.

The study and control samples were subjected to immunohistochemical marker fascin and to evaluate the expression of mature dendritic cells in the submucosa.

Two to three serial sections of 3 µm thickness were made, taken in pre-coated (3- Aminopropyl triethoxy silane) slides for immunohistochemistry. The slides were placed on the slide racks and then into the hot air oven at a temperature of 55 °C to 65 °C for half an hour to melt the wax and for the adhesion of the sections onto the slide. The sections were cleared by passing them through 3 changes of xylene for 5 minutes each. The sections were rehydrated following a routine protocol and kept in tap water for 10 min. Heat antigen retrieval procedure was done under citrate buffer of pH 6 using pressure cooker. After cooling, the sections were treated with 3% hydrogen peroxide and power block for 10 min in each to reduce nonspecific binding. The sections were incubated with mouse monoclonal anti-human primary antibodies raised against fascin (Biocare Medical manufacture's) for 30 min. Then, slides were washed in phosphate buffered saline and treated with polyhorseradish peroxidase enzyme for 30 min. Immunostaining was developed by treating the sections with freshly prepared diaminobenzidine (3,3'-diaminobenzidine

tetrahydrochloride) solution for 5 min, and the excess chromogen was removed by rinsing. The slides were immersed in Mayer's hematoxylin for 4 minutes and then washed gently under running tap water for about 10 minutes. The sections were dehydrated in graded alcohol, cleared with xylene, and mounted using DPX. All the sections were determined under the light microscope at 100X magnification by two observers so as to eliminate subjective bias.

Evaluation of the staining: Presence of brown coloured precipitate of cytoplasmic staining as well as cell body with at least well-visualized dendrites was indicative of positive immunoreactivity. Fascin antibody also reacted with the basal, parabasal and suprabasal layers of epithelium (**Figure - 1**). Antibody positive cells were counted manually at high power (400X) in five different randomly selected fields in the submucosa specimens. The slide was moved in a single direction from left to right of every slide so as to avoid repetition of already examined fields.

Figure - 1: Photomicrograph showing fascin expression in A) Normal oral mucosa and B) Oral lichen planus (100X).

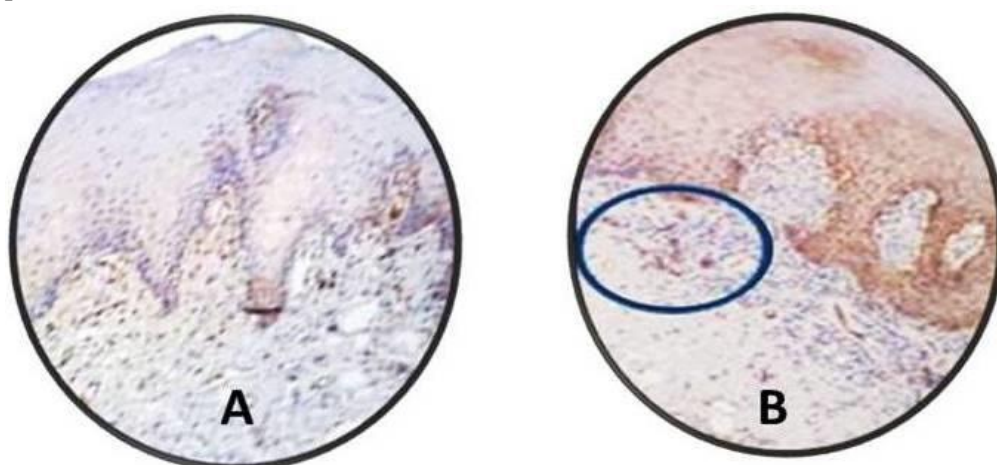


Table - 1: Interobserver reliability analysis for fascin immunostaining.

| Reliability Analysis | Cronbach's α Test |
|----------------------|--------------------------|
| | Observer 1 & Observer 2 |

Results

Data on immunohistochemical expression of Fascin in all tissue sections was collected and statistically analysed with the help of SPSS software (statistical package for social sciences) version 19.0 using mean, standard deviation, independent T test, Post hoc Bonferroni test and Cronbach's alpha reliability test. A probability value of ≤ 0.05 was considered to be statistically significant. A good interobserver reliability was observed on applying Cronbach's alpha

reliability test to the observations obtained from all two observers for the assessment of fascin expression (**Table - 1**). The mean \pm standard deviation (SD) of fascin positive cells in normal oral mucosa was reported to be 3.86 ± 0.56 and in oral lichen planus cases was 19.97 ± 6.52 . A significant correlation ($p < 0.001$) was observed between the mean of fascin positive cells in normal oral mucosa and in oral lichen planus (**Table - 2**).

Table - 2: Comparison between fascin expression in normal oral mucosa and in oral lichen planus.

| Group | Fascin positive cells | |
|--------------------|---|------|
| | Mean | SD |
| NOM | 3.86 | 0.56 |
| OLP | 19.97 | 6.52 |
| Independent t test | 8.442 | |
| p – value | < 0.001 | |
| Group | Fascin positive cells [Post hoc Bonferroni (p – value)] | |
| Group 1 vs Group 2 | < 0.001 | |

SD- Standard deviation, NOM- Normal oral mucosa, OLP-Oral lichen planus

Discussion

OLP is a T-cell mediated autoimmune disease in which the auto-cytotoxic CD8+ T cells cause apoptosis of the basal cells of the oral epithelium. In this disease, the mechanism involves keratinocyte antigen expression or unmasking of an antigen that may be a self-peptide or a heat shock protein. Following this, T cells (mostly CD8+ and some CD4+ cells) migrate into the epithelium either due to random encounter of antigen during routine surveillance or a chemokine-mediated migration toward basal keratinocytes [3, 13, 14].

Dendritic cells (DCs) are specialized antigen presenting cells that originate from bone marrow progenitor cells, and also play an essential role in bridging innate and adaptive immune responses [15]. DCs have the ability to migrate to lymph nodes and present captured antigens in the form of peptides bound to MHC class molecules. DCs exist in two stages of maturation. Immature cells are present all over the body where they act as sentinels, continuously taking up antigen and

undergoing activation. Activation leads to the secretion of pro-inflammatory cytokines, resulting in up-regulation of co-stimulatory molecules and migration to the lymph nodes. During their maturation, DCs lose their antigen-capturing capacity and become mature immunostimulatory cells which have the ability to activate naïve T cells that differentiate to either Th1 or Th2 cells in a regional lymph node. DCs also present antigens to some of memory T cell [16, 17].

Fascin is a 55-kDa, actin-bundling protein that regulates the rearrangement of cytoskeletal elements, and the interaction between the cytoskeleton and the cell membrane in response to extra or intracellular signals. Fascin antibody especially detects mature DC, histiocytes, smooth muscle cells, endothelial cells and squamous epithelial cells [18].

In the present study, we determined mature dendritic cells in the control oral epithelium as well as in OLP tissues using

immunohistochemical marker, Fascin. In this study, increased number of fascin positive cells in oral lichen planus as compared to normal oral mucosa with a statistically significant p-value. These results were in accordance with the study carried out by Mukae S, et al. [19]. They signified that mature DC (fascin+) were recognized in the submucosa specimens but not observed in the epithelium from OLP or control.

In this study, we have shown that fascin expression is critical in the antigen presentation activity of mature DC in oral lichen planus. In the present study, we observed that fascin expression is strongly correlated with DC maturity. Furthermore, we found that fascin expression plays a significant role in the function of DC antigen presentation to CD4+ T cells. Thus, mature dendritic cells (DC) play an important role in the immunopathogenesis of oral lichen planus.

Conclusion

In the present study, fascin positive cells were more in OLP as compared to NOM. Mature dendritic cells are considered to play an important role in the pathogenesis of OLP with respect to antigen presentation to T cells.

References

1. Barnes L, Eveson JW, Reichart P and Sidransky D. World health organization classification of head and neck tumours. Lyon: IARC Press, 2004; 140, 177-179.
2. Shafer WG, Hine MK, Levy BM, Rajendran R, Sivapathasundharam B. Text book of oral pathology, 7th edition, Elsevier, 2012; 94, 808.
3. Sugarman PB, Savage NW, Walsh LJ, Zhao ZZ, Zhou XJ, Khan A, et al. The pathogenesis of oral lichen planus. *Crit Rev Oral Biol Med.*, 2002; 13: 350-365.
4. Gorsky M, Epstein JB, Hasson-Kanfi H, Kaufman E. Smoking habits among patients diagnosed with oral lichen planus. *Tobacco Induced Diseases*, 2004; 2(2): 103-8.
5. Eisen D. The clinical features, malignant potential and systemic associations of oral lichen planus: a study of 723 patients. *J Am Acad Dermatol.*, 2002; 46(2): 207-14.
6. Ismail SB, Kumar SK, Zain RB. Oral lichen planus and Lichenoid reactions; Etiopathogenesis, diagnosis, management and malignant transformation. *J Oral Sci.*, 2007; 49: 89-106.
7. Canto AM, Muller H, Freitas RR, Santos PS. Oral lichen planus (OLP): Clinical and complementary diagnosis. *An Bras Dermatol.*, 2010; 85: 669-675.
8. Silverman S, Gorsky M, Lozada-Nur F. A prospective follow-up study of 570 patients with oral lichen planus: persistence, remission and malignant association. *Oral Surg Oral Med Oral Pathol.*, 1985; 60: 30-34.
9. Silverman S, Gorsky M, Lozada-Nur F, Giannotti K. A prospective study of findings and management in 214 patients with oral lichen planus. *Oral Surg Oral Med Oral Pathol.*, 1991; 72: 665-670.
10. Sloberg K, Jonsson R, Jontell M. Assessment of Langerhans' cells in oral lichen planus using monoclonal antibodies. *J Oral Pathol.*, 1984; 13: 516-24.
11. Adams JC. Roles of fascin in cell adhesion and motility. *Curr Opin Cell Biol.*, 2004; 16: 590-596.
12. Hiroi M, Kuroda N, Toi M, et al. Fascin-positive dendritic cells and fibroblastic reticulum cells build a framework of T-cell areas in lymph nodes. *Virchows Arch.*, 2004; 444: 158-163.
13. Zhou XJ, Sugarman PB, Savage NW, Walsh LJ, Seymour GJ. Intra-epithelial CD8+ T cells and basement membrane disruption in oral lichen planus. *J Oral Pathol Med.*, 2002; 31: 23-27.
14. Eversole LR. Immunopathogenesis of oral lichen planus and recurrent aphthous stomatitis. *Semin Cutan Med Surg.*, 1997; 16: 284-294.

15. Moll H, Fuchs H, Blank C, Rollinghoff M. Langerhans cells transport *Leishmania major* from the infected skin to the draining lymph node for presentation to antigen-specific T cells. *Eur J Immunol.*, 1993; 23: 1595.
16. Steinman RM, Hawiger D, Nussenzweig MC. Tolerogenic dendritic cells. *Annu Rev Immunol.*, 2003; 21: 685-711.
17. Boonstra A, Asselin-Paturel C, Gilliet M, Crain C, Trinchieri G, Liu YJ, et al. Flexibility of mouse classical and plasmacytoid derived dendritic cells in directing T helper type 1 and 2 cell development: dependency on antigen dose and differential toll-like receptor ligation. *J Exp Med.*, 2003; 197: 101-109.
18. Stossel TP. On the crawling of animal cells. *Science*, 1993; 260: 1086.
19. Mukae S, Okazaki Y, Suda HT, Nagai K, Matsumoto N, Ochiai T, et al. Detection of fascin and CCR-7 positive mature dendritic cells in oral lichen planus. *J Oral Pathol Med.*, 2009; 38: 334-342.