



Original Research Article

RADIOLOGICAL ANALYSIS OF INTERSTITIAL LUNG DISEASES

Meraj Rentia^{1*}, Himanshu Singla¹, Divya Malpani², Tushar Vaishnav³, Pradeep Jhala³

¹1st year Resident, ²3rd year Resident, ³Professor

Radiology Department, SBKS Medical Institute & Research Centre, Sumandeep Vidyapeeth, Vadodara, India

*Corresponding author email: drrentia@gmail.com

How to cite this article Meraj Rentia, Himanshu Singla, Divya Malpani, Tushar Vaishnav, Pradeep Jhala. Radiological analysis of interstitial lung diseases. IAIM, 2015; 2(6): 69-76.

Available online at www.iaimjournal.com

Received on: 22-05-2015

Accepted on: 01-06-2015

Abstract

Aims and objectives: To diagnose interstitial lung diseases using HRCT and chest X-Ray and to study and compare the different radiographic patterns evident in both conventional chest radiography and HRCT.

Material and method: The present study was a prospective and observational (non interventional) type of study. This study aimed evaluating patients coming to the Radiology Department of Dhiraj General Hospital, by using X-RAY and CT scan so as to achieve aims and objectives outlined.

Results: Of the 48 patients, 28 patients were males (58.33%) and 20 (41.67%) were females. The age of the patients ranged from 39 years to 80 years. The common diseases included in the study were idiopathic pulmonary fibrosis (25%), idiopathic NSIP (16.5%), rheumatoid arthritis (14.5%), lymphangitis carcinomatosa (8.33%).

Conclusion: In our study, 48 patients were radiologically evaluated with X - ray and CT-Scan. Chest X - ray is a primary modality used to screen patients with lung pathologies, being cheap, easy to perform and requires less radiation. HRCT is the modality of choice for diagnosis of interstitial lung diseases.

Key words

Interstitial lung diseases, X-rays, HRCT.

Introduction

Interstitial lung diseases are a diverse group of diseases which affect the lung interstitium and

share similar clinical and radiological manifestations. They are a heterogeneous group of disorders of the lower respiratory tract that

are characterised by both acute and chronic inflammation and a generally irreversible and relentless process of fibrosis in the interstitium and the alveolar walls [1]. The interstitium refers to tissues of the alveolar wall between the capillary endothelium and the alveolar epithelium and it is the site of primary injury. The term “interstitial” can be misleading as most of these conditions also affect the airway spaces and even the blood vessels, but it is the predominant and primary involvement of the interstitium that characterizes them [2].

Interstitial lung diseases are characterized by anatomical distortion of peripheral airways and interstitium, determined by a first stage of alveolitis followed by a stage of fibrosis. The natural history of several interstitial lung diseases is characterized by slow and progressive destruction of alveolar-capillary functional units, often with respiratory failure and death [3, 4]. For their smoldering evolution and non-specificity of symptoms (exertional dyspnea and cough), they may remain undiagnosed and not treated for a long time [5, 6]. Herein lies the importance of HRCT and other investigations in aiding for an early diagnosis.

Idiopathic pulmonary fibrosis is the most common interstitial lung disease in adults and generally has a poor prognosis [3]. Idiopathic pulmonary fibrosis (IPF)/usual interstitial pneumonia (UIP) is not a very well-understood entity. Current explanations of the natural history and pathogenesis of IPF/UIP are controversial, and ongoing research continues to investigate multiple hypotheses [7]. Around 15% of patients with interstitial lung disease have an underlying connective tissue disorder.

Materials and methods

The present study was a prospective and observational (non interventional) type of study. This study aims evaluating patients coming to

the radiology department of Dhiraj general hospital, by using X-RAY and CT scan so as to achieve aims and objectives outlined. This study comprised of 48 patients, time period selected in study was May 2014 to April 2015.

Inclusion criteria

- Only those patients who wanted to participate in study were included.
- Patients referred to the Radiology Department for X - ray and/or CT scan thorax investigations, and found to have lesion, were included in this study.
- Already diagnosed cases of such interstitial lung diseases which need follow up radiological investigations and were referred to Radiology Department were included in study.
- Patients presented with associated conditions and with symptoms such as rheumatoid arthritis.
- Patients with known history of industrial exposure or certain drug exposures.
- Evaluation of diffuse pulmonary disease discovered on chest radiographs, conventional CT of the chest, or other CT examinations that include portions of the chest.
- Evaluation of the lungs in patients with clinically suspected pulmonary disorders with normal or equivocal chest radiographs.
- Evaluation of suspected small and/or large airway disease.
- Quantification of the extent of diffuse lung disease for evaluating effectiveness of treatment.

Exclusion criteria

Patients presented to Radiology Department who were unfit for the study such as are pregnant or were unwilling to participate.

Protocol used to perform HRCT

- Scanogram
- 5 mm mediastinal window cuts.
- Full inspiration 1.5 mm lung window cuts in axial section
- Suspended full expiration scans at levels- aortic arch, tracheal bifurcation and above diaphragm
- Prone scans in lung window 1.5 mm cuts if indicated.

Description of tools

- X-Ray Machine: 600 mA Siemens (500 mA Siemens, 300 mA Siemens)
- CR system: Kodak/AGFA
- CT scan Machine: Siemens emotion 16 slice MDCT

Results

The present study was a prospective and observational (non interventional) type of cross sectional study. A total of 48 patients were evaluated for interstitial lung diseases in the Department of Radiology, SBKS MI&RC, Piparia from May 2014 till April 2015, constituted the study material. The results of investigation were evaluated using proportions and chi squared test. The level of significance was 0.05.

Decision criterion

We compared the P-Value with the level of significance. If $P < 0.05$, we rejected the null hypothesis and accept the alternate hypothesis. If $P \geq 0.05$, we accepted the null hypothesis.

Computations

Various computations and the P-Value were as per **Table – 1** to **Table - 5**.

Discussion

The study was carried out at the Department of Radiology, Dhiraj Hospital, Vadodara. A total of 48 patients were selected for the study. The 48

patients were subjected to both conventional chest radiograph and HRCT scan thorax and a detailed work up of these patients was performed; their clinical history, relevant past and occupational history and any laboratory data recorded. Of the 48 patients, 28 patients were males (58.33%) and 20 (41.67%) were females. The age of the patients ranged from 39 years to 80 years.

The spectrum of diseases included in the study were idiopathic pulmonary fibrosis (25%), idiopathic NSIP (16.5%), rheumatoid arthritis (14.5%) lymphangitis carcinomatosa (8.33%), asbestosis (6.25%), hypersensitivity pneumonitis (6.25%), smoking related interstitial lung disease (6.25%), cryptogenic organizing pneumonia (6.25%), sarcoidosis (2.08%), post infection (atypical mycobacterial) (2.08%), silicosis (2.08%), allergic bronchopulmonary aspergillosis (2.08%) and tuberous sclerosis (lymphangiomyomatosis) (2.08%), drug induced interstitial lung disease (2.08%), atypical usual interstitial pneumonitis (2.08%).

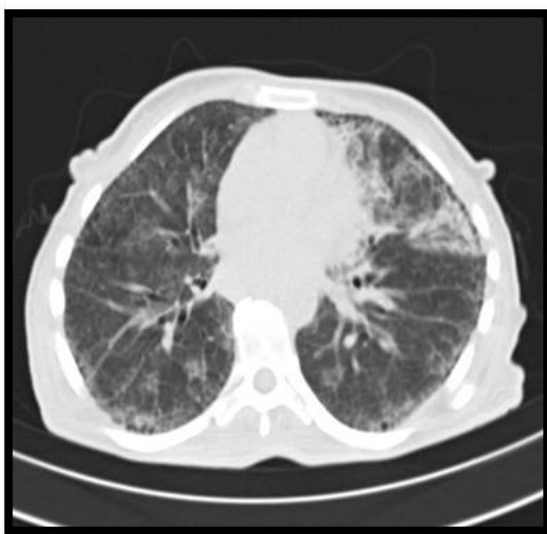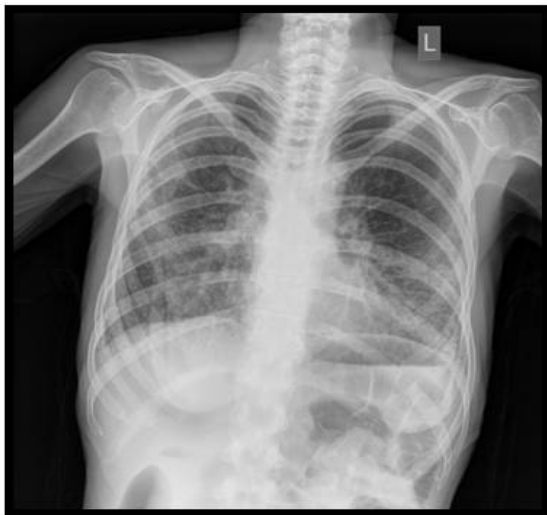The main observation in study was that higher number of samples with findings was detected by HRCT as compared to conventional radiography. Even when both modalities were able to detect the findings, HRCT could characterize the abnormality and specify its location much more accurately.

The chest radiogram can appear completely normal in patients suffering from interstitial lung diseases. Therein lies the inherent lack of sensitivity of conventional chest radiography in the diagnosis of the conditions. In our study, 2 of the 48 patients (4.16%) had no abnormalities in their chest radiographs. However HRCT was able to show changes in these patients.

The most common abnormality seen on chest radiographs was reticular opacities which were

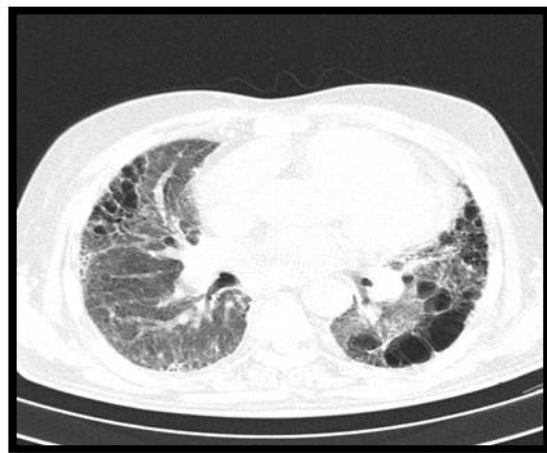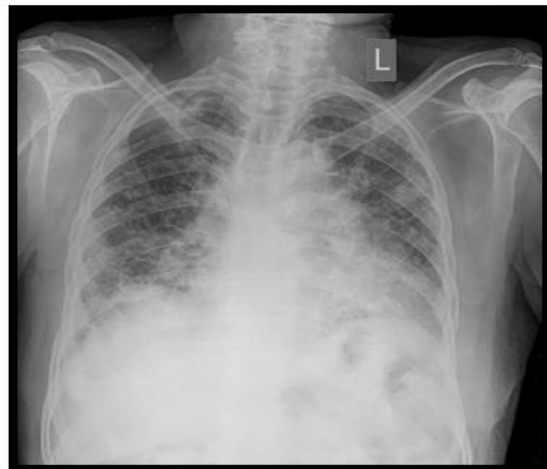observed in 89% of the cases (**Figure – 1A, 1B**). However HRCT managed to detect reticular opacities in 98% of the cases, thereby implying a much greater sensitivity in the identification of these densities. Furthermore, in the detection of these reticular opacities, although conventional chest radiography was able to differentiate between medium and coarse opacities, their detection of fine reticular densities was a cause of concern. HRCT detected fine reticular opacities in the lungs when the chest radiograph revealed no such abnormalities.

Figure – 1A, 1B: X - ray shows reticular thickening in the lower zones. HRCT shows reticular thickening with ground glass opacities and sub pleural sparing of lung.



The end stage of interstitial lung disease is characterized by honeycombing (**Figure – 2A, 2B**). It reflects extensive lung fibrosis with alveolar destruction, thereby resulting in a characteristic reticular appearance. On HRCT, it is associated with gross distortion of lung architecture, where individual lobules are no longer visible. In our study, such honeycombing was seen in 52% of the cases on HRCT while chest radiography could detect them in only 31%. On HRCT, honeycombing was much more accurately diagnosed by the presence of thick walled, air filled cysts, usually measuring 3 mm to 1 cm in diameter, typically occurring in several layers at the pleural surface.

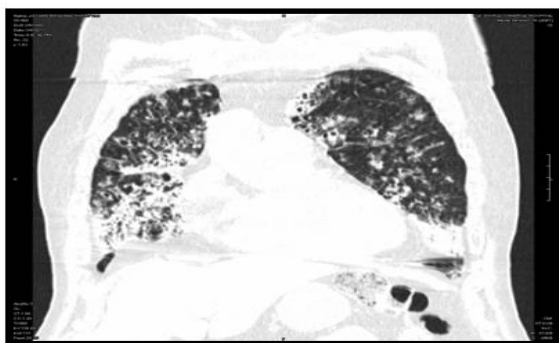
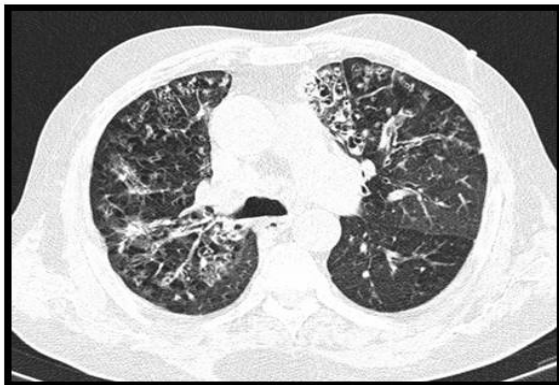
Figure – 2A, 2B: X - ray shows reticular thickening with minimal honeycombing in lower zones. HRCT shows classical sub pleural and peripheral honeycombing.



Detection of honeycombing has great clinical significance as its presence strongly suggest the diagnosis of usual interstitial pneumonia. It also indicates end stage disease, whereby the patient will gain little from a lung biopsy and hence avoid it. In this context also, HRCT definitely scores over conventional radiography.

Traction bronchiectasis or bronchial dilatation resulting from lung fibrosis was visible in 27% of the cases on chest radiography. They were typically associated with reticular opacities and in some cases with honeycombing. HRCT however managed to detect traction bronchiectasis in 54%. The bronchiectasis in these cases was typically associated with an absence of mucous plugging or fluid within the bronchi. This finding or the absence of it was much better appreciated on HRCT than conventional radiography (**Figure – 3A, 3B**).

Figure – 3A, 3B: HRCT shows asymmetrical bronchiectasis with fluid levels with mucoid impaction suggestive of allergic broncho pulmonary aspergillosis.



The detection of associated air trapping and lymphadenopathy was also greater with HRCT than with conventional radiography.

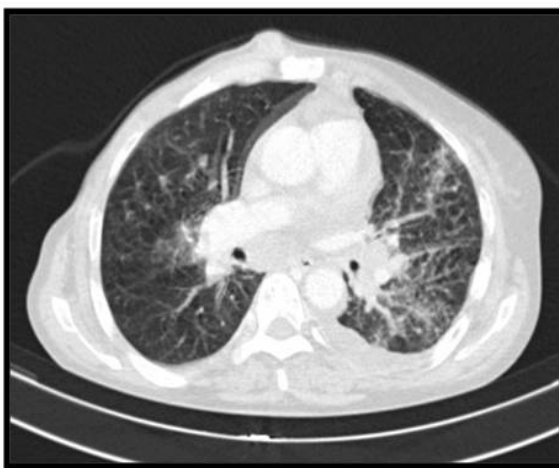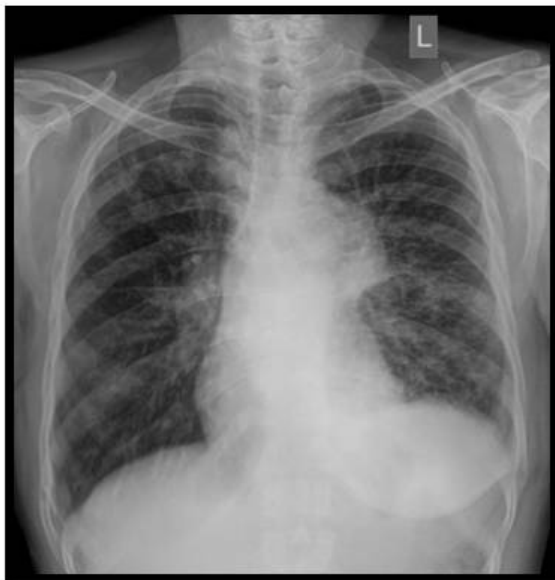Pulmonary function test was performed in 40 out of 48 patients. It was restrictive in nature with FEV1/FVC values are normal while total lung capacity was less than 65% (mild restriction) in 15 out of 40 patients and was 50-65% (moderate restriction) in 11 patients and severe restriction of <50% was seen in 14 patients.

High resolution computed tomography is a diagnostic method of choice in the evaluation of lung parenchyma. HRCT enables the evaluation of small interstitial changes, invisible on plain chest radiographs, and their assessment at the level of the lung lobule. Nodular thickening of the peribronchovascular interstitium and interlobular septa are typical in lymphangitic spread of carcinoma. Smooth peribronchovascular and septal thickenings are typical in sarcoidosis, and are only seen in some patients in the lymphangitic spread of carcinoma (**Figure – 4A, 4B**). In lymphangitis carcinomatosa lung architecture remains unchanged, which allows differentiating from sarcoidosis. In our study also, we were able to appreciate the different types of septal thickening evident in different diseases; although detailed statistical analysis in this regard was not performed.

Interstitial lung disease (ILD) is a frequent extra-articular manifestation of rheumatoid arthritis (RA). While the nonspecific interstitial pneumonia pattern predominates in most forms of connective tissue-associated ILD, studies in patients with RA-associated ILD (RA-ILD) suggest that the usual interstitial pneumonia (UIP) pattern is more common in this patient population. High-resolution CT (HRCT) scans appear accurate in identifying UIP pattern in many patients with RA-ILD. Although the data

are limited, UIP pattern appears to predict worse survival in RA-ILD patients. Larger, prospective, multicenter studies are needed to confirm this finding. We propose that the evaluation of patients with RA-ILD should focus on identifying those with UIP pattern on HRCT scans, as these patients are likely to carry a worse prognosis. In patients in whom the underlying pattern cannot be determined by HRCT scanning, surgical lung biopsy should be considered.

Figure – 4A, 4B: X - ray shows mastectomy on left side with left hilar mass and reticular thickening in left upper and mid zone. CT scan shows a left hilar mass with septal thickening as shown suggestive of lymphatic spread of tumor.



In our study, out of 7 patients of rheumatoid arthritis, 5 patients show usual interstitial pneumonitis pattern and the rest two shown on specific interstitial pneumonitis pattern.

Lymphangioleiomyomatosis (LAM) is a rare interstitial lung disease that affects women exclusively, typically during their reproductive years.

Conclusion

In our study, 48 patients were radiologically evaluated with X - ray and CT scan. Chest X - ray is a modality for preliminary diagnosis and screening of patients and HRCT proves to be a ultimate modality for near to accurate diagnosis of the pathology. Hence any case with suspected interstitial lung disease should always be subjected to HRCT to reach to the final diagnosis.

References

1. Neurohr C, Behr J. Dtsch Med Wochenschr. Diagnosis and therapy of interstitial lung diseases, 2009; 134(11): 524-9.
2. James Ward, Christine McDonald, et al. Interstitial lung disease: An approach to diagnosis and management. Australian Family Physician, 2010; 39: 644-649.
3. Kevin K. Brown. Idiopathic Pulmonary Fibrosis: Current approach to diagnosis and therapy. MedSci update, 2004; 21: 1-3.
4. Crystal RG, Fulmer JD, Roberts WC, Moss ML, Line BR, Reynolds HY. Idiopathic pulmonary fibrosis: clinical, histologic, radiographic, physiologic, scintigraphic, cytologic and biochemical aspects. Ann InternMed, 1976; 85: 769– 788.
5. Mazzoccoli G, Carughi S, De Cata A, Giuliani A, Masciale N, La Viola M, Puzzolante F, Balzanelli M. Recenti.

- Interstitial lung diseases. Prog Med., 2003; 94(5): 227-37.
6. Mazzoccoli G, De Cata A, De Pinto GD, De Matthaeis A, Vendemiale G. Immunopathogenetic and pharmacological aspects of interstitial lung diseases. Int J ImmunopatholPharmacol., 2010; 23(4): 971-80.
7. Strieter RM. Pathogenesis and natural history of usual interstitial pneumonia: The whole story or the last chapter of a long novel. Chest, 2005; 128: 526S-532S.

Source of support: Nil

Conflict of interest: None declared.

Table - 1: Age distribution of patients with interstitial lung diseases detected by radiologic investigations.

Sr. No	Age range	Total	%
1	30-39	2	4.1
2	40-49	5	10.4
3	50-59	14	29.1
4	60-69	15	31.2
5	70-79	11	22.9
6	80-89	1	2.0

Table - 2: Sex specific distribution.

	Frequency	Percentage
Female	20	41.67
Male	28	58.33
Total	48	100.0

Table - 3: Incidence of diseases depending on the occupation.

Sr. No	Occupation	No. of patients	%
1	Driver	05	10.41
2	Farmer	12	25
3	Housewife	13	27.08
4	Construction site worker	02	4.16
5	Daily wage labourer	04	8.33
6	Basket weaving	01	2.08
7	Bangle maker	01	2.08
8	Flour mill worker	03	6.25
9	Fisherman	01	2.08
10	Jute bag factory worker	02	4.16
11	Cloth mill worker	03	6.25
12	Shopkeeper	01	2.08
	Total	48	100

Table - 4: Incidence of various patterns in this cross section of population.

Sr. No	Pattern	No. of cases	Percentage
1.	Usual interstitial pneumonitis	22	45.8
2.	Non specific interstitial pneumonitis	10	20.8
3	Nodular	02	4.16
4.	Asbestosis	02	4.16
4.	Lymphangitic spread	04	8.33
5.	Desquamative interstitial pneumonia	01	2.08
6.	Lymphangioleiomyomatosis	01	2.08
7.	Cryptogenic organizing pneumonia	02	4.16
8.	Respiratory bronchiolitis-interstitia lung disease	01	2.08
9.	Others	03	6.25

Table – 5: Consolidation.

Consolidation	HRCT		X-ray		Total	χ^2	P value
	n	%	n	%			
Present	14	29.1	09	18.75	23	2.84	0.217
Absent	34	70.8	39	81.25	73		
Total	48	100%	48	100%	96		