


Case Report

Incarcerated femoral cystocele - A rare case report

P.G. Kolandaivelu¹, R. Balamurugan², R. Lakshmana³, S. Arun Prasath^{4*}

¹Professor and Head, ²Associate Professor, ³Assistant Professor, ⁴Resident
Department of General Surgery, SRM Medical College and Research Centre, Kanchipuram District,
Tamil Nadu, India

*Corresponding author email: dr.arun612@gmail.com

	International Archives of Integrated Medicine, Vol. 2, Issue 7, July, 2015. Copy right © 2015, IAIM, All Rights Reserved. Available online at http://iaimjournal.com/ ISSN: 2394-0026 (P) ISSN: 2394-0034 (O)
	Received on: 07-06-2015 Accepted on: 18-06-2015 Source of support: Nil Conflict of interest: None declared.

Abstract

Femoral hernia accounts for about 3-5% of all groin hernias. Incarceration and strangulation are more common with femoral hernia. Femoral hernia with bladder as content and its incarceration is reported very rarely in literature. Our patient is a 48 year old multiparous female who presented with left sided groin swelling with difficulty in micturition and was diagnosed to have incarcerated femoral cystocele.

Key words

Incarcerated femoral hernia, Femoral cystocele, Femoral hernia contents, Femoral hernia repair.

Introduction

Femoral hernia is a rare type of groin hernia accounting for around 3-5% [1, 2]. About 25% of femoral hernia becomes incarcerated or strangulated and a similar number is missed or diagnosed on table. The usual contents of femoral hernia are preperitoneal fat, omentum, small intestine, colon [1]. Femoral hernia with bladder as content is called femoral cystocele which accounts for about 0.36% of all groin hernias [3, 4]. Here, we have presented an interesting case of incarcerated femoral cystocele.

Case report

History

A 48 year old multiparous female presented with complaints of swelling in the left groin since 4 months associated with pain. She also complained of difficulty in micturition - 2 staged micturition and a sense of incomplete voiding. She was a known case of systemic hypertension for 10 years on regular treatment.

Examination

General examination of patient showed obesity with stable vitals. Local examination revealed a

7X6 cm swelling in the left inguinal region extending from left inguinal region to left labia majora. Swelling was irreducible. Cough impulse was absent. A diagnosis of irreducible left inguinal hernia was made clinically.

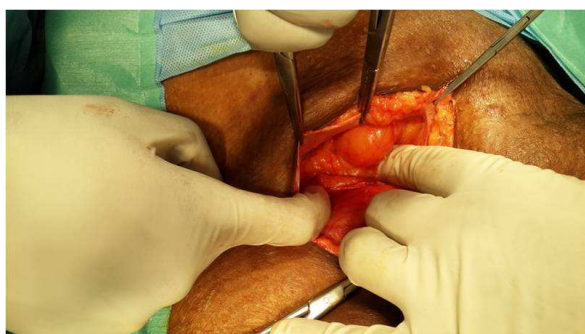
Imaging

Ultrasonography (USG) showed left inguinal hernia with part of bladder as content at this time of study.

Treatment

After obtaining anesthetic fitness, patient was taken up for surgery. Patient was catheterised. Inguinal approach was used. 6 cm skin crease inguinal incision was made and deepened. External oblique aponeurosis was opened along with superficial inguinal ring. Sac was seen to go below the inguinal ligament passing through the femoral ring and was adherent to medial side of the femoral ring. Foley's bulb was felt in the sac. The diagnosis was revised as incarcerated femoral cystocele intra-operatively. Femoral ring was dilated and the sac was reduced. The transversalis fascia was opened. Bladder was reduced back into the pelvis. Femoral ring was occluded by suturing cooper's ligament with inguinal ligament and inguinal canal integrity was reinforced with meshplasty. Patient tolerated the procedure well. (**Photo – 1, 2**)

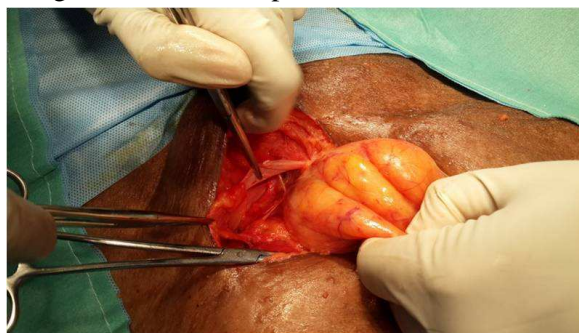
Photo – 1: Hernia sac found in the femoral ring.



Post-operative period

It was uneventful. Catheter was removed on 2nd post-operative day (POD) and patient was discharged on 3rd POD. Skin staplers were removed on 10th POD.

Photo – 2: Hernial sac containing the bladder being reduced into the pelvis.



Discussion

Femoral hernia accounts for around 5% of all groin hernias [1, 2] with female to male predominance of 1.8: 1. It is twice as common in parous as non parous women. Approximately 80% right side and 30% left side and 10% bilateral [2]. Approximately 25% of femoral hernias become incarcerated or strangulated [5, 6]. Diagnosing the nature of lump in the groin is often difficult in obese patient [2]. The usual contents of femoral hernia are preperitoneal fat, omentum, small intestine, colon [1]. Bladder as a content of groin hernias is 0.36% [3]. Only 7% of bladder hernias are diagnosed preoperatively. Most of them are diagnosed intra-operatively and some when they present with post operative complications [5]. In our case it was diagnosed intra-operatively. Causative factors of femoral cystocele are advanced age, previous vesical pathologies, multiparity, pelvic or uterine tumor, repeated or continuous exertion during urination, Prostatic enlargement or urethral stricture [2]. Femoral cystocele is classified into 3 types depending on the relationship of bladder with hernia sac.

- Extra-peritoneal - in which the herniated portion of bladder is neither engaged nor contiguous with hernia sac.
- Para-peritoneal - in which the herniated bladder process is covered on one side with peritoneum.
- Intra-peritoneal - in which the hernia sac contains the bladder process [4].

Conclusion

Femoral cystocele is an uncommon type of hernia. The exact incidence of incarcerated femoral cystocele is not clear as the available literature in this subject is very limited. We report this case for its rarity.

References

1. Kate H Kraft, Sarah Sweeney, Muta M Issa. Inguino-scrotal hernias - A report of a series and review of the literature. Canadian Urological Association Journal, 2008; 2(6): 619-623.
2. Iswanto Sucandy, Jeffrey W Kolff. Incarcerated femoral hernia in men: Incidence, diagnosis, and surgical management. North American Journal of Medical Sciences, 2012; 4(11): 617-618.
3. Gurer A, Ozdogan M, Ozlem N, Yildirim A, Kulacoglu H, Aydin R. Uncommon content in groin hernia sac. Hernia, 2006; 10(2): 152-5.
4. Anthony P. Vastola. Strangulated femoral cystocele. Ann Surg., 1933; 97(5): 724-732.
5. B.N. Kishore Kumar, Anil Kumar Sakelecha, Deepak Das, Poonam bharath kumar. Urinary bladder herniation rare preoperative incidental finding radiological features. International Journal of Biological and Medical Research, 2012; 3(1): 1459-1460.
6. Mary E. Klingensmith. The Washington manual of surgery, 6th edition, Lippincott Williams and Wilkins, chapter 26-hernias.