

Case Report


Incidence of mesenteric arterial thrombosis in protein S deficiency patients

Baburaj K^{1*}, Salma Hanam A^{2*}

¹Reader, ²PG Student

Department of Medicine, RMMCH, Chidambaram, Tamil Nadu, India

*Corresponding author email: salmahanma@yahoo.co.in

	International Archives of Integrated Medicine, Vol. 2, Issue 11, November, 2015. Copy right © 2015, IAIM, All Rights Reserved. Available online at http://iaimjournal.com/	
	ISSN: 2394-0026 (P)	ISSN: 2394-0034 (O)
	Received on: 29-10-2015	Accepted on: 05-11-2015
	Source of support: Nil	Conflict of interest: None declared.
How to cite this article: Baburaj K, Salma Hanam A. Incidence of mesenteric arterial thrombosis in protein S deficiency patients. IAIM, 2015; 2(11): 74-77.		

Abstract

Acute mesenteric ischemia refers to the sudden onset of intestinal hypo perfusion, one cause of which can be mesenteric venous occlusion. Mesenteric venous thrombosis can present acutely, or in a subacute or chronic manner. Protein S is a vitamin K-dependent plasma glycoprotein synthesized in the endothelium. The characterized function of Protein S is its role in the anti coagulation pathway. We have presented here a case of 34 years old male who presented with acute abdominal pain of sudden onset and later on diagnosed as mesenteric arterial thrombosis with protein S deficiency. Faced with such a case of arterial thrombosis without any known risk factors, the screening for thrombophilia is to be done to prevent further complication and to put patient on adequate lifelong anticoagulant therapy.

Key words

Mesenteric artery, Protein S, Thrombosis, Thrombophilia.

Introduction

Acute mesenteric ischemia refers to the sudden onset of intestinal hypo perfusion, one cause of which can be mesenteric venous occlusion. Mesenteric venous thrombosis can present acutely, or in a subacute or chronic manner [1]. Venous thrombosis is predominantly a result of stagnation of blood flow, vascular injury, and hyper coagulability. Local factors such as

splenectomy, pancreatitis appears to be associated with initial thrombus formation in the large veins, whereas systemic hyper coagulable states lead to thrombosis initiated in the intramural venules, vasa recta, and venous arcades [2]. Mesenteric vein thrombosis almost always involves the distal small intestine, superior mesenteric venous drainage and rarely involves the inferior mesenteric venous drainage. Protein S is a vitamin K-dependent plasma

glycoprotein synthesized in the endothelium. The characterized function of Protein S is its role in the anti coagulation pathway. Protein S, a vitamin K dependent glycoprotein is a cofactor for activated protein C (APC). In presence of Protein S, APC inactivates factor Va and VIIIa at an increased rate. The most common presentation of Protein S deficient state is venous thrombosis. This case is presented for rarity of Protein S deficiency presenting as arterial thrombosis [3, 4].

Case report

A 34 years old male presented with acute abdominal pain of sudden onset. There was no history of trauma. He was normotensive and euglycemic with an uneventful past and family history. No precipitating factors such as chronic drug, alcoholism, dyslipidemia were present. On examination, pulse rate was 110/min, low volume; blood pressure was 90/60 mm Hg; respiratory rate was 28/min. His cardiac and respiratory system examination was normal. Examination of the abdomen showed generalized tenderness with sluggish peristaltic movements. His routine blood investigations including liver function tests (LFT) were within normal limits. X-ray abdomen was normal. CT abdomen showed transbowel pad of fat thickening with bowel edema suggestive of vascular occlusion. CT abdomen angiography was done which showed Superior Mesenteric artery occlusion which was the cause for gangrenous bowel. Hence, laparotomy with end to end jejunostomy was done. (Figure – 1)

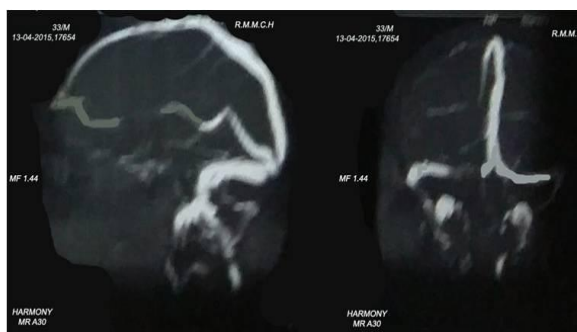
From above clinical presentation of the patient with no risk factors, hyper coagulable condition was considered. On further evaluation, his Prothrombin time was 28 sec, INR was 2.1 sec, APTT >2 min (control 30 sec). Anti-cardiolipin antibody, Lupus coagulant antibody, Anti thrombin III was normal. Protein S was 24% (normal 60-140%) and Protein C 145% (normal 70-140%). Factor V Leiden was not done. A diagnosis of Protein S deficiency was made and patient was managed with intravenous heparin

followed by oral anti-coagulant. On follow up, 6 weeks later he presented with headache. Hence MRI brain with MR-Angiogram and MR-venogram was done which showed sluggish flow in transverse sinus probably a venous thrombus. (Figure – 2)

Figure – 1: CT abdomen showed mesenteric artery occlusion.

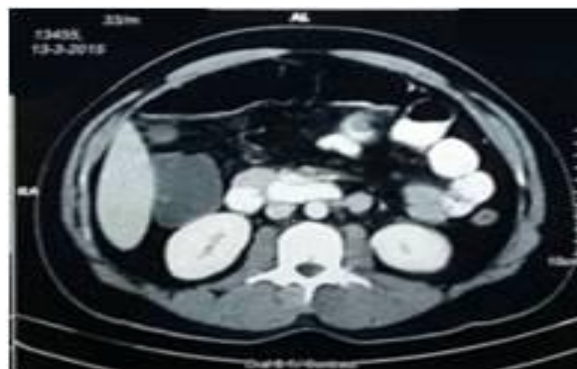

Figure – 2: MRI brain with MR-angiogram and MR-venogram showing transverse sinus with sluggish flow.



Discussion

Protein S, vitamin K dependent glycoprotein is a cofactor for activated protein C (APC). It is synthesized by hepatocytes, endothelial cells and megakaryocytes. In presence of Protein S, APC inactivates factor Va and VIIIa at an increased rate. Protein S is also a cofactor for protein C enhancement of fibrinolysis and can indirectly inhibit prothrombin time [5]. Protein S deficiency is generally an autosomal dominant condition. Protein S deficiency is caused by mutations in the *PROS1* gene. This gene

provides instructions for making protein S, which is found in the bloodstream and is important for controlling blood clotting [6]. Protein S helps to block the activity of (inactivate) certain proteins that promote the formation of blood clots. Protein S also binds to the nascent complement complex C5, 6, 7 and prevents this complex from inserting into a membrane. This function prevents the inappropriate activation of the complement system, which would cause uncontrolled systemic inflammation [7]. Although the most common presentation of Protein S deficient state is venous thrombosis or embolism, occurrence of arterial thrombosis is very rare. Only some studies and case reports have discussed the implication of thrombophilic defects in arterial thrombosis; however, the results are controversial [8]. In one cohort family study, the arterial events were diagnosed in 8% of the 144 subjects with Protein C or S deficiencies and 1% from the 94 subjects with anti-thrombin deficiency. In another sample study on carriers of familial thrombophilia (The European Prospective Cohort on Thrombophilia (EPCOT) Study), over all annual incidence of myocardial infarction and/or ischemic stroke after 20 years were 0.15% in subjects with Protein S deficiency. In a case control study, arterial thrombosis was recorded more frequently in 88 carriers with Protein S ,Protein C or anti-thrombin deficiency (19% arterial thrombosis) compared to control subjects with VTE without these deficiencies (1% arterial thrombosis) [9]. In another retrospective family cohort study published in 2008, out of 468 subjects with thrombophilic disorders, 35% had Protein S deficiency [10]. On follow up of those subjects, 11% had arterial thrombus. The high risk of arterial thrombosis conferred by any deficiency was evident only until 55 years of age, a 5 fold risk increase when compared to normal subjects and for Protein S deficiency 1.1 to 18.3 fold risks higher before 55 years. Interestingly, only Protein S and C deficiencies are related to arterial thrombosis before 55 years old. Protein S deficiency is associated with arterial thrombosis because of its synthesis by endothelial cells [11]. Endothelial injury as a trigger of thrombosis may

be enhanced by a preexisting defect in Protein S synthesis at the site of injury. Some cytoprotective effects have been attributed to Protein S [12].

Conclusion

Thrombophilia is a serious disorder that exposes the patient to life threatening arterial or venous thrombus. Faced with such a case of arterial thrombosis without any known risk factors, the screening for thrombophilia is to be done to prevent further complication and to put patient on adequate lifelong anticoagulant therapy.

References

1. Aiach M, Borgel D, Gaussem P, Emmerich J, Alhenc-Gelas M, Gandrille S. Protein C and protein S deficiencies. *SeminHematol.*, 1997, 34: 205-216.
2. Dahlback B. Advances in understanding pathogenic mechanisms of thrombophilic disorders. *Blood*, 2008, 112: 19-27.
3. Choi BK, Yang SH, Suh KH, Hwang JA, Lee MH, Si WK, et al. A case of portal vein thrombosis by protein C and S deficiency completely recanalized by anticoagulation therapy. *Chonnam Med J.*, 2011; 47: 185-8
4. Onwuanyi A, Sachdeva R, Hamirani K, Islam M, Parris R. Multiple aortic thrombi associated with protein C and S deficiency. *Mayo ClinProc.*, 2001; 76: 319-22
5. Boekholdt SM, Kramer MH. Arterial thrombosis and the role of thrombophilia. *SeminThromb Hemost.*, 2007; 33: 588–596.
6. Vossen CY, Rosendaal FR. Risk of arterial thrombosis in carriers of familial thrombophilia. *J Thromb Haemost.*, 2006; 4: 916–918.
7. Simioni P, Zanardi S, Saracino A, Girolami A. Occurrence of arterial thrombosis in a cohort of patients with hereditary deficiency of clotting inhibitors. *J Med.*, 1992; 23: 61–74.

8. Bakhtawar K, Jan-Leendert P, Nic J, Van der Meer J. Hereditary Deficiency of Protein C or Protein S Confers Increased Risk of Arterial Thromboembolic Events at a Young Age. *Circulation*, 2008; 118: 1659-1667
9. De Stefano V, Leone G, Mastrangelo S, Tripodi A, Rodeghiero F. Clinical manifestations and management of inherited thrombophilia: retrospective analysis and follow-up after diagnosis of 238 patients with congenital deficiency of antithrombin III, protein C, protein S. *Thromb Haemost.*, 1994; 72: 352–358.
10. Girolami A, Simioni P, Scarano L, Girolami B. Venous and arterial thrombophilia. *Haematologica.*, 1997; 82: 96–100.
11. Mosnier LO, Zlokovic BV, Griffin JH. The cytoprotective protein C pathway. *Blood*, 2007; 109: 3161–3172.
12. Rezende SM, Simmonds RE, Lane DA. Coagulation, inflammation, and apoptosis: different roles for protein S and the protein S-C4b binding protein complex. *Blood*, 2004; 103: 1192–1201.