


Case Report

Giant lipoma of breast: A rare case report

C. Saritha¹, B. V. Anuradha Devi², Imran Ali Mohammed¹,
Chandra Sekhar^{3*}, S. Sandhya Anil⁴, H. Sandhya Rani⁵

¹Assistant Professor, ²Post Graduate, ³Associate Professor, ⁴Professor, ⁵Professor and Head
Kakaitya Medical College, Warangal, Andhra Pradesh, India

*Corresponding author email: sekhar_pranathi@yahoo.co.in

	International Archives of Integrated Medicine, Vol. 3, Issue 1, January, 2016.	
	Copy right © 2016, IAIM, All Rights Reserved.	
	Available online at http://iaimjournal.com/	
	ISSN: 2394-0026 (P)	ISSN: 2394-0034 (O)
	Received on: 06-12-2015	Accepted on: 17-12-2015
	Source of support: Nil	Conflict of interest: None declared.
How to cite this article: C. Saritha, B. V. Anuradha Devi, Imran Ali Mohammed, Chandra Sekhar, S. Sandhya Anil, H. Sandhya Rani. Giant lipoma of breast: A rare case report. IAIM, 2016; 3(1): 116-118.		

Abstract

Lipomas are most common benign tumours derived from adipose tissue. Lipoma breast is somewhat difficult to diagnose clinically because of fatty consistency of breast. Lipoma breast measuring more than 10 cm in diameter or weighing more than 1 kg is called giant lipoma of breast which is infrequently observed because of rarity in size and location, with only very few case reports available in literature. Here, we have reported a case of this rare entity in 80 years old female who presented with complaints of painless lump in her right breast at our hospital.

Key words

Breast, Giant, Lipoma.

Introduction

Lipomas are one of the most common adipose tissue tumours having incidence of 16% of all mesenchymal tumors [1]. Lipomas are benign tumors of the breast [2]. They may be single or multiple and they are clinically asymptomatic. They usually developed as well circumscribed, encapsulated masses with a doughy feel that is freely mobile underneath the skin [2]. The diagnosis may be difficult due to normal adipose tissue of the breast. Giant lipomas are defined as lesions that have diameter of at least 10 cm or

weighs a minimum of 1000 gm [2-4]. Lipoma may cause asymmetry of the breast when grown up [5]. We have presented here an unusual case of giant breast lipoma in 80 years old female patient. The case presented is of interest because of age, size, and location.

Case report

80 years old female presented with slow growing painless lump in breast on right side since 2 years. On examination, lump was present in right upper and central quadrants, non tender,

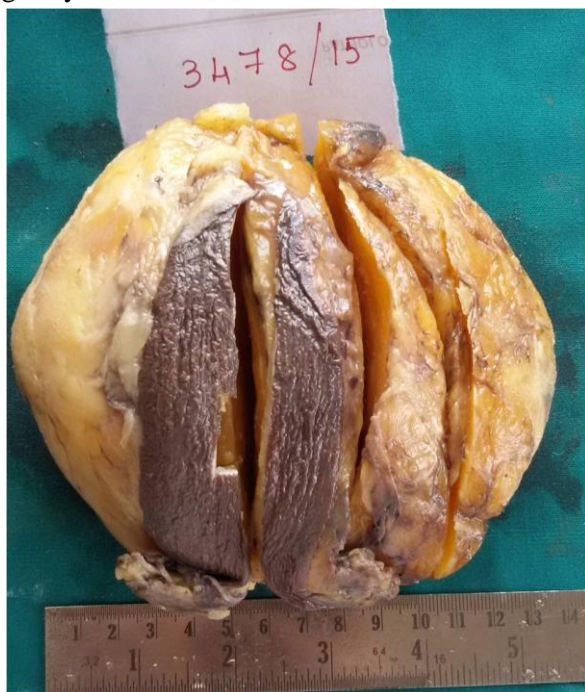mobile, not adherent to underlying fascia or muscle, skin above it was free and normal. No axillary lymph node involvement was present. USG was showing well circumscribed radiolucent avascular lesion. On fine needle aspiration cytology (FNAC) of right breast lesion revealed cellular smears consisting mainly fragments of mature adipose tissue, a few single fat cells suggesting the diagnosis of lipoma.

Mammography showed no other suspicious abnormality. Patient had undergone surgical excision and biopsy was sent to department of pathology for histopathological examination.

Gross features

We received well circumscribed skin covered soft tissue mass of dimensions 14x13x7 cm. Skin flap measuring 12x4 cm (**Figure - 1**). Cut section revealed soft, yellow, greasy homogenous tissue separated by fine fibrous trabeculae (**Figure - 2**).

Figure - 1: Gross: Breast lipoma - yellow, soft, greasy skin covered.



Microscopic features

Microscopy showed tumor composed of mature adipose tissue separated by thin fibrovascular septa. Individual cells were large and have

abundant empty cytoplasm and a small eccentric dark nucleus. No evidence of atypia was seen (**Figure - 3, 4**).

Figure - 2: Cut section showing soft, yellow, greasy, homogenous tissue separated by fine fibrous trabeculae.

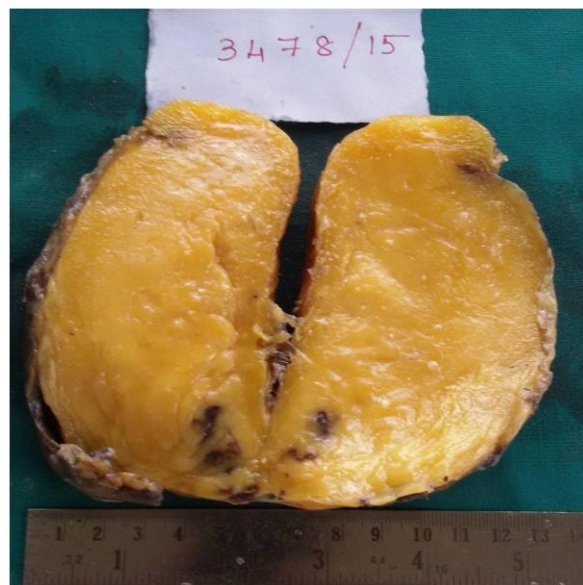
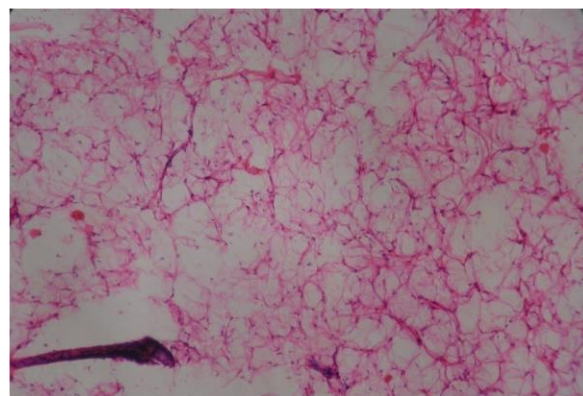


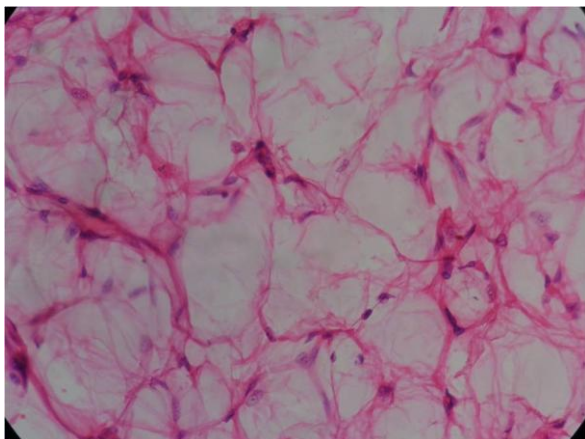
Figure - 3: Microphotograph shows mature adipocytes in sheets with thin intervening fibrovascular septa (100X, H and E stain).



Discussion

Lipomas are benign fatty tissue tumors [2]. They are usually solitary and may be difficult to diagnose in large or postmenopausal breasts [3]. Giant breast lipomas are usually long-standing and slow-growing, unilateral breast lesions. If large in size, they may give rise to a cosmetic problem or interfere with function as a result of the anatomical position [5].

Figure - 4: Micrograph shows cells with large abundant empty cytoplasm and a small eccentric dark nucleus (400X, H & E stain).



For a more accurate diagnosis, imaging techniques (ultrasonography, mammography) are helpful particularly in planning the best therapeutic strategy for the individual patient [5, 6]. In mammography, lipoma is a radiolucent nodule surrounded with a thin radiopaque capsule [7]. The ultrasound demonstrates elliptical, lobulated, homogeneous, hyperechoic thin capsulated solid mass with an echogenicity similar to that of normal fat [7, 8]. Breast lipomas may be misdiagnosed as carcinomas, fibroadenomas, phyllodes tumours and duct papillomas. It should be mentioned that “pseudo” lipomas, hamartomas (adenolipomas), angioliipomas, angiomyoliipomas, atypical lipomatous tumours and liposarcomas can mimic lipomas [8]. Sometimes it is difficult to diagnose and biopsy may be required [7]. Each of these tumor has characteristic histological features which helps to arrive at a correct diagnosis.

The lipomas may present as hard, fixed masses due to the post-traumatic fat necrosis [5]. The definitive diagnosis of these patients is crucial [7]. Thus, a detailed history and imaging techniques are required for these patients [8]. In our case, lipoma has been described as a well circumscribed radiolucent avascular lesion in USG and excisional biopsy was performed which revealed tumour tissue composed of mature adipose tissue separated by thin

fibrovascular septa, No evidence of atypia seen conforming the diagnosis of lipoma. If nuclear atypia is present in the tumour, extensive sampling should be performed to exclude liposarcoma. Management of giant breast lipomas often requires surgical intervention for cosmetic reasons or to alleviate the symptoms of discomfort and heaviness [9].

Conclusion

In conclusion, lipomas of the breast are benign tumors with a very limited risk of malignant transformation; they are associated with an excellent prognosis after successful excision. Preoperative evaluation requires a careful diagnostic workup due to its similarity to other pathologies, especially those associated with breast asymmetry and benign hypertrophy.

References

1. Lanng C, Eriksen BO, Hoffmann J. Lipoma of the breast: a diagnostic dilemma. *Breast*, 2004; 13: 408-11.
2. Sanchez MR, et al. Giant lipoma: case report and review of the literature. *J Am Acad Dermatol.*, 1993; 28(2 Pt 1): 266-8.
3. Schmidt J, et al. Giant lipoma of the breast. *Breast J*, 2009; 15(1): 107-8.
4. Lerman R, et al. Giant mammary lipoma. *Breast J*, 2002; 8(5): 307-8.
5. Li YF, et al. Giant lipoma of the breast: a case report and review of the literature. *Clin Breast Cancer*, 2011; 11(6): 420-2.
6. Hawary MB, et al. Giant breast tumors. *Ann Saudi Med.*, 1999; 19(2): 174-6.
7. Muttarak M, Chaiwun B. Imaging of giant breast masses with pathological correlation. *Singapore Med J*, 2004; 45: 132-139.
8. Pui MH, Movson IJ. Fatty tissue breast lesions. *Clin Imag*, 2003; 27: 150-155.
9. Citgez B., Akgün I, Ferhatoğlu F., Kartal A., Akçakaya A. Case Report: Giant Lipoma of the Breast. *Breast case*, 2012; 1: 20-22.