

Original Research Article

A comparative study of oral manifestations of HIV among pediatric patients

Neerav Dutta¹, Vinay Kumar Gupta², Rakshith Shetty¹, Ankit Roy³, Gaurav Dani⁴, Vijayendra Pandey^{5*}

¹Senior Lecturer, Department of Oral Pathology, Vananchal Dental College and Hospital, Garhwa, Jharkhand, India


²Senior Lecturer, Department of Prosthodontics, Vananchal Dental College and Hospital, Garhwa, Jharkhand, India

³Senior Lecturer, Department of OMR, Vananchal Dental College and Hospital, Garhwa, Jharkhand, India

⁴PG Student, Department of Oral Pathology, Maitri College of Dentistry and Research Centre, Chhattisgarh, India

⁵Reader, Department of Periodontology, Vananchal Dental College and Hospital, Garhwa, Jharkhand, India

*Corresponding author email: drvijayendrapandey@yahoo.com

	International Archives of Integrated Medicine, Vol. 3, Issue 5, May, 2016.	
	Copy right © 2016, IAIM, All Rights Reserved.	
	Available online at http://iaimjournal.com/	
	ISSN: 2394-0026 (P)	ISSN: 2394-0034 (O)
	Received on: 17-04-2016	Accepted on: 25-04-2016
	Source of support: Nil	Conflict of interest: None declared.
How to cite this article: Dutta N, Gupta VK, Shetty R, Roy A, Dani G, Pandey V. A comparative study of oral manifestations of HIV among pediatric patients. IAIM, 2016; 3(5): 46-52.		

Abstract

Introduction: The HIV pandemic has become a human, social as well as economic disaster, with far reaching inferences for individuals, communities and countries. The distribution of some of the specific oral manifestations is reported to differ between adults and children. Thus, the present study was carried to compare the oral manifestations in HIV positive children and HIV negative children.

Materials and methods: The present study comprised a total of 90 subjects, divided into 3 groups, 30 HIV positive pediatric patients with HAART, 30 HIV positive pediatric patients without HAART and 30 healthy controls (HIV negative patients). The present study was conducted in the ART centre in Ranchi, Chattisgarh, India. The details to be taken from these children for subsequent analysis include age, CD4+ T cell count and oral lesions. Chi- square test was used to compare the lesions with P-value of 0.05 or less was considered for statistical significance and a P-value of 0.02 or less was considered for statistical highly significance.

Results: Statistical analysis showed that patients with low CD4+ T cell counts (Group IA) had more number of lesions when compared to the patients with higher CD4 T cell count (Group IB).

According to individual lesion percentage distribution, it was observed that except hyperpigmentation most of the other lesions were more prevalent in group II than in group I. Mucocele was seen in group III and was not seen in group I and II. Dental caries was prevalent in all the three groups.

Conclusion: HIV infected patients receiving HAART, had a significantly lower prevalence of oral lesion as compared to patients without HAART therapy.

Key words

AIDS, Candidiasis, Dental caries, Oral manifestations.

Introduction

The HIV pandemic has become a human, social as well as economic disaster, with far reaching inferences for individuals, communities and countries. Of the 40 million people estimated to be infected with HIV by the end of 2004, children accounted for over 3 million of the total population. The progression of the disease is faster and more severe in children due to their developmental stage and to the immaturity of their immune system [1]. HIV transmission in children occurs mainly through vertical transmission (mother to child). The risk of transmission by an infected mother occurring before or during birth without medical intervention is around 15-20%. Breast feeding by an infected mother increases the risk by 5-20% to a total of 20-45%. In a study conducted in Brazil vertical transmission was seen in 97.5% in children. Studies in India have reported that vertical transmission is seen in 51 to 83% of children [2].

Oral manifestations are among the earliest and most important indicators of HIV infection [2, 3]. Oral lesions are features of HIV infection and are well described in the literature in adults and earlier studies have concurred with the findings from developed countries that oral lesions are diagnostic of HIV infection and that they are useful in monitoring HIV disease progression. Oral lesions in pediatric HIV infection are characteristic of the disease process and though, similar to adults, certain lesions are typical in the pediatric population [4]. The distribution of some of the specific oral manifestations is reported to differ between adults and children [3]. Thus, the present study was carried to compare the oral

manifestations in HIV positive children and HIV negative children.

Materials and methods

The present study comprised a total of 90 subjects, divided into 3 groups, 30 HIV positive pediatric patients with HAART, 30 HIV positive pediatric patients without HAART and 30 healthy controls (HIV negative patients). The present study was conducted in the ART centre in Ranchi, Chattisgarh, India. The subjects were categorized as follows:

Group - I: Comprised of 30 HIV positive children receiving HAART for a minimum of 3 months. This group is further divided into two subgroups based on CD4+ T cell count cells:

Group - IA: Comprised of HIV positive children with CD4+ T cell count less than 350 per cubic mm.

Group - IB: Comprised of HIV positive children with CD4+ T cell count more than 350 per cubic mm.

Group - II: Comprised of 30 HIV positive children without HAART and who came to the ART centre for first time without previous history of anti – retroviral therapy.

Group - III: Comprised of 30 HIV negative children studying in a government school.

The subjects included in this study were randomly selected from the ART centre, Ranchi. Study was approved by the institutional ethical committee and written consent was obtained from the parents of the children selected for the study. Patients were assured to keep their identity confidential. These children were selected from same age group of 2 years to 13 years and same

socioeconomic status. The details to be taken from these children for subsequent analysis include age, CD4+ T cell count and oral lesions. Patients were interviewed, examined orally and current and previous oral manifestations were categorized and were recorded. The extra-oral and perioral tissues were examined first, followed by the intra-oral tissues, for changes in size, colour and shape of anatomical areas as well as for clinical signs and lesions. The oral lesions associated with HIV infection were diagnosed based on their clinical presentation and where multiple sites were involved, all sites were documented. Chi-square test was used to compare the lesions with P-value of 0.05 or less was considered for statistical significance and a P-value of 0.02 or less was considered for statistical highly significance.

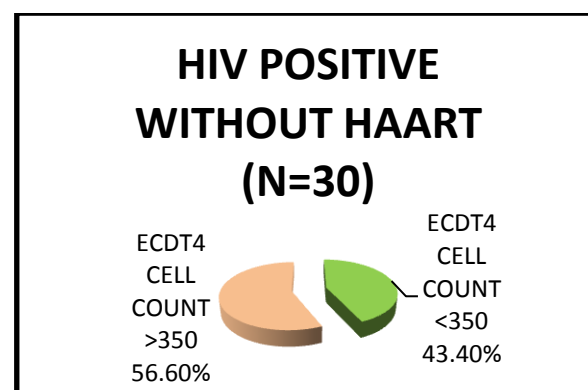
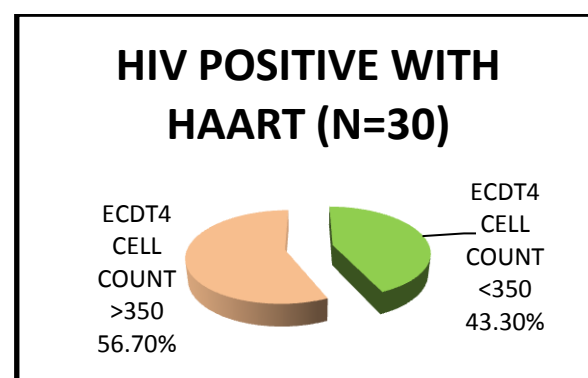
Results

The total sample of 30 children in Group I were divided into two groups (Group IA and Group IB) based on their CD4+ T cell count at the time of oral examination. Group IA included patients with CD4+ T cell count less than 350 per cubic mm. Group IB included patients with CD4+ T cell count more than 350 per cubic mm. We found that 43.30% of these children were having CD4+ T cell count less than 350 per cubic mm and 56.70% of these children were having CD4+ T cell count more than 350 per cubic mm. In group II, it was included HIV +ve pediatric patients who were currently not undergoing HAART therapy children, it was found that 43.40% of these children were having CD4+ T cell count less than 350 per cubic mm and 56.60% of these children were having CD4+ T cell count more than 350 per cubic mm (**Graph - 1**).

Statistical analysis was done using Fisher's Chi-square test and probability value (*P* value) was obtained for all the lesions divided into two groups based on their CD4+ T cell count. Statistical analysis showed that patients with low CD4+ T cell counts (Group IA) had more number of lesions when compared to the patients

with higher CD4 T cell count (Group IB). According to individual lesion percentage distribution, it was observed that except hyperpigmentation most of the other lesions where more prevalent in group II than in group I. Mucocele was seen in group III and was not seen in group I and II. Dental caries was prevalent in all the three groups. (**Table - 1, Graph - 2**).

Graph - 1: Percentage distribution of CD4 count cell among group I and group II.



Oral manifestations of children in Group II (HIV +ve without HAART) were compared to that of Group III (HIV -ve Control group). The manifestations that were observed in Group II were taken into consideration for comparing the two groups. Candidiasis, angular chelitis, ulcerative stomatitis, cervical lymphadenopathy, parotid gland enlargement and dental caries where statistically highly significant. Mucocele was not observed in HIV +ve children. Viral infection and gingivitis/periodontitis were more in group II and were statistically significant. Whereas other lesions where more in group II but where statistically not significant (**Table - 2**).

Graph - 2: Percentage distribution of oral manifestations among the study group.

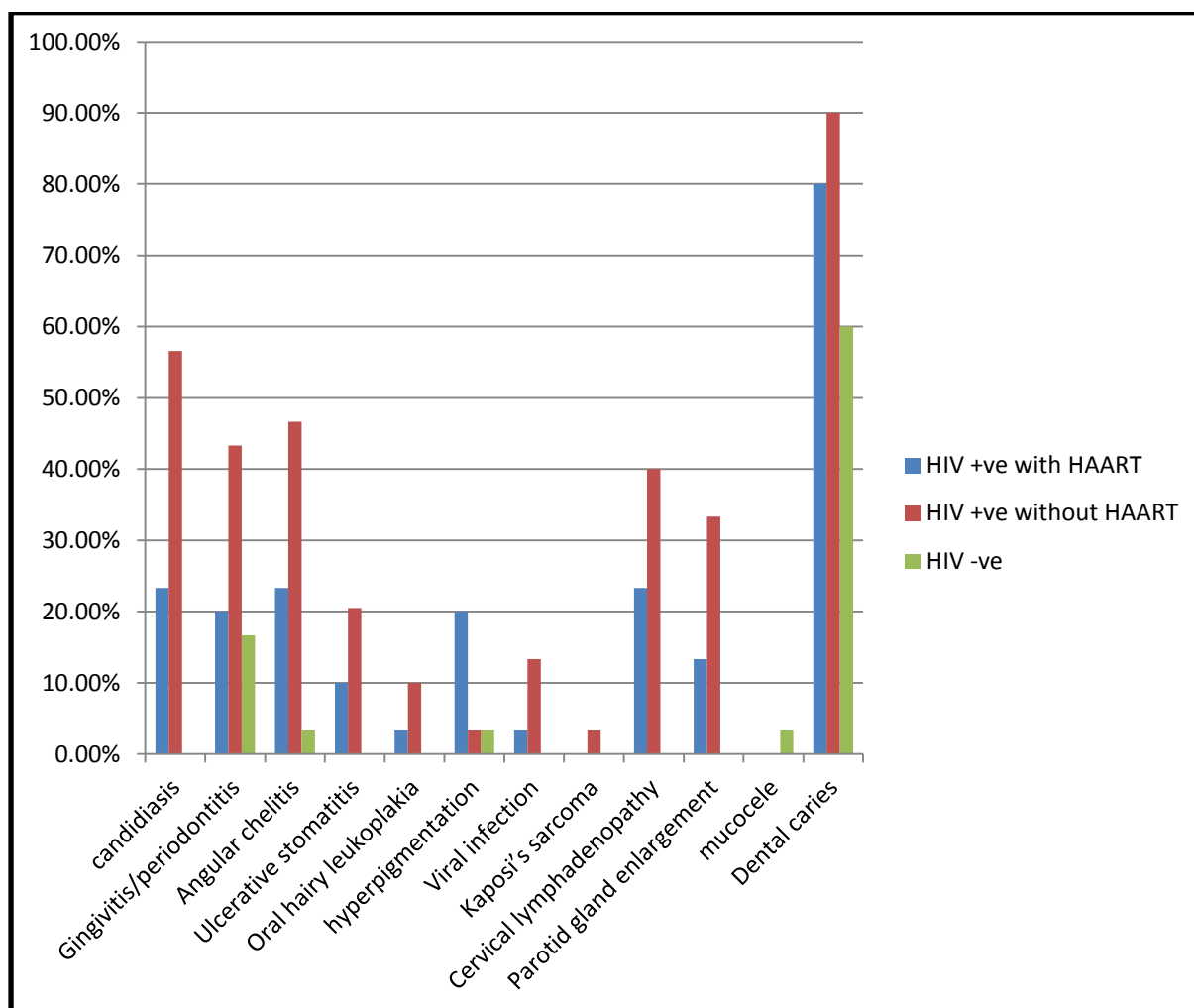


Table - 1: Oral manifestation percentage distribution in all three groups.

Name of disease	HIV positive with HAART N=30	HIV positive without HAART	HIV negative patient (Control group)
Candidiasis	23.30%	56.60%	0
Gingivitis/periodontitis	20%	43%	16.66%
Angular chelitis	23.30%	46.66%	3.33%
Ulcerative stomatitis	10%	21%	0
Oral hairy leukoplakia	3.33%	10.00%	0
Hyperpigmentation	20%	3.33%	3.33%
Viral infection	3.33%	13.33%	0
Kaposi's sarcoma		3.33%	0
Cervical lymphadenopathy	23.30%	40.00%	0
Parotid gland enlargement	13.33%	33.33%	0
Mucocele			3.33%
Dental caries	80%	90%	60%

Table - 2: Comparing incidence of oral lesion with HIV positive without HAART (group2) and HIV negative (group 3) with chi square value, p value and inference.

Name of disease	HIV positive without HAART n=30	HIV negative patient (Control group) n=30	Chi Sqr Value	'P' value	Significance
Candidiasis	56.6%	0	23.72	0.0001	Highly Significant
Gingivitis/periodontitis	43.3%	16.66%	5.08	0.024	Significant
Angular cheilitis	46.66%	3.33%	15.02	0.0001	Highly Significant
Ulcerative stomatitis	20.51%	0	9.23	0.002	Highly Significant
Oral hairy leukoplakia	10%	0	3.16	0.07	NS
Hyperpigmentation	3.33%	3.33%	0	1	NS
Viral infection	13.33%	0	4.29	0.038	Significant
Kaposi's sarcoma	3.33%	0	1.02	0.31	NS
Cervical lymphadenopathy	40%	0	15	0.0001	Highly Significant
Parotid gland enlargement	33.3%	0	12	0.0005	Highly Significant
Mucocele	0	3.33%	1.02	0.312	NS
Dental caries	90%	60%	7.2	0.007	Highly Significant

Discussion

The prevalence of oral manifestations in HIV infected patients tends to vary from country to country. Previous studies, in Africa, showed a wide range of prevalence rates from 1.5% up to 94%. However, in HIV-infected children, the prevalence of oral manifestations in developed countries has been reported to be as high as 72%. Comparable studies in children from developing countries, including Africa, indicated variations in the occurrence of oral manifestations, for example 61% in Brazil, 55% in Romania, 49% in Thailand and 63% in South Africa [5].

The oral manifestations of candidiasis and hairy leukoplakia in particular are clinical predictors of acquired immunodeficiency syndrome (AIDS) progression and are usually associated with CD4+ T lymphocyte cell count < 200 cells/ μ l of blood and high viral load levels in patients [5].

The present study found that about 43% patients were having CD4+ T cell count more than 350 per cubic mm and about 56.70% were having CD4+ T cell count less than 350 per cubic mm.

The classification system for pediatric HIV disease is different from that of adults. It is based on immune categories, which change according to the age of the child, and on different clinical categories as per **Table - 3** [6].

Classification of orofacial lesions in HIV-infected children has been based on the likelihood of a lesion's being associated with HIV disease [6].

Oral lesions in HIV/AIDS indicate the progress of disease process and therefore, have prognostic significance. The risk factors that influence the development of such oral manifestations include, low CD4+ T cell count, xerostomia and lack of

HAART. Opportunistic infections like oral candidiasis and herpetic viral infections are the commonly observed infections in children [2].

Table - 3: Revised classification system for pediatric HIV disease based on CD4 cell count and percentage [6].

Immune category	< 12 months CD4 cell/mm ³ %	1-5 years CD4 cell/mm ³ %	6-12 years CD4 cell/mm ³
Category 1: No suppression	>1500	>1000	>500
Category 2: Moderate suppression	750-1499	500-999	200-499
Category 3: Severe suppression	<750	<500	<200

The present study found that candidiasis, angular cheilitis, ulcerative stomatitis were more prevalent among HIV patients. Rwenyonyi CM, et al. [5] assessed factors influencing the distribution of oral manifestations in HIV/AIDS-infected children and reported that cervical lymphadenopathy, oral candidiasis and gingivitis were the most common soft tissue oral lesions: 60.8%, 28.3% and 19.0%, respectively.

Adebola AR, et al. [1] conducted a study to assess oral manifestation of HIV/AIDS infections in paediatric Nigerian patients and found that oral lesions occurred in 61.9% of the children with oral candidiasis being the most common lesion followed by the angular cheilitis.

Barasch A, et al. [7] compared oral soft tissue manifestations in HIV-positive and HIV negative children and found that HIV-positive children had significantly more oral soft tissue lesions than their HIV-negative peers. In particular, the prevalence of candidiasis, linear gingival erythema and median rhomboid glossitis were high and only candidiasis was associated with a low CD4 count.

Candidiasis is one of the most common mucocutaneous manifestations of HIV infection in children and its incidence is estimated to range between 20%-72%. It has been suggested in several studies it is a marker of rapid disease progression and death. It is more commonly seen with low CD4+Tcells or symptomatic HIV disease [8].

Early diagnosis is necessary for initiating highly active antiretroviral therapy (HAART), which also spares the babies from the toxicity of the antiretroviral drugs in negative cases. Though all infants born to HIV-positive mothers are initially seropositive, only 13–40% develops HIV infection. The seropositive mothers passively transmit the anti-HIV antibodies to the neonates (by vertical and intrauterine transmission) and only one-third of these children are infected. So the criteria for diagnosis in children less than 18 months of age include positive results on two separate determinations (excluding cord blood) from one or more of the following tests, namely HIV culture, HIV-DNA PCR, and HIV-p24 Ag or meeting the criteria for AIDS diagnosis based on 1987 AIDS surveillance definition, i.e., >18 months of age who is HIV antibody positive by repeated enzyme immunoassay (EIA) and confirmatory test (western blot or immune fluorescence assay) or by meeting any of the above criteria [2].

Conclusion

In the current study, it was observed a high incidence of dental caries and candidiasis when compared to other lesions such as gingivitis, periodontitis, angular cheilitis, parotid gland enlargement, ulcer and other lesions. This might be attributed to the poor oral hygiene practices by these children coming from lower socioeconomic classes. The children as well as the caretakers in the current study were given adequate oral hygiene instructions and thus, oral lesions can decrease in HIV positive children

through proper oral hygiene practices. HIV infected patients receiving HAART, had a significantly lower prevalence of oral lesion as compared to patients without HAART therapy.

References

1. Adebola AR, Adeleke SI, Mukhtar M, Osunde OD, Akhiwu BI, Ladeinde A. Oral manifestation of HIV/AIDS infections in paediatric Nigerian patients. *Nigerian Medical Journal: Journal of the Nigeria Medical Association*, 2012; 53(3): 150-4.
2. Poonam SR, Srivastava G, Theruru K. Oral manifestation of human deficiency virus in children: An institutional study at highly active antiretroviral therapy centre in India. *J Oral maxillofacial pathology*, 2012; 16(2): 195-202.
3. Park K. Text book of preventive and social medicine, 21st edition, Banarsidas Bhanot Publishers, February, 2011.
4. Francisco J, Ramos-Gom, et al. Risk factors for HIV-related orofacial soft-tissue manifestations in children. *Pediatr Dent.*, 1996; 18: 121-26.
5. Rwenyonyi CM, et al. Oral manifestation in HIV/ AIDS in infected children. *Eur J Dent.*, 2011; 5: 291-298.
6. Glick M. Orofacial disorders in children with HIV disease. *Dent Clin N Am.*, 2005; 49: 259-71.
7. Barasch A, Safford MM, Catalanotto FA, Fine DH, Katz RV. Oral soft tissue manifestations in HIV-positive vs. HIV negative children from an inner city population: A two-year observational study. *Pediatric Dent.*, 2000; 22: 215-20.
8. Mendiratta V, Mittal S, Jain A, Chander R. Mucocutaneous manifestations in children with human immunodeficiency virus infection. *Indian J Dermatol Venereol Leprol.*, 2010; 76: 458-66.