

Case Series


Acute superior mesentric vessel thrombosis with bowel ischemia – Case series

S. Krishnabharath¹, S. Mathan Sankar^{2*}

¹Senior Resident, ²Post Graduate Resident,

Department of General Surgery, Govt. Stanley Medical College, Chennai, Tamil Nadu, India

*Corresponding author email: mathansank@gmail.com

	International Archives of Integrated Medicine, Vol. 3, Issue 8, August, 2016.	
	Copy right © 2016, IAIM, All Rights Reserved.	
	Available online at http://iaimjournal.com/	
	ISSN: 2394-0026 (P)	ISSN: 2394-0034 (O)
	Received on: 11-07-2016	Accepted on: 20-07-2016
	Source of support: Nil	Conflict of interest: None declared.
How to cite this article: S. Krishnabharath, S. Mathan Sankar. Acute superior mesentric vessel thrombosis with bowel ischemia – Case series. IAIM, 2016; 3(8): 258-265.		

Abstract

Background: Acute mesenteric ischemia consists of the sudden, partial or complete, interruption of the blood flow in superior or inferior mesenteric vessels that result in intestinal ischemia. The incidence was exponentially increasing with age and no difference has been observed between sexes.

Aim: The Aim of this case series was to highlight clinical presentation, the difficulty in diagnosis and importance of early intervention and the prognosis of superior mesentric vessel thrombosis with bowel ischemia. This article presented a case series of intestinal infarction through obstruction of superior mesenteric vessels – three cases of acute mesenteric artery thrombosis, two case of acute mesenteric vein thrombosis.

Materials and methods:

The materials for this case series was collected from patients diagnosed and admitted as acute superior mesentric vessel thrombosis in various surgical units in Department of General Surgery, Govt. Stanley Medical College, Chennai. All 5 cases have been analyzed for this study during period of 6 months from January 2016 to June 2016. All Cases with superior mesentric vessels thrombosis were included. No exclusion criteria.

Results: This case series consisted of 5 cases, three cases of acute mesenteric artery thrombosis and two case of acute mesenteric vein thrombosis. In this case series, superior mesentric artery thrombosis was more common with male preponderance. 4 out of 5 cases were male in which Superior mesenteric artery was more common when compared to vein thrombosis. Out of 5 cases, 2 cases were asymptomatic with mild abdominal discomfort. Most common complaints of 5 cases were sudden onset of abdominal pain with or without vomiting. Abdominal distension/ Constipation were not seen in all cases. Out of 5 cases, 4 patients were on favorable follow up in which 2 cases had been diagnosed very early who had less post-operative stay and no complications after surgery. 2 cases developed post op complications. 1 case had deceased because of late presentation. This case series

presentation draws to attention that timely diagnosis and appropriate surgery with resection and immediate postoperative heparinization and proper follow up with anti coagulant the morbidity and mortality is averted.

Conclusion: The diagnosis of AMI is difficult and mostly delayed resulting in irreversible bowel ischemia which requires emergency intervention. Mortality and morbidity for AMI remains high, and in patients requiring extensive bowel resection the survival rate was low. As AMI mostly affects the elderly population physicians have to be aware of the possibility of this condition when facing the elderly patient even with mild sudden onset of abdominal pain complaints. An interdisciplinary collaboration is must, since patients are not initially evaluated by surgeons.

Key words

Acute Mesenteric Ischemia (AMI), CT angiogram, Gangrene, Ostomy, Heparin.

Introduction

Acute mesenteric ischemia consists of the sudden, partial or complete, interruption of the blood flow in superior or inferior mesenteric vessels that result in intestinal ischemia. The incidence was exponentially increasing with age and no difference has been observed between sexes [1]. Despite the major progresses in the diagnostic tools and treatment in the past years, due to the low rate of clinical suspicion, the late presentation at the hospital, the advanced age of the patients and the present co-morbidities, the mortality rate is still estimated to be 40-70% [2]. In this article, we presented 5 cases of AMI that have been classified according to the physiopathologic mechanisms of their production, three cases of acute mesenteric artery thrombosis, two case of acute mesenteric vein thrombosis.

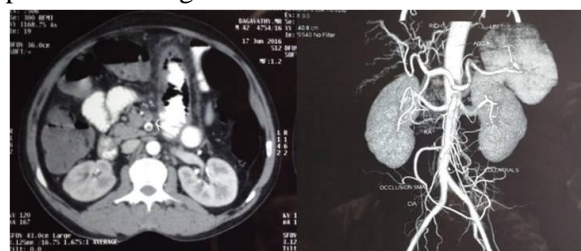
Case series

Case - 1: SMA thrombosis with uncommon presentation

A 50 year-old man presented to the OPD with sudden onset of mild upper abdominal pain for 4 days with no symptoms of vomiting, abdominal distension and constipation. No significant past history. On the clinical examination the patient was cooperative, had a normal orientation in time and place vitals stable, general examination was normal. Abdominal examination was normal. P/R examination was normal. All blood investigations results were normal including ECG, coagulation prolife and Chest X-ray.

Upper GI scopy was normal. CECT abdomen/pelvis and CT angio was taken in view of suspected sudden onset of abdominal pain which showed small ischemic segment of proximal jejunum with SMA thrombosis (**Figure - 1**). Since patients vitals was stable and with no symptoms, patient was planned for emergency D LAP procedure to inspect bowel. On D lap a segment of ischemic jejunum bowel was noted. Then laprotomy was performed ischemic gangrene of proximal jejunum noted (**Figure - 2**) then resection anastomosis was done (**Figure - 3**). Post op heparin was started. Post-operative period was uneventful. Orals started later patient is doing well with anticoagulants and follow up.

Figure - 1: CECT abdomen/ pelvis and CT angio picture showing SMA thrombosis.



Case - 2: SMA thrombosis.

A 53 year male presented with known history of significant CAD/AF on irregular medications, presented to the casualty with epigastric pain for 10 days prior admission which was accompanied by mild distension. The clinical examination revealed an abdomen was mildly distended with localized guarding present in epigastric region and umbilical region P/R normal. Laboratory

results were normal except electrolyte imbalance. The abdominal CECT and CT angio was suggestive for an AMI caused by the obstruction of the SMA with ischemic segment involving terminal ileum (**Figure - 4**).

Figure – 2: Gangreneous segment of proximal jejunum.

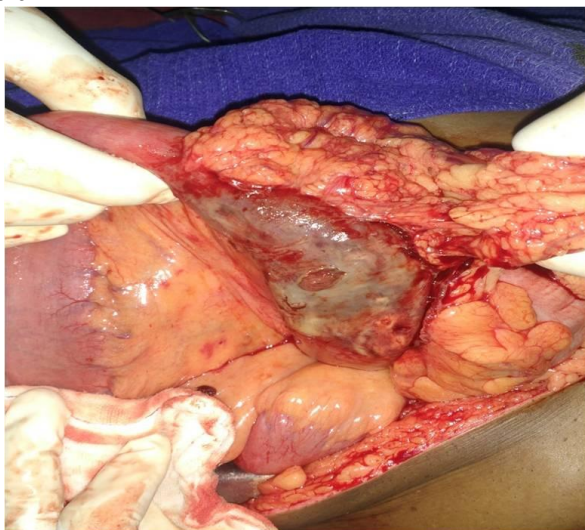


Figure – 3: After anastomosis of jejunum.

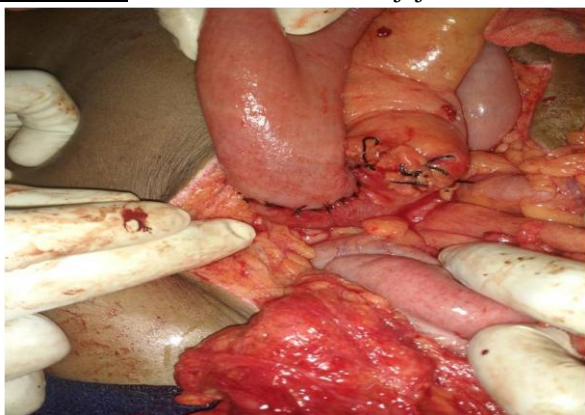
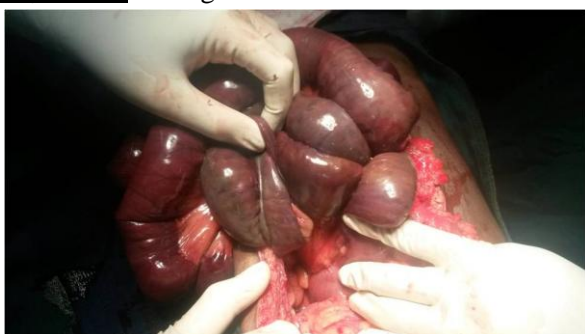
Figure – 4: Gangrened distal ileum.



The diagnosis of an acute surgical abdomen has been stated, and the decision of an emergency

intervention has been made. During the exploration of the abdominal cavity the distal ileum about last 60 cm was gangrened, with absence of peristalsis. Segmental resection has been performed and anastomosis was done. The post-operative was favorable with less post-operative stay, the patient received treatment to maintain his electrolyte balance, antibiotics, anticoagulant and pain relievers. Patient is on favorable follow up.

Case - 3: SMV thrombosis.

A 41 year old male labourer was presented in the emergency department with sudden onset of abdominal pain generalized in nature of 2 days duration associated with vomiting 2-3 episodes. The abdominal pain was continuous with no other symptoms of malena, hematemesis or diarrhea. Past medical history of DVT of the left leg 1 year back and was started on oral anticoagulant drugs. He had stopped the anticoagulant drug since 2 weeks back on his own and following which developed the abdominal pain. No history of other abdominal surgeries. Patient was a chronic smoker and alcoholic. Physical examination Per abdomen revealed generalized abdominal distension with guarding, rigidity and absent bowel sounds. Per rectal examination revealed an empty rectum. Laboratory investigations were normal. The initial X-ray of abdomen showed dilated small bowel loops with no air under the diaphragm. USG of abdomen and pelvis demonstrated free fluid. CE CT abdomen and pelvis showed ischemic changes in the jejunal bowel loops in the form of wall thickening and loss of contrast uptake. No contrast filling noted in the SMV. Diagnosis of SMV thrombosis with bowel gangrene and peritonitis was made (**Figure - 5**). The patient was managed with IV fluids, IV broad spectrum antibiotics and explorative laparotomy. Operative findings noted were gangrenous bowel segments of jejunum and ileum of 100 cm length (**Figure - 6**). Large bowel was normal. Hemorrhagic peritoneal fluid of about 700 ml was present. Resection of gangrenous bowel segments with Laprostomy (**Figure - 7**) kept checking bowel viability and

jejunostomy was done. Postoperatively was given therapeutic unfractionated heparin. Later after 72 hours laprostomy was closed. Postoperatively patient developed Respiratory infections which managed accordingly and heparin was administered for 2 weeks and continued with warfarin. After 10 weeks patient was readmitted for jejunoileal anastomosis. Patient was on follow up.

Figure – 5: Contrast CT of Abdomen shows central lucency of the SMV.

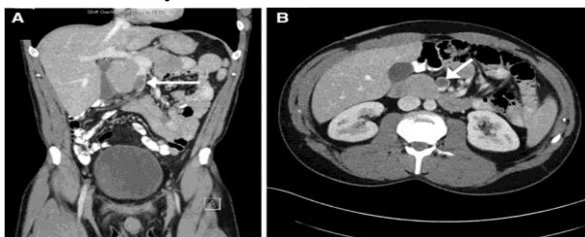
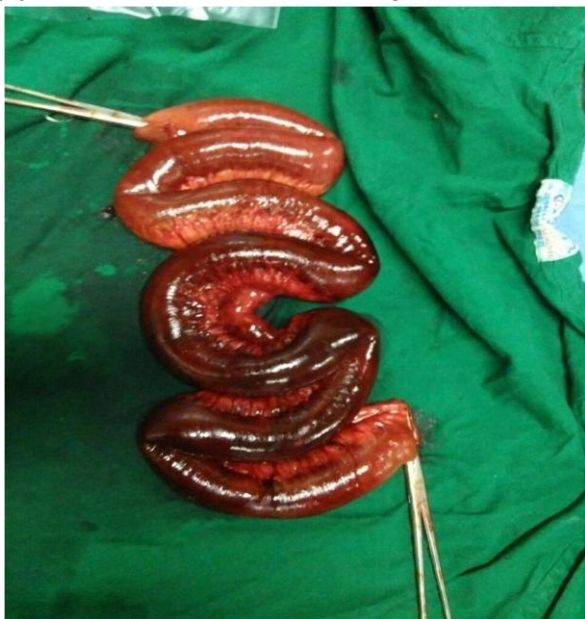
Figure – 6: Gangrenous bowel segments of jejunum and ileum of 100 cm length.

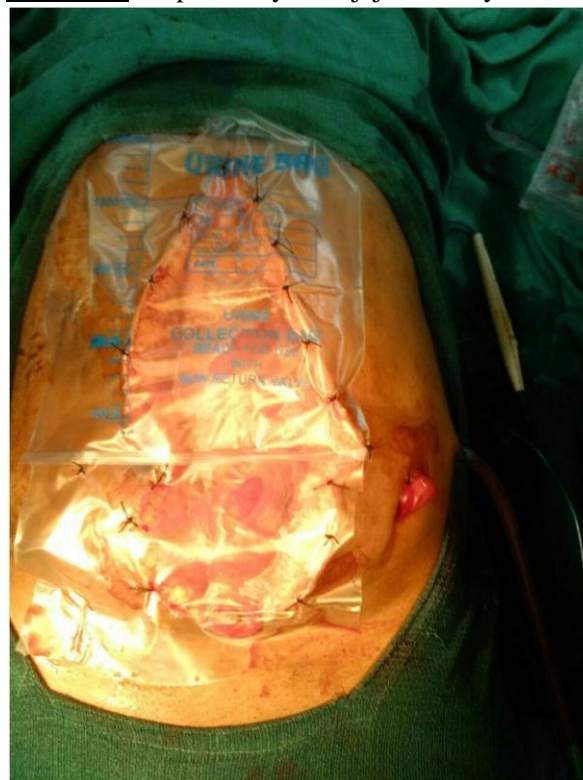

Case - 4: SMV thrombosis.

A 55 year old male presented to casualty with abdominal pain for 1 day which was sudden in onset and suddenly collapsed in home, patient was known case of stroke and CAD on irregular medications, history of constipation (+). History similar episode 20 days back where patient had mild abdominal pain only for which he was admitted and evaluated CT angio was taken showed SMV thrombosis with ? mild ischemia of

jejunum (**Figure - 8**), patient was managed conservatively, discharged later with anticoagulants. Suddenly 30 mins prior to admission patient was collapsed, patient was intubated outside and referred to our institution. GCS was E2M2VT on examination, Tachycardia, Hypotension (+). Abdomen was rigid. P/R was empty. USG of abdomen and pelvis demonstrated free fluid. Hemorrhagic fluid was aspirated under image guidance. Patient was started on i.v. fluids and antibiotics and resuscitated well. An attempt to restore the patient's volemic and electrolytic equilibrium has been made, but it was unsuccessful. 2 hour after presentation the patient succumbs.

Figure - 7: Laprostomy with jejunostomy.



Case – 5: SMA thrombosis.

51 year male presented to casualty with severe abdominal pain for 2 days and vomiting. No history of malena or hemetemesis. Patient was known case of hypertension on regular medications. On examination was conscious oriented tachycardia (+). On abdominal exam guarding and rigidity present all over abdomen. P/R was empty. USG showed free fluid. CECT

was taken showed ischemic bowel changes from proximal jejunum to distal ileum with SMA thrombosis with free fluid. Exploratory laprotomy performed gangrenous bowel 20cm from DJ flexure to Terminal Ileum (**Figure - 9**) seen with 1.5 litres of free fluid present. Resection was done and jejunostomy was kept and distal loop ileostomy also kept. Post-operatively patient developed electrolyte imbalance and wound infection, after correcting electrolyte imbalance and patient nutritional status, wound healed with good antibiotics and secondary suturing. Jejunostomy was functional well. Patient was doing well on follow up with anticoagulants. Patient is waiting for ostomy revision closure.

Figure - 8: Acute thrombosis in Superior mesenteric vein.

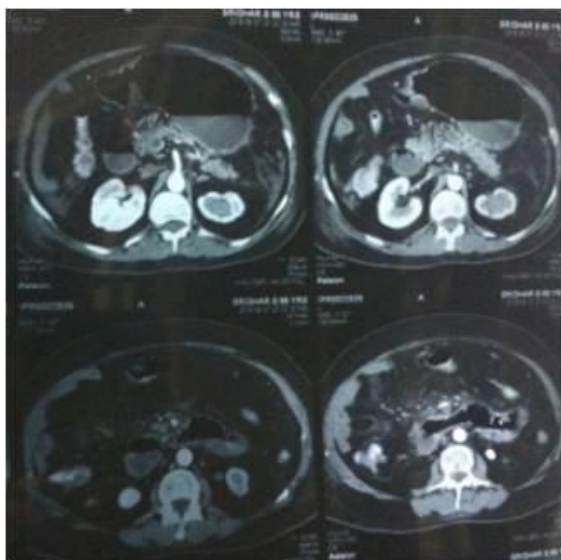



Figure - 9: Gangrene of almost entire small bowel.



Comparative synthesis of all 5 cases was as per **Table - 1**.

Discussion

Acute mesenteric vessel thrombosis is most frequently caused by the migration of thrombus to the systemic circulation, due any underlying cardiac problems or any procoagulant state [6-8].

Most emboli to the mesentery lodge in the SMA. Its wide angle of origin and parallel course to the aorta makes it likely to lodge there [9]. Mostly large thrombi will lodge in within first 8 cm of the vessel, mostly leaving the proximal jejunum [10]. Emboli typically lodge in the proximal SMA, distal to the origin of the middle colic artery. A high index of suspicion is needed in the setting of a compatible history and physical examination. Many of the signs and symptoms of AMI are easily misdiagnosed as pancreatitis, cholecystitis, appendicitis, diverticulitis, and bowel obstruction.

Generally, the pain has a sudden onset, and after transmural involvement of the bowel it becomes diffuse radiating towards the flanks. Superficial palpation typically shows no guarding, with a few signs of distension. The abdomen is resonant mostly, except when liquid appears in the peritoneum [3]. Among the many serum parameters that have been investigated there is no specific marker to diagnose AMI. Increased D-dimer levels are equally nonspecific [11]. CT angiography is gold standard in the diagnosis of AMI (sensitivity 0.96, specificity 0.94) [12, 13]. Regular CT examination can show a bowel thickening, dilated intestines filled with liquid and other localized infarctions of the bowel [14, 15].

In this case series, 3 out of 5 cases presented with risk factor like CAD and DVT. CAD was found in two cases and DVT in one case. 2 cases were without any risk factor. It's worth that in Case 1, the patient was asymptomatic and all investigation was normal except CECT abdomen which showed ischemia of bowel. Early

intervention with D lap played an important role in the recovery of this patient in spite of patient was being asymptomatic.

Table – 1: Comparative synthesis of all 5 cases.

	Case 1	Case 2	Case 3	Case 4	Case 5
	49 years old male	53 years old female	41 years old male	55 years old male	51 years old male
	SMA	SMA	SMV	SMV	SMA
Clinical picture	Asymptomatic	Epigastric pain, Abdominal distension	Abdominal pain, Vomiting	Abdominal pain, shock	Severe abdominal pain, vomiting
Risk factor	Nil	CAD/AF	DVT	CAD/Stroke	SHT
Abdominal X-ray	Normal	Hydroaeric levels	Dilated small bowel loop	Not taken	Hydroaeric levels
CT angiography	Small ischemic segment of proximal jejunum with SMA thrombosis	SMA with ischemic segment involving terminal ileum	Ischemic changes in the jejunum bowel with SMV thrombosis	? Gangrene of proximal jejunum with SMV thrombosis	Ischemic changes from proximal jejunum to distal ileum, SMA thrombosis
Surgery	Resection and Anastomosis	Resection and Anastomosis	Jejunostomy followed by anastomosis later	---	Jejunostomy on follow up
Evolution	Favorable follow up	Favorable on follow up	Favorable on follow up, post-operative respiratory infection	Death after 2 hours admission	Favorable follow up, post-operative wound infection/ electrolyte imbalance
Post-operative stay	12	11	26	---	30

In Case 2, CAD and AMI were plausible in the presence of atrial fibrillation. Patient was with severe abdominal pain and distension. The clinical presentation of Case 1 is atypical to that of case2. But resection anastomosis was done in both cases in single settings with good post op care and heparin patient improved very well. Both patients discharged within 2weeks post operatively with anticoagulants.

In case 3 patients had history of DVT presented with acute abdominal pain. The patient was managed with IV fluids, IV broad spectrum antibiotics and explorative laparotomy done.

Resection of gangrenous bowel segments with jejunostomy and laprostomy was done. Post-operatively was given therapeutic unfractionated heparin. With increased post-operative day stay and 2nd surgery for closure abdomen and 3rd surgery for closure of ostomy. Patient developed postop respiratory infections and nutritional status was also affected. After good antibiotics patient improved and discharged on follow up.

And in Case 5 patient was managed same with resection. jejunostomy was kept and distal loop ileostomy also kept. Post operatively patient developed electrolyte imbalance due to

jejunostomy and wound infection, later after correcting electrolyte imbalance and patient nutritional status, wound healed with good antibiotics and secondary suturing.

In case 4, repeat CT was contraindicated because of the hemodynamic instability and renal insufficiency of the patient. Patient resuscitated well but died within 2 hours of admission. This indicates late intervention always poor prognosis.

The patient presented with symptoms suggestive of an intestinal angina 1 month before the admission to previous hospital, with paroxysmic pain after meals, with time, the frequency and intensity of the anginous episodes tend to increase, preparing the territory for an AMI.

Since D lap was not performed to this case at early presentation to inspect bowel viability after being diagnosed as SMV thrombosis, this factor also adds to mortality. D lap is must for asymptomatic patients (As done in case 1) to intervene early and to give prompt treatment.

If patient clinical condition was good/minimal Gangrene was present then we can for resection anastomosis in single setting with good post-operative care and anticoagulants will prevent post op complications and hospital stay is reduced. If suspected gangrene later after surgery in post-operative we can directly go for 2nd diagnostic laparoscopy. No need for 2nd laparotomy. Mostly single branch involvement won't undergo to form full blown gangrene postoperatively as seen case 1 and 2.

If patient clinical condition was bad or gangrene was involving large segment bowel means ostomy can be done. As seen in case 3 and 5. But post operative complications was likely occur in these kind of patients because of long post op stay and revision surgery

The diagnostic laparoscopy will be very useful for the critical/atypical patients, for whom there was a suspicion of mesenteric intestinal infarction. As seen in Case 1.

In AMI due to SMA thrombosis, survival is approximately 50% when the diagnosis occurs within 24 hours after the onset of symptoms, but it drops to <30% when the diagnosis is delayed [16].

Besides the need to diagnose acute mesenteric ischemia early, before infarction, knowledge of the clinical risk factors that predict prognosis enables emergency physicians to use more aggressive resuscitation and treatment strategies to improve outcomes [17].

Conclusion

The diagnostic laparoscopy will be very useful for the critical/atypical patients, for whom there was a suspicion of acute mesenteric intestinal ischemia. The diagnosis of AMI is difficult and mostly delayed resulting in irreversible bowel ischemia which requires emergency intervention. Mortality and Morbidity for AMI remains high, and in patients requiring extensive bowel resection the survival rate was low. As AMI mostly affects the elderly population physicians have to be aware of the possibility of this condition when facing the elderly patient even with mild sudden onset of abdominal pain complaints. An interdisciplinary collaboration is must, since patients are not initially evaluated by surgeons.

References

1. Acosta S. Epidemiology of mesenteric vascular disease: clinical implications. *Semin Vasc Surg.*, 2010; 23(1): 4-8.
2. Kassahun WT, Schulz T, Richter O, Hauss J. Unchanged high mortality rates from acute occlusive intestinal ischemia: six year review. *Langenbecks Arch Surg.*, 2008; 393(2): 163-71.
3. Oldenburg WA, Lau LL, Rodenberg TJ, Edmonds HJ, Burger CD. Acute mesenteric ischemia: a clinical review. *Arch Intern Med.*, 2004; 164(10): 1054-62.
4. Brandt LJ, Boley SJ. Intestinal ischaemia. In: Feldman, M, Friedman,

- LS, Sleisenger, MH, eds. Sleisenger and Fordtran's Gastrointestinal and Liver Disease, Philadelphia, PA, USA: WB Saunders, 2002, p. 2321-40.
5. Grendell J.H., Ockner R.K. Mesenteric venous thrombosis. *Gastroenterology*, 1982; 82(2): 358-72.
 6. Basavanagowdappa H, Babu S, Kumar P, Nanaiah MM, Jeevan HR. Superior mesenteric artery embolism. *J Assoc Physicians India*, 2008; 56: 907-9.
 7. Martinez JP, Hogan GJ. Mesenteric ischemia. *Emerg Med Clin North Am.*, 2004; 22: 909-28.
 8. Ruotolo RA, Evans SRT. Mesenteric ischemia in the elderly. *Clin Geriatr Med.*, 1999; 15: 527-57.
 9. Menke J, Luthje L, Kastrup A, Larsen J. Thromboembolism in atrial fibrillation. *Am J Cardiol.*, 2010; 105(4): 502-10.
 10. Renner P, Kienle K, Dahlke MH, Heiss P, Pfister K, Stroszczynski C, et al. Intestinal ischemia: current treatment concepts. *Langenbecks Arch Surg.*, 2011; 396(1): 3-11.
 11. Akyildiz H, Akcan A, Oztürk A, Sozuer E, Kucuk C, Karahan I. The correlation of the D-dimer test and biphasic computed tomography with mesenteric computed tomography angiography in the diagnosis of acute mesenteric ischemia. *Am J Surg.*, 2009; 197: 429-33.
 12. Wyers MC. Acute mesenteric ischemia: diagnostic approach and surgical treatment. *Semin Vasc Surg.*, 2010; 23: 9-20.
 13. Kirkpatrick ID, Kroeker MA, Greenberg HM. Biphasic CT with mesenteric CT angiography in the evaluation of acute mesenteric ischemia: initial experience. *Radiology*, 2003; 229: 91-8.
 14. Mazzei MA, Mazzei FG, Marrelli D, Imbriaco G, Guerrini S, Vindigni C, et al. Computed tomographic evaluation of mesentery: diagnostic value in acute mesenteric ischemia. *J Comput Assist Tomogr.*, 2012; 36(1): 1-7.
 15. Fock CM, Kullnig P, Ranner G, Beaufort-Spontin F, Schmidt F. Mesenteric arterial embolism-the value of emergency CT in diagnostic procedure. *Eur J Radiol.*, 1994; 18(1): 12-4.
 16. Boley SJ, Feinstein FR, Sammartano R, Brandt LJ, Sprayregen S. New concepts in the management of emboli of the superior mesenteric artery. *Surg Gynecol Obstet.*, 1981; 153(4): 561-69.
 17. Huang HH, Chang YC, Yen DH, Kao WF, Chen JD, Wang LM, et al. Clinical factors and outcomes in patients with acute mesenteric ischemia in the emergency department. *J Chin Med Assoc.*, 2005; 68(7): 299-306.
 18. Kaley RN, Boley SJ. Acute mesenteric ischemia: an aggressive diagnostic and therapeutic approach: 1991 Roussel Lecture. *Can J Surg.*, 1992; 35: 613-23.
 19. Rajkovic Z, Zelic Z, Papes D, Cizmek K, Arslani N. Synchronous celiac axis and superior mesenteric artery embolism. *Vasa.*, 2011; 40(6): 495-8.
 20. Stone JR, Wilkins LR. Acute mesenteric ischemia. *Tech Vasc Interv Radiol.*, 2015; 18(1): 24-30.