

## Case Report


# S-Beta Thalassemia leading to avascular necrosis of left hip joint in a young male - A rare case report

Shubhi Saxena<sup>1\*</sup>, Nishant Saxena<sup>1</sup>, R.M Jaiswal<sup>2</sup>

<sup>1</sup>PG Student, <sup>2</sup>Associate Professor,

Department of Pathology, Mahatma Gandhi University of medical science and technology, Sitapura, Jaipur, Rajasthan, India

\*Corresponding author email: [shoobheee@gmail.com](mailto:shoobheee@gmail.com)

	International Archives of Integrated Medicine, Vol. 3, Issue 8, August, 2016. Copy right © 2016, IAIM, All Rights Reserved. Available online at <a href="http://iaimjournal.com/">http://iaimjournal.com/</a>
	ISSN: 2394-0026 (P)                      ISSN: 2394-0034 (O)
	Received on: 09-07-2016                      Accepted on: 22-07-2016 Source of support: Nil                      Conflict of interest: None declared.
<b>How to cite this article:</b> Saxena S, Saxena N, Jaiswal RM. S-Beta Thalassemia leading to avascular necrosis of left hip joint in a young male - A rare case report. IAIM, 2016; 3(8): 278-282.	

## Abstract

Sickle beta thalassemia is a disorder which represents the double heterozygous state for the Hb-S and the beta-thalassemia genes. The clinical and hematological manifestations of sickle beta thalassemia are highly variable due to existence of two types of genes, beta<sup>0</sup> thalassemia gene and beta<sup>+</sup> gene. Beta<sup>0</sup> gene leads to complete absence of Hb-A levels, whereas beta<sup>+</sup> gene leads to production of Hb-A levels 10-30%. This disorder is diagnosed by levels of HbS, HbA2 and HbF in Hemoglobin Electrophoresis. We are presenting one such young male patient with features of Sickle Beta<sup>+</sup> thalassemia who presented with anemia, fatigue and joint pain with characteristic features of avascular necrosis of left hip joint in X-Ray and MRI. For the etiological diagnosis further investigation in the form of capillary haemoglobin electrophoresis and for final confirmation genetic analysis by PCR is done.

## Key words

Anemia, Avascular necrosis, Sickle-Beta Thalassemia, Hb Electrophoresis, Genetic analysis by PCR.

## Introduction

Hemoglobinopathies are a group of genetic disorders of hemoglobin [1]. Thalassemia and other structural hemoglobinopathies are the major genetic disorders prevalent in certain parts

of the world including India. The general incidence of thalassemia trait and sickle cell Hemoglobinopathy in India varies between 3-17% and 1-44% respectively [2] but, because of consanguinity, caste and area endogamy, some

communities show a very high incidence, making the disease a major public health problem in our country [2, 3]. Inherited disorders of hemoglobin synthesis are an important cause of morbidity and mortality worldwide. They place a large burden on the patients, their families and even the community. They can be managed by expensive bone marrow transplantation, which is always not possible in a developing country like ours. Population screening, genetic counseling and prenatal diagnosis can prevent these genetic disorders; as it has been a success in countries like Greece, Cyprus and Italy.

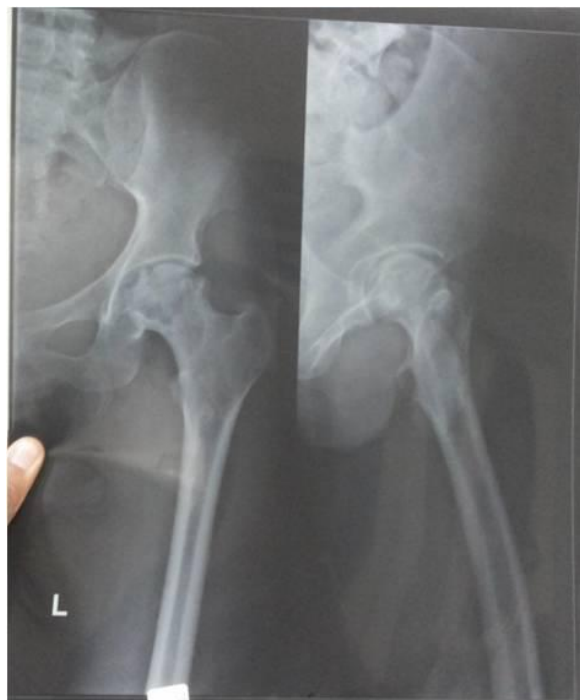Population screening has identified the prevalence of Beta-thalassemia carrier status as high as 17% in certain communities in India [4]. The prevalence of hemoglobinopathies varies in different parts of India. Sickle beta thalassemia prevalence was found to be relatively low in contrast to the prevalence of beta-thalassemia trait in various studies [5-11]. Sickle beta thalassemia is a disorder which represents the double heterozygous state for the Hb-S and the beta-thalassemia genes. The overall prevalence of sickle beta thalassemia in India is 0.02% with highest prevalence in Bangalore (0.06%). The overall prevalence of beta-thalassemia trait in India is (2.78%) with highest prevalence in Kolkata (3.64%). The overall prevalence of HbS trait in India is 0.70% with highest prevalence in Vadodara (2.94%). The overall prevalence of HbE trait in India is 3.63% with highest prevalence of 23.9% in Dibrugarh [5]. This case is presented due to uncommon occurrence of sickle beta<sup>+</sup> thalassemia.

### **Case report**

A 40 year old Hindu male from Jaipur, Rajasthan presented with acute onset of intermittent fever with chills, rigor, backache, fatigue and joint pain since one week. He did not have any other complaints suggestive of cardiac, respiratory and haematological disorders. There is no significant family or personal history. On examination, he was conscious, oriented and mildly icteric with mild pallor. Other systemic examinations were

unremarkable. Radiological findings on X-Ray showed avascular necrosis in left femoral head (**Figure - 1**) and MRI showed avascular necrosis in left hip joint, stage 4.

**Figure – 1:** X-Ray showing avascular necrosis of left femoral head.



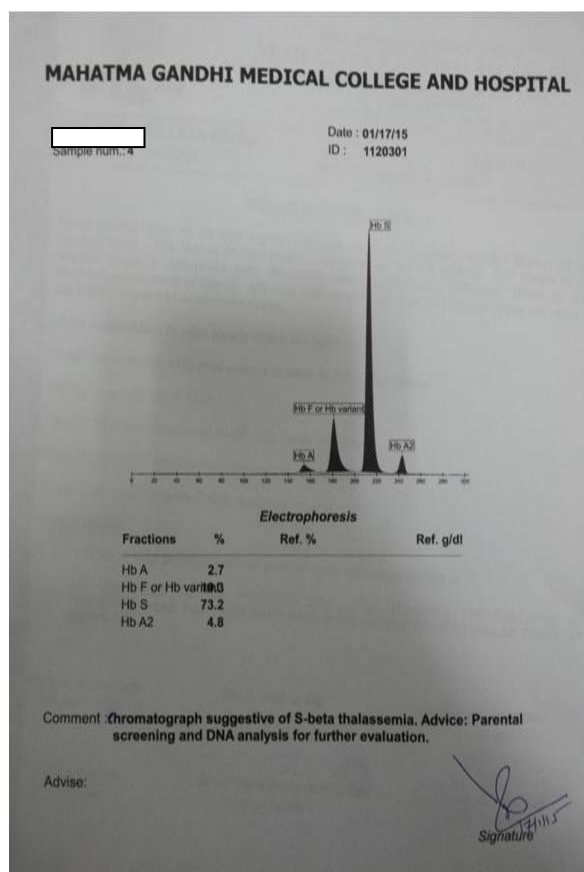
His complete blood count revealed anaemia Hb 10.1 gm%, RBC's 5.14 million/cubic mm, MCV 56.1 fl, MCH 19.3, MCHC 34.5, RDW 21.6% with normal total count and platelets with ESR 10 mm/hr. Peripheral smear showed microcytic hypochromic RBC's with moderate anisopoikilocytosis in the form of target cells, elliptocytes, sickle cell, few fragmented RBC'S with polychromatic cells. Reticulocyte count was 4.7%.

His biochemical investigations showed normal liver fuction and renal function test. Serological tests like coomb's test, ELISA for HIV, dengue and malaria card test, VDRL, ASLO Titre and RF were all negative. Immunological test like Quantitative CRP is 22.6mg/dl and is positive.

In view of anaemia and sickle cells in peripheral smear, patient was investigated further and hence sickling test and capillary Haemoglobin

electrophoresis was ordered. Sickling test came positive with Hb electrophoresis revealing HbS 73.2%, HbA level 2.7%, HbA2 4.8%, HbF 19.3% suggestive of S-Beta Thalassemia (Figure - 2). We further advised him for parental screening and DNA analysis.

**Figure – 2:** Capillary Hemoglobin Electrophoresis shows HbS 73.2%, HbA2 4.8%, HbF 19.3% and HbA 2.7% suggestive of S-Beta Thalassemia.



On Allele specific Polymerase chain reaction codon 6 (A-T) mutant allele detected which confirms sickle cell carrier and IVS 1-5 (G-C) mutant allele detected which confirm a Beta thalassemia minor. The genetic study confirms the patient is compound heterozygous for Beta thalassemia and sickle cell and is likely to suffer from disease.

## Discussion

Differentiation of sickle cell anaemia and some of the sickle beta thalassemia syndromes has to be done carefully due to close similarity of

symptoms and laboratory features. Mean corpuscular volume (MCV) may be normal or low in all thalassemia syndromes. Symptoms and blood picture of patients with HbS beta<sup>0</sup> thalassemia are similar to those of homozygous sickle cell disease (HbSS) with microcytosis, marked hypochromia, target cells and sickle cells in the peripheral smear and can be differentiated only by Hb electrophoresis. The Hemoglobin Electrophoresis pattern of the sickle-beta<sup>0</sup> thalassemia consists almost totally of HbS with a mild increase in HbF and HbA2 and absent HbA [12]. They also have similar symptoms of homozygous sickle cell disease like frequent painful vasoocclusive crises, hand-foot syndrome and aseptic necrosis of bone with autosplenectomy. The beta<sup>+</sup> thalassemia type consists of Hb-S, along with 10-30% of Hb-A and a mild increase in Hb-F and Hb-A2. Patients with HbS beta<sup>+</sup> thalassemia are characterized by mild anemia associated with moderate splenomegaly, in contrast to autosplenectomy of sickle cell anaemia [13]. Sickle beta<sup>+</sup> thalassemia patients have Hb-S composition of approximately 60–70%, Hb-A 25%, and an elevated level of Hb-A2 [14]. They also can have few symptoms like occasional vasoocclusive crises and aseptic necrosis of the bone. Patients with HbS-HPFH (HbS and Hereditary Persistence of Fetal Hemoglobin) are asymptomatic and not anemic. HbA2 levels are elevated above 3.5% in HbS beta thalassemia and are low or normal in patients with HbS-HPFH. HbF level in patients with HPFH are generally more than 20% [15]. Thus a careful evaluation of symptoms and signs along with Hb electrophoresis helps us to distinguish between various sickle beta thalassemia syndromes.

## Conclusion

Hemoglobinopathies are a group of genetic disorders of hemoglobin in which there is abnormal production or structure of the hemoglobin molecule. These hereditary disorders are major public health problem in many parts of the world including India. The clinical spectrum of the disorders varies from asymptomatic

conditions to serious disorders like thalassemia major that requires regular blood transfusions and extensive medical care. As per World Health Organization (WHO) report, around 7% of the global population carries an abnormal haemoglobin gene [16].

As in this 24 year old male who presented with pain in left pelvic girdle and fatigue was diagnosed by MRI as a case of avascular necrosis of left hip joint stage 4 and was further investigated for the etiology by haematological parameters which suggested S-Beta thalassemia. Further DNA analysis was done which revealed codon 6 (A-T) mutant allele which confirms sickle cell carrier and IVS 1-5 (G-C) mutant allele which confirms Beta thalassemia minor. The genetic study confirms the patient is compound heterozygous for Beta thalassemia and sickle cell and is likely to suffer from disease.

## References

1. S.S. Ambekar, M.A. Phadke, et al. Patterns of haemoglobinopathies in Western Maharashtra. *Indian Pediatrics*, 2001; 38: 530-534.
2. Balgir RS. The burden of hemoglobinopathies in India and the challenges ahead. *Curr Sci.*, 2000; 79: 1536-47.
3. Balgir RS. The general burden of hemoglobinopathies with special reference to community health in India and the challenges ahead. *Indian J Hemat Blood Transfusion*, 2002; 20: 2-7.
4. Vaz FE, Thakur CB, Banerjee MK, Gangal SG. Distribution of beta-Thalassemia Mutations in the Indian Population Referred to a Diagnostic Center. *Hemoglobin*, 2000; 24: 181-94.
5. D. Mohanty, R. B. Colah, A. C. Gorakshakar, R. Z. Patel, et al. Prevalence of  $\beta$  - thalassemia and other haemoglobinopathies in six cities in India: a multicentre study. *J Community Genet.*, 2013; 4(1): 33-42.
6. Jain BB, Roy RN, Ghosh S, Ghosh T, Banerjee U, Bhattacharya SK. Screening for thalassemia and other hemoglobinopathies in a tertiary care hospital of West Bengal: Implications for population screening. *Indian J Public Health*, 2012; 56: 297-300.
7. Balgir RS. Spectrum of hemoglobinopathies in the state of Orissa, India: A ten years cohort study. *JAPI*, 2005; 53: 1021-1026.
8. Chatterjee N, Mishra A, Soni R, Kulkarni H, Mantani M, Shrivastava M. Bayesian estimates of the prevalence of  $\beta$  thalassemia trait in voluntary blood donors of central India: a survey. *Hemoglobin*, 2010; 34: 548-560.
9. Chhotray GP, Dash BP, Ranjit M. Spectrum of hemoglobinopathies in Orissa, India. *Hemoglobin*, 2004; 28: 117-122.
10. Colah R, Thomas M, Mayekar P. Assessing the impact of screening & counseling high school children for beta thalassemia in India. *J Med Screen*, 2007; 14: 158.
11. Madan N, Sharma S, Sood S K, Colah R, Bhatia H M. Frequency of  $\beta$ -thalassemia trait and other hemoglobinopathies in northern and western India. *Indian J Hum Genet.*, 2010; 16: 16-25.
12. Frank Firkin. Disorders of Haemoglobin structure and Synthesis, De Gruchy's Clinical Hematology in Medical Practice, 5<sup>th</sup> edition, Blackwell Science Ltd., France, p. 140-151.
13. Winfred C. Wang. Sickle Cell Anemia and other Sickling Syndromes, Wintrobe's Clinical Hematology, 11<sup>th</sup> edition, Philadelphia. Lippincott Williams & Wilkams, p. 1294-1295.
14. David J Weatherall. The Thalassemias, William's textbook of haematology, 7<sup>th</sup> edition, McGraw Hill Companies, p. 698-99.
15. Angastiniotis M, Eleftheriou A, Galenello R, et al. Prevention of Thalassemia and other Haemoglobin

Saxena S, Saxena N, Jaiswal RM. S-Beta Thalassemia leading to avascular necrosis of left hip joint in a young male - A rare case report. IAIM, 2016; 3(8): 278-282.

Disorders: Volume 1, 2<sup>nd</sup> edition, Thalassaemia International Federation; 2013.

16. WHO. Management of Haemoglobin Disorders. Report of Joint WHO-TIF Meeting on the Management of Haemoglobin Disorders. Nicosia,

Cyprus, 16-18 November 2007. World Health Organization 2008: 1-2. Available from: [http://www.who.int/genomics/WHO TIF genetics](http://www.who.int/genomics/WHO_TIF_genetics).