

## Case Report


# Neonatal hiatal hernia on CPAP: A rare entity

Niraj Gupta<sup>1\*</sup>, Mohit Sahni<sup>2</sup>

<sup>1</sup>Fellow in Neonatology, <sup>2</sup>Head and Professor,

Department of Neonatology, Nirmal Hospital and Critical Care Centre, Surat, Gujarat, India

\*Corresponding author email: [nirajgupta1187@hotmail.com](mailto:nirajgupta1187@hotmail.com)

	International Archives of Integrated Medicine, Vol. 3, Issue 9, September, 2016. Copy right © 2016, IAIM, All Rights Reserved. Available online at <a href="http://iaimjournal.com/">http://iaimjournal.com/</a> ISSN: 2394-0026 (P) ISSN: 2394-0034 (O)
	Received on: 31-08-2016 Accepted on: 07-09-2016 Source of support: Nil Conflict of interest: None declared.
<b>How to cite this article:</b> Gupta N, Sahni M. Neonatal hiatal hernia on CPAP: A rare entity. IAIM, 2016; 3(9): 238-241.	

## Abstract

Herniation of the stomach through the esophageal hiatus can occur as a common Sliding hernia (Type 1) in which the gastro esophageal junction slides into the thorax, or Paraesophageal (Type 2) in which a portion of the stomach (usually the fundus) is insinuated next to the oesophagus inside the gastroesophageal junction in the hiatus. A combination of sliding and paraesophageal type (Type 3) is present in some patients. We have presented here a case report of a preterm baby who developed hiatal hernia while on CPAP on DOL 13. We are presenting this case due to rarity of its occurrence.

## Key words

Hernia, Neonate, Hiatal, CPAP.

## Introduction

The herniation of abdominal viscera into the thoracic cavity, Hiatus Hernia, is due to the disorder of gastroesophageal junction and is rarely seen in neonatal period [1, 2]. This entity may result in misdiagnosis such as congenital diaphragmatic hernia, eventration of diaphragm, lobar emphysema, pneumatocele, pneumothorax, pleural effusion and esophageal atresia [3, 4]. Rapid diagnosis and treatment is essential. It avoids lethal complications such as gastric dilatation, gangrene and perforation,

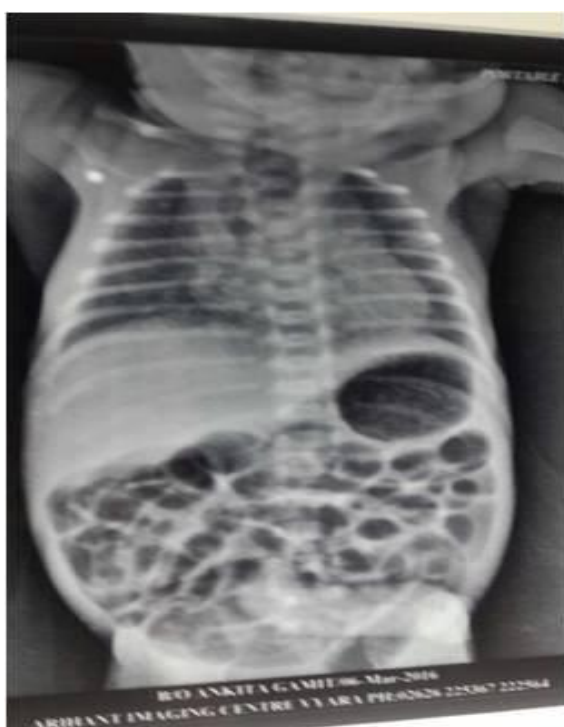which in turn may lead to cardiopulmonary arrest. We report a case of hiatal hernia in a neonate presenting on 13<sup>th</sup> DOL while the baby was on CPAP.

## Materials and methods

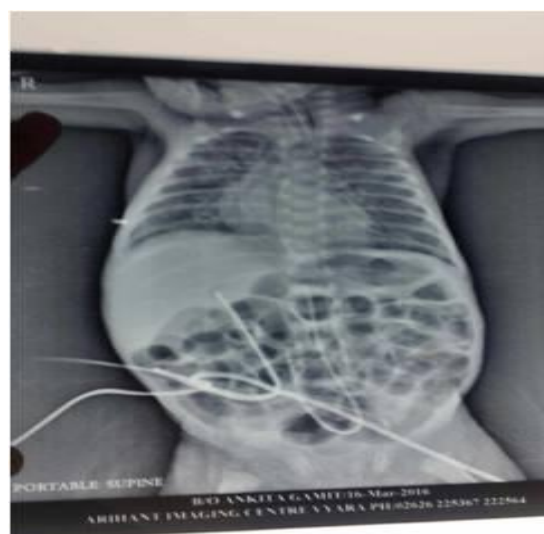A preterm 29+4 week female baby was born by vaginal delivery and the baby cried immediately at birth weight of 1.1 kg initial resuscitation in the form of oxygen was given to the baby. The baby was received with severe respiratory distress amounting to mechanical ventilation and

requiring dobutamine. X-ray was suggestive of HMD Grade II on the first X-ray with rest of the organ systems normal. 1 dose of surfactant was given to the baby. The baby was kept on ventilator and as the respiratory condition improved baby was shifted to CPAP on day of life 3. Initially trophic feedings were started and increased as the baby tolerated well. The baby developed features of NEC with increased gastric aspirates, abdominal distension, and increased respiratory distress. Feeds were held and the baby was kept on mechanical ventilation again. After a 5 day period of NBM the baby was started on minimal feeds and feeds gradually increased. As respiratory condition improved, baby was extubated to CPAP on DOL 10. Repeat X-ray was done on DOL 13 in view of increased oxygen requirements of the baby and increased distress baby was intubated and inotropes were started. X-ray was suggestive of herniation of abdominal viscera into the right hemithorax. Based on the X-ray the diagnosis of hiatal hernia with pneumonia was made. Surgery was planned but the baby developed severe cardio respiratory compromise and could not be revived despite efforts (Figure – 1, 2, 3).

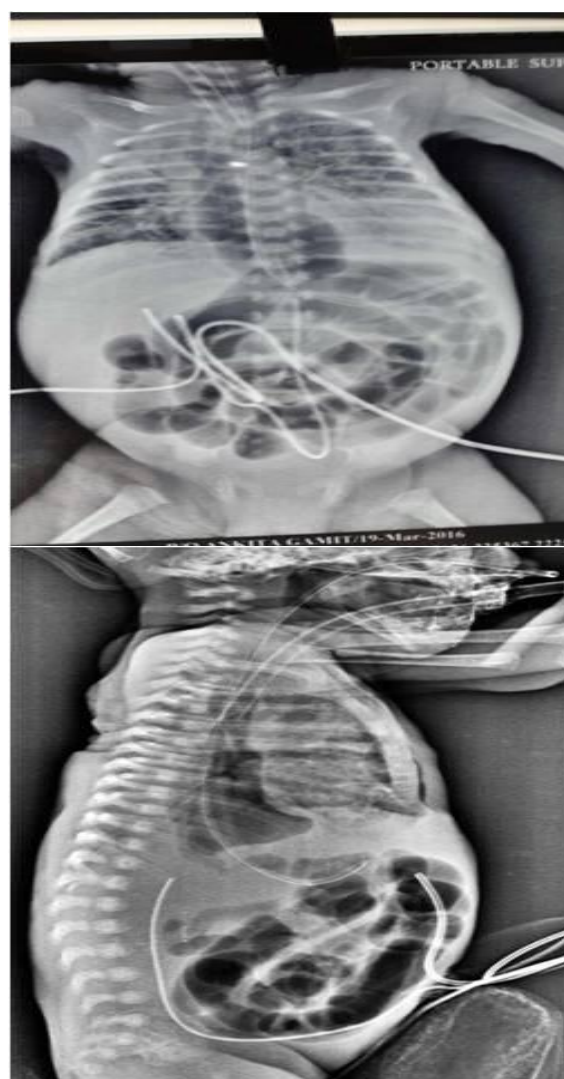
**Figure – 1:** Inital Xray of the baby DOL=1.



**Figure – 2:** X-ray after intubation DOL = 9.



**Figure - 3:** Herniation of abdominal viscera into the abdomen DOL=13.



## Discussion

Herniation of the stomach through the esophageal hiatus can occur as a common Sliding hernia (Type 1) in which the gastro esophageal junction slides into the thorax, or Paraesophageal (Type 2) in which a portion of the stomach (usually the fundus) is insinuated next to the oesophagus inside the gastroesophageal junction in the hiatus. A combination of sliding and paraesophageal type (Type 3) is present in some patients [5]. Type 1 is the most common type found most commonly in children as well as adults. Although a paraesophageal hernia is a rare entity it is more prone to incarceration, strangulation, complete gastric herniation with organoaxial volvulus (upside down stomach), and a perforation of herniated viscera [6, 7].

A hiatal hernia is considered as massive if more than one third of the stomach is located above the diaphragm [8]. It has been reported that massive hiatal hernias may occur due to progression of a paraesophageal hiatus hernia [9]. However massive hiatal hernia may also occur due to sliding hiatal hernia. However, massive hiatus hernia has been rarely reported in children [10, 11]. The main presenting features are respiratory distress, failure to thrive and poor feeding. Parida and Hall reported higher incidence of congenital anomalies in such children [12]. They can also be misdiagnosed as lobar pneumonia, pneumatocele, pneumothorax, pleural effusion or congenital diaphragmatic hernia.

Barium swallow examination, upper gastrointestinal endoscopy and computed tomography are routinely used to confirm the diagnosis of Hiatus hernia. Manometry, 24 hour pH monitoring and gastric scintigraphy are done to rule out the presence of gastroesophageal reflux. Chest radiographs may show opacity in the posterior mediastinum with or without an air-fluid level. Barium swallow will show three or more gastric folds above the diaphragm hiatus and a pouch of stomach more than two cm above the hiatus. On CT scan, the diaphragmatic crura are seen separated by more than 15mm and the

protrusion of hernia above the diaphragm hiatus. Medical management include use of antacids, H<sub>2</sub>-receptor antagonist and proton pump inhibitors and Nissen fundoplication is done in refractory cases.

Hiatal hernia although rare, should be considered in differential diagnosis of severe respiratory distress in a neonate as early intervention will be life saving.

## References

1. Anderson KD. Congenital diaphragmatic hernia. In: Welch KJ, Randolph JG, Ravitch Mm, Rome MC, editors. Paediatric Surgery 4<sup>th</sup> edition, Chicago: Year Book medical publishers; 1986, p. 599.
2. Senocak ME, Buyukpamukcu N, Hisconmez A. Massive hiatal hernia containing colon and stomach with organo-axial volvulus in a child. Turk J Pediatr., 1990; 32: 53-58.
3. Al-Arfaj AL, Khwaja MS, Upadhyaya P. Hiatal hernia in children. Eur J Surg., 1991; 157: 465-468.
4. Yadav K, Myers NA. Paraesophageal hernia in the neonatal period-another differential diagnosis of esophageal atresia. Pediatr Surg International, 1997; 12: 420-421.
5. Kliegman, et al. Hiatal Hernia. Seema Khan, Susan R Orenstein. Nelson Textbook of Pediatrics, 19<sup>th</sup> edition, Southeast asia, Elsevier, 2010; p. 1265.
6. Stiefel D, Willi UV, Sacher P, Schwobel MG, Stauffer UG. Pitfalls in therapy of upside-down stomach. Eur J Pediatr Surg., 2000; 10: 162-166.
7. Maruyama T, Fukue M, Imamura F, Nozue M. Incarcerated paraesophageal hernia associated with perforation of the fundus of the stomach: report of a case. Surg Today, 2001; 31: 454-457.
8. Pearson FG, Cooper JD, Ilves R, Todd TR, Jamieson WR. Massive hiatal hernia

- with incarceration: a report of 53 cases. *Ann Thorac Surg.*, 1983; 35: 45-51.
9. Geha AS, Massad MG, Snow NJ, Bau AE. A 32-year experience in 100 patients with giant paraesophageal hernia: the case for abdominal approach and selective and antireflux repair. *Surgery*, 2000; 128: 623-630.
  10. Arima T, Igarashi M, Shiraishi M, Nakamura T. Hiatal herniation of colon in an infant. *Int Surg.*, 1988; 73: 196-197.
  11. Maziak DE, Todd TR, Pearson FG. Massive hiatal hernia: Evaluation and surgical management. *J Thorac Cardiac vasc Surg.*, 1998; 115: 53-62.
  12. Parida SK, Kriss VM, Hall BD. Hiatal hernia in neonatal Marfan syndrome. *Am J Med Genet.*, 1997; 72: 156-158.