


Original Research Article

Efficacy of FNAC in early diagnosis of prostatic carcinoma

S. Dhanraj Reddy^{1*}, M. Sandhya Rani¹

¹Associate Professor, Department of Pathology, MNR Medical College and Hospital, Sangareddy, Medak, Telangana, India

*Corresponding author email: dhanrajreddy95@yahoo.com

	International Archives of Integrated Medicine, Vol. 3, Issue 10, October, 2016. Copy right © 2016, IAIM, All Rights Reserved. Available online at http://iaimjournal.com/	
	ISSN: 2394-0026 (P)	ISSN: 2394-0034 (O)
	Received on: 21-09-2016	Accepted on: 05-10-2016
Source of support: Nil		Conflict of interest: None declared.
How to cite this article: S. Dhanraj Reddy, M. Sandhya Rani. Efficacy of FNAC in early diagnosis of prostatic carcinoma. IAIM, 2016; 3(10): 100-104.		

Abstract

Background: Prostatic carcinoma is one of the most important causes of mortality in elderly men mainly because of the late detection despite of the fact that it is a potentially curable disease. Fine needle aspiration cytology (FNAC) is an easy to perform outpatient procedure requiring no expensive equipment or anesthesia.

Objectives: The present study was carried out in an attempt to evaluate the fine needle aspiration cytology in the diagnosis of carcinoma prostate.

Materials and methods: The present study was performed on 27 patients admitted in the surgical wards, with complaints suggestive of prostatic disease, in whom there was found to be a suspicion of malignancy of the prostate gland.

Results: Among 27 patients, 14 patients were diagnosed as prostatic malignancy on per rectal FNAC whereas, 19 patients were confirmed with prostatic cancer histologically. Out of 19 histologically confirmed cancer cases, 16 were also positive on FNAC i.e. 84.21% accuracy of FNAC in detecting prostatic malignancy.

Conclusion: Fine needle aspiration cytology is easily available and inexpensive procedure. It is a reliable method in the diagnosis of prostatic cancer. Its positive results are relatively more reliable than the negative ones. It is an effective method in follow up of the cancer cases.

Key words

Fine needle aspiration cytology (FNAC), Prostatic carcinoma, Giemsa or May Grunwald Giemsa stain (M.G.G.).

Introduction

Prostatic disease is one of the common problem of old age group and third most common cause of cancer death in males [1, 2]. The incidence of prostatic disease both carcinoma and nodular hyperplasia are increasing with the demographic shift to longevity in our country.

Initial diagnosis of prostate cancer can be done by digital rectal examination (DRE) and estimation of serum prostate specific antigen (PSA) level. Although prostatic cancer can be detected by DRE, the specificity of the examination is only 50 percent, which means that a biopsy is always necessary [3].

Carcinoma of prostate can be diagnosed definitively by biopsy either- open biopsy, punch biopsy, core needle biopsy, or fine needle aspiration biopsy (FNAB). The transrectal FNAC has been utilized extensively in Europe with excellent results [1, 4, 5].

FNAC can be utilized for early detection of recurrences of prostatic carcinoma. Transrectal FNA of prostate is an effective procedure and studies have shown that transrectal FNAC of prostate has a higher sensitivity than fine core needle biopsy [6, 7, 8]. With above facts, the present study was aimed to evaluate the efficacy of FNAC as an early diagnostic tool in detection of prostatic carcinoma.

Materials and methods

The present study has been performed on the patients, admitted in the surgical wards of MNR Medical College and Hospital, Sangareddy during 2013 to 2015 with complaints of prostatism, in whom there was found to be a suspicion of malignancy of the prostate gland, in the form of palpable nodule or area of induration, during digital per rectal examination.

Procedure

The patient was explained the whole procedure and its importance regarding management of patients' problems and advised to take a light

evening meal and a mild laxative. In the next morning, after passing the motion, the patient underwent digital per rectal examination to see whether the rectum was empty; if not so, an enema was given to him to cleanse the rectum. After that, patient was given a shot of injection gentamycin (80 mg. IM). Patient was positioned either in left lateral or in lithotomy position. The syringe and needle were wetted by aspirating one ml. of 0.90% saline, which was subsequently returned to its source. (It decreases the frequency of clotted samples).

Fixation and staining

Air-dried smeared slides were placed in 95% alcohol immediately for 24 hours (after proper labelling) for fixation. Slides were then stained by haematoxylin, Giemsa or May Grunwald Giemsa (M.G.G.) stain by standard technique. The findings of FNAC were later compared with the results of histopathological diagnosis. The material for which was obtained either by transurethral resection of prostate or by transrectal true-cut core needle biopsy.

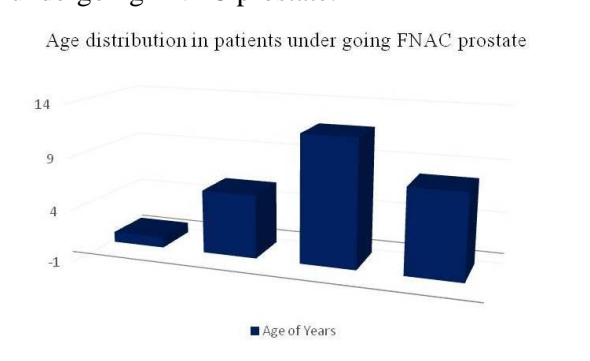
Results

The present study has been performed on 27 patients admitted in the surgical wards of MNR Medical College & Hospital, Sangareddy during 2013 to 2015, with complaints suggestive of prostatic disease, in whom there was found to be a suspicion of malignancy of the prostate gland, in the form of palpable nodule(s) or area(s) of induration, during digital perrectal examination. The age of patients varied from 55 years to 75 years (**Table – 1, Figure – 1**).

Table – 1: Presentation of patients among study groups.

Presented as	No. of cases	%
Urinary retention	6	22.22
Features of prostatism	12	44.45
With features of metastatic spread	-	0

Figure – 1: Age distribution in patients undergoing FNAC prostate.



Fourteen patients were diagnosed as cases of prostatic malignancy on perrectal FNAC and nineteen were having prostatic cancer. Out of 19 cases, procedure was repeated in 5 cases, while FNAC was either negative for malignant cells or could not provide sufficient material for diagnosis. Out of these 5 cases, 2 were detected to be having malignancy on repeat FNAC while 3 remained negative for malignant cells even after repeat FNAC. Out of 19 histologically cancer cases, 16 were also positive on FNAC i.e. 84.21% accuracy of FNAC in detecting prostatic malignancy (Table – 2 and Table – 3, Figure - 2).

Table – 2: Findings on routine blood investigation.

Investigation	No. of cases	%
Presented with raised serum acid phosphatase and serum alkaline phosphatase	0	0
Presented with raised serum urea (>40 mg %) and serum creatinine (>1.4 mg %)	2	7.4
Presented with haemoglobin level below 9.0 gm%	14	51.9
Presented with raised blood sugar level	0	0

Discussion

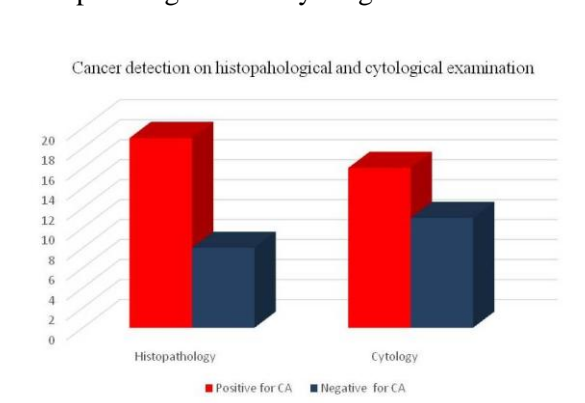
Among 27 patients, carcinoma prostate was suspected on digital per rectal examination, however morphological examination of the tissue

obtained by tru-cut needle biopsy revealed adenocarcinoma in only 19 patients, rest 8 were found to be suffering from various benign deceases which can mimic carcinoma. FNAC showed carcinoma only on 14 patients on initial attempt, in other 5 patients there was a very strong suspicion of malignancy on digital per rectal examination which was confirmed by trust needle biopsy. In these patients FNAC was repeated which revealed carcinoma in only 2 cases and in rest 3 malignancy could not be identified. Hence out of 27 cases, the cancer was detected in 16 cases by FNAC, that is, approximately 59.25% of cases were diagnosed as having cancer prostate in the present study.

Table – 3: Rates of detection of malignant prostate.

Incidence of prostate carcinoma diagnosed as true positive	59.25%
Incidence of prostate carcinoma diagnosed as false positive	0%
Incidence of prostate carcinoma diagnosed as false negative	15.79%
Accuracy of FNAC in detecting malignancy	84.21%

Figure – 2: Cancer Detection on Histopathological and Cytological Examination.



The incidence varied among various studies, but this can be due to the fact that different studies have been conducted in different geographical areas, in people with different criteria or cytological diagnosis used by differently pathologies and moreover, that few studies were carried randomly on all prostatic cases and other

were done on patients with a high clinical suspicion of cancer prostate, which can explain relatively high incidence of cancer prostate detected by FNAC in present study; besides in this small study, are included few follow up cases of cancer prostate, who contributed significantly in making the incidence of cancer detection higher (**Table - 4**). A study by Esposti PL, et al. found a good correlation between cytological findings and histological controls in 350 patients. Overall accuracy was 96% and 93% specificity for benign and 97% for cancer [9]. Similarly Melograna, et al. in 1982 reported confirmation of diagnosis occur 91% time, 96% with BPH, 77% with carcinoma and 100% with prostatitis [10].

Table – 4: Incidence of prostatic carcinoma diagnosed by FNAC in present study with previous study.

Name of the Author	No. of cases	Incidence of cancer detection
Esposti P.L., et al. [10]	1100	33%
Kline TS, et al. [1]	51	62.75%
Present study	27	59.25%

In the present study, incidence of false positive results was 15.7% that is, when FNAC was reported as positive for malignant cells, the histopathological examination also confirmed it, however in 3 out of 18 histopathologically proved cancer causes, no malignant cells could be detected on cytological examination. The

incidence of specificity of FNAC in various series is as per **Table - 5**.

From clinical point of view, the rate of false positive cytological diagnosis is of far greater significance than the failure to demonstrate carcinoma at first attempt. The diagnosis of any cancer by fine needle aspiration biopsy relies on three major criteria; cellularity, anaplasia and dysdifferentiation. In order to avoid a false positive diagnosis, carcinoma should be diagnosed only when all criteria of disease are met. There may be many reasons for false negative reports, like inadequacy of the specimen, missing of the tumour by operator in obtaining the specimen, borderline lesions (and so difficulty in interpretation) or cancer associated with fulminant prostatitis. Hence, if there is a strong clinical suspicion of malignancies and FNAC is negative, it is advised to subject the patient to various imaging studies, biomarkers and most important of all is to repeat the cytological examination. Further, it has been said that, in the absence of a positive diagnosis of carcinoma or in the absence of a lesion that would adequately explain the clinical findings, clinical judgement always prevails. Fine needle aspiration cytology is easily available and inexpensive. It is a reliable method in the diagnosis of cancer prostate. Its positive results are relatively more reliable than the negative ones. It is an effective method in follow up of the cancer cases. The progress of the disease and response to therapy can be assessed objectively with the help of FNAC.

Table – 5: Incidence of false positive reports in various studies.

Name of the Author	No. of cases	False +ve reports	False -ve reports
Melograna, et al. [11]	58	0%	23%
Present study	27	0%	15.79%

Conclusion

Fine needle aspiration cytology is easily available and inexpensive procedure. It is a reliable method in the diagnosis of prostatic

cancer. Its positive results are relatively more reliable than the negative ones. It is an effective method in follow up of the cancer cases.

References

1. Kiline TS, Kelsey DM, Kohler FP. Prostatic carcinoma and needle aspiration biopsy. *Am J Clin Pathol.*, 1976; 67(2): 131-3.
2. Hermida Perez JA, Ochoa Urdangarain O, Ramos Rodriguez AV, Acost Bernad I, Vento Remedios T, Mesa Borroto D, et al. Fine needle aspiration cytology in the diagnosis of prostate cancer. *Arch Esp Urol.*, 2001; 54(1): 23-33.
3. Singh N, Shenoi UD, Raghuvveer CV. FNAC and transabdominal ultrasonography in the diagnosis of prostatomegaly. *Indian J Pathol Microbiol.*, 1997; 40(4): 473-9.
4. Saleh Af, Nahar Rahman AJ, Salam MA, Islam F. Role of fine needle aspiration cytology (FNAC) in the diagnosis of prostatic lesions with histologic correlation. *Bangladesh Med Res Coun Bull.*, 2005; 31(3): 95-103.
5. Planelles Gómez J, Beltrán Armada JM, Alonso Hernández S, Tarín Planes M, Beamud Cortés M, Gil Salom M. Value of transrectal FNA in the diagnosis of prostate cancer in elderly patients. *Actas Urol Esp.*, 2008; 32(5): 485-91.
6. Fiobert L. Schmidt, Kirsten Howard, Brian J. Hall, Lester J. Layfield. Comparative Effectiveness of Fine-needle Aspiration Cytology Sampling Policies. *Am J Clin Pathol.*, 2012; 138: 823-30.
7. Chayanika Pantola, Sanjay Kala, P.K. Singh. A Correlative Study Between Transrectal FNAC And Histology Of The Prostate For The Detection of Prostate Carcinoma. *Journal of Dental and Medical Sciences (IOSR.JDMS)*, 2012; 1(1): 18-20.
8. Tariqul Islam, Tamanna Chowdhury, KH Khan. Fine Needle Aspiration Cytology of Prostatic Lesions with Histologic Correlation. *Ibrahim Med. Coll. J.*, 2007; 1: 7-10.
9. Esposti P-L. Aspiration Biopsy Cytology in the Diagnosis and Management of Prostatic Carcinoma. Stockholm, Stahl and Accidenstryct, 1974.
10. Melograna F, Oertel Y C, Kwart AM. Prospective controlled assessment of fine needle prostatic aspiration. *Urology*, 1982; 19(1): 47-51.