

Original Research Article


# Evaluation of salivary gland tumors by ultrasonography and CT-scan

Mansi Thakkar<sup>1\*</sup>, Parthiv Brahmhatt<sup>2</sup>, C. Raychaudhuri<sup>3</sup>

<sup>1</sup>1<sup>st</sup> Year Resident, <sup>2</sup>Professor, <sup>3</sup>Professor & HOD

Radiology Department, SBKS Medical Institute and Research Centre, Sumandeep Vidyapeeth, Vadodara, India

\*Corresponding author email: [thakkarmansi109@gmail.com](mailto:thakkarmansi109@gmail.com)

	International Archives of Integrated Medicine, Vol. 4, Issue 4, April, 2017. Copy right © 2017, IAIM, All Rights Reserved. Available online at <a href="http://iaimjournal.com/">http://iaimjournal.com/</a> ISSN: 2394-0026 (P)                      ISSN: 2394-0034 (O)
	Received on: 23-03-2017                      Accepted on: 30-03-2017 Source of support: Nil                      Conflict of interest: None declared.
<b>How to cite this article:</b> Mansi Thakkar, Parthiv Brahmhatt, C. Raychaudhuri. Evaluation of salivary gland tumors by ultrasonography and CT-scan. IAIM, 2017; 4(4): 14-18.	

## Abstract

**Introduction:** Salivary gland tumor is a tumor that forms in tissues of a salivary gland. Salivary gland cancer is rare, with 2% of head and neck tumors forming in the salivary glands, the majority in the parotid. Ultrasonography plays a very significant role in the diagnosis and management of salivary gland lesions. CT scan is useful for evaluating intra glandular component of mass.

**Aim and objectives:** To study the appearances of salivary gland tumors including major and minor salivary glands using radiological modalities like: Ultra-sonography, CT-SCAN, MRI to diagnosis and evaluate salivary gland tumors in order to do early management of the condition.

**Materials and methods:** 30 cases of either strong suspicion or symptoms related to salivary glands were evaluated who came to Dhiraj Hospital with different radiological modalities like Ultrasonography, CT-SCAN.

**Results:** Out of total number of 30 patients who were diagnosed and evaluated for salivary gland tumor on Ultrasonography, CT SCAN are conditions like: Warthin's Tumor, Pleomorphic adenoma, Mucoepidermoid Carcinoma, Lipoma, Rhabdomyosarcoma, Sialolithiasis in Submandibular gland, Lymphoma parotid and some other conditions related to major and minor salivary glands tumors.

**Conclusion:** Ultrasound and CT scan are both comparable in their ability to diagnose Salivary gland tumors. Although Ultrasound has a slightly inferior specificity rate as compared to CT scan, but it is still a very compelling option for the initial imaging of the Salivary gland tumors. CT scan is useful for evaluating intra glandular component of mass especially in deep lobe of parotid, mass extending to para-pharyngeal space that is inaccessible to ultrasound.

## Key words

Salivary gland tumor, USG, CT scan.

## **Introduction**

Salivary gland tumor is a tumor that forms in tissues of a salivary gland. The salivary glands are classified as major and minor. The major salivary glands consist of the parotid, submandibular, and sublingual glands. The minor glands include small mucus-secreting glands located throughout the palate, nasal and oral cavity [1]. Salivary gland cancer is rare, with 2% of head and neck tumors forming in the salivary glands, the majority in the parotid [2].

The algorithm for imaging the salivary glands depends on the clinical scenario with which the patient presents to the clinician. Many of the disease processes may not require imaging of any kind. Still others may be readily evaluated with palpation and direct visualization either endoscopically or transorally. There are a number of different imaging modalities for evaluation of salivary gland lesions like plain X-ray, sialography, Ultrasonography, Colour Doppler, CT scan, CT sialography, MRI and MR spectroscopy, nuclear medicine and PET scan [3].

Ultrasonography plays a very significant role in the diagnosis and management of salivary gland lesions. It has several significant inherent advantages which make it an ideal modality in the evaluation of salivary gland lesions [4]. It is generally used as the 1<sup>st</sup> line radioimaging modality for localization and characterization of lesions in the major salivary glands. It can differentiate intra glandular from extra glandular lesions. It can classify salivary gland lesions as focal or diffuse. Further characterization in terms of benign vs malignant nature can be done by evaluation of the lesion edges, internal vascularity and adjacent adenopathy. Ultrasound guided biopsy or drainage in cases of abscess can further aid in the diagnosis. Its easy availability, low cost and lack of radiation hazard further adds to its benefits [5].

Color Doppler demonstrates intra tumor vascular resistance which if found to be increased,

suggests an increase in the risk of the lesion being malignant.

CT scan is useful for evaluating intra glandular component of mass especially in deep lobe of parotid, mass extending to para-pharyngeal space that is inaccessible to ultrasound [6].

## **Aim and objectives**

- To differentiate the different salivary gland tumors according to their pathological classification.
- To locate the exact site, size, extension and multiplicity of the lesion and help the clinician in its treatment and management.

## **Materials and methods**

### **Study area**

The study was carried out in the Department of Radiodiagnosis, S.B.K.S. Medical Institute and Research Centre, Waghodia, Vadodara.

### **Study design**

Type of the study: An Observational, Descriptive Hospital Based Study.

**Sample size:** 30 patients.

### **Selection of subject**

#### **Inclusion criteria**

- Only those patients who are willing to participate in study will be included.
- Patients referred to the radiology department for evaluation of lesions suggestive of salivary gland tumors and found to have positive findings, will be included in this study. Already diagnosed cases of salivary gland tumors which need follow up radiological investigations and are referred to our radiology department will be included in study.
- Patients coming for investigations for other diseases, and are accidentally found to have salivary gland tumors, will be included in this study.

### Exclusion criteria

All patients unwilling were excluded from this study.

### Study protocol

30 Patients were evaluated, which comprised equal Male as well as female patients; Where the Patients had presented with swelling in the neck along with some associated symptoms like odynophagia, restricted mouth opening, fever, facial muscle weakness and lastly skin numbness .Proper diagnosis of salivary gland tumor was evaluated by Ultrasonography and CT scan.

### Results

A total 30 patients were examined and comparison done with operative and Histopathological diagnosis.

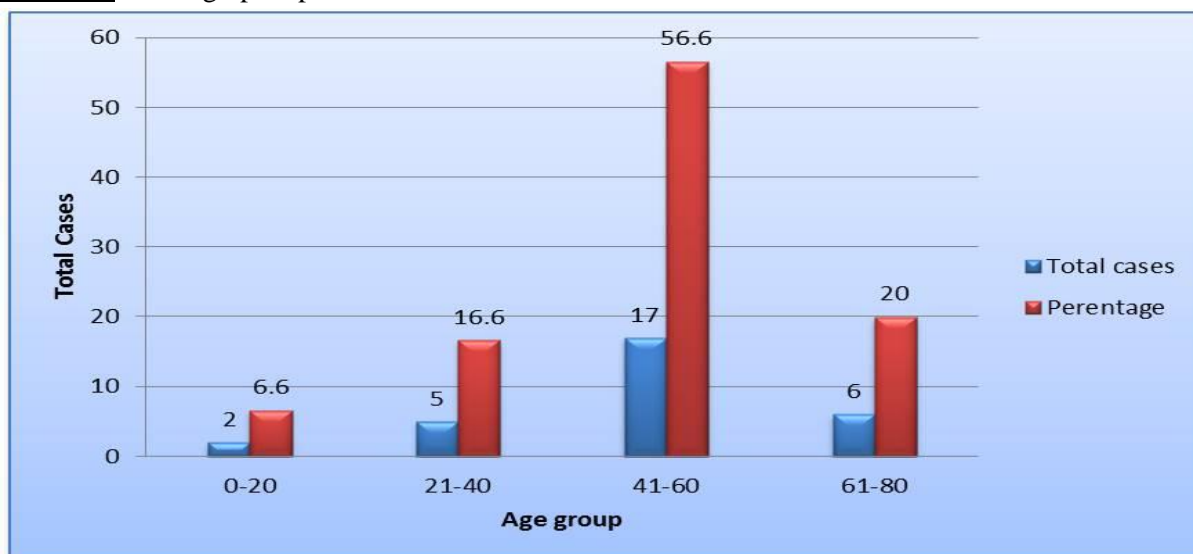
The salient observations are as follows:

- Most common age group in my study was 41-60 years (56%) followed by 61-80 years and 21-40 years having an incidence rate of 20% and 16% respectively.
- In my study Salivary gland tumor is more common in males (66.6%) than in females (33.3%) which is a ratio of 2:1.
- Most common presenting compliant is Swelling (100%) and Odynophagia

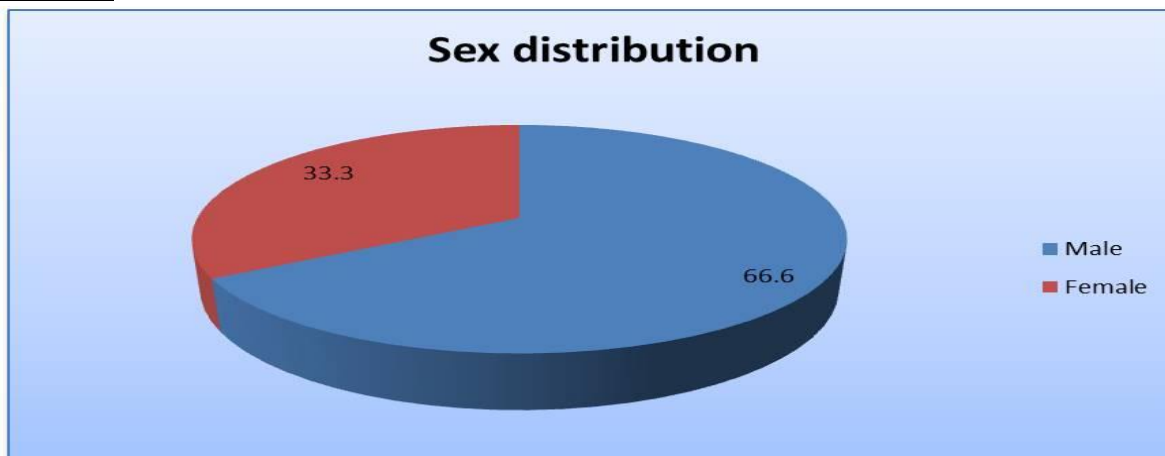
(43.3%) followed by Lymphadenopathy (26.6%) followed by restricted mouth opening (20%), fever (16.6%), facial muscle weakness (13.3%) and lastly skin numbness (6.6%).

- In my study the most common site of salivary gland tumors was Parotid gland (80%) followed by Submandibular gland (16.6%) and lastly minor salivary glands (3%) with no case affecting the sublingual gland.
- In my study Salivary gland tumors were unilateral in 76.6% of patients and bilateral in 23% of patients with Pleomorphic adenoma being the most common unilateral tumor and Warthin's tumor being the most common bilateral tumor.
- In my study 88.8% of the Pleomorphic adenomas were located in the Parotid gland and only 11.2% were located in the submandibular gland.
- Ultrasound and CT were comparable in there sensitivity rates with both showing a 100% sensitivity rate. CT was better than ultrasound in specificity and shows a specificity of 92.3% as compared to ultrasound which showed a specificity of 85.7% (**Chart – 1, 2, 3**).

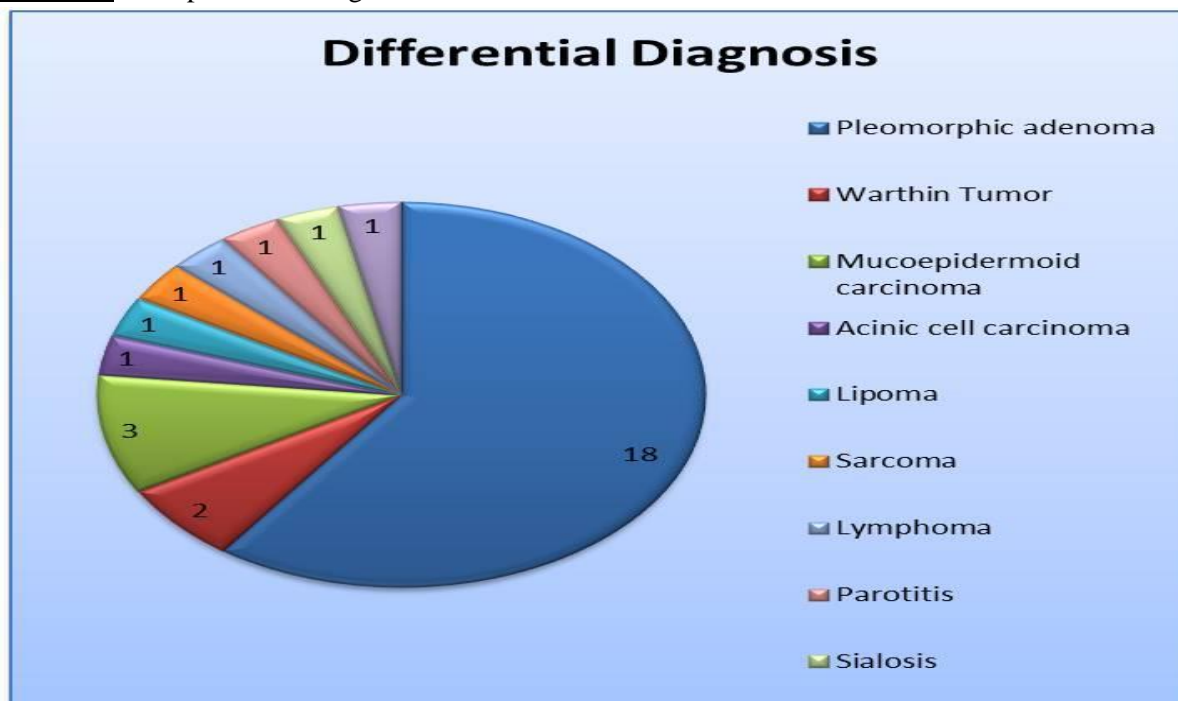
**Chart - 1:** Demographic profile.



**Chart - 2:** Sex distribution.



**Chart - 3:** Comparison of diagnosis.



**Discussion**

Most common age group in my study was 41-60 years (56%) followed by 61-80 years and 21-40 years having an incidence rate of 20% and 16% respectively.

In my study Salivary gland tumor is more common in males (66.6%) than in females (33.3%) which is a ratio of 2:1.

Most common presenting compliant is Swelling (100%) and Odynophagia (43.3%) followed by Lymphadenopathy (26.6%) followed by

restricted mouth opening (20%), fever (16.6%), facial muscle weakness (13.3%) and lastly skin numbness (6.6%).

**Conclusion**

Salivary gland tumors account for only 3% of all tumors in the body and it is estimated that about 1% of all head and neck malignant neoplasms arise in the salivary glands.

Most common age group in my study was 41-60 years (56%) followed by 61-80 years and 21-40

years having an incidence rate of 20% and 16% respectively.

In my study Salivary gland tumor is more common in males (66.6%) than in females (33.3%) which is a ratio of 2:1.

Most common presenting complaint is Swelling (100%) and Odynophagia (43.3%) followed by Lymphadenopathy (26.6%) followed by restricted mouth opening (20%), fever (16.6%), facial muscle weakness (13.3%) and lastly skin numbness (6.6%).

In my study the most common site of salivary gland tumors was Parotid gland (80%) followed by Submandibular gland (16.6%) and lastly minor salivary glands (3%) with no case affecting the sublingual gland.

## References

1. Batsakis JG. Tumors of the head and neck: clinical and pathological considerations. 2<sup>nd</sup> edition, Baltimore, MD: Williams & Willkins; 1979, p. 1–120.
2. Salivary glands Embryology, Fatima Aly, M.D.,
3. Candiani F, Martinoli C. Salivary glands. In: Solbiati L, Rizzatto G, eds. Ultrasound of superficial structures. Edinburgh, Scotland: Churchill Livingstone, 1995; p. 125–139.
4. Lin DT, Coppit GL, Burkey BB, Netterville JL. Tumors of the accessory lobe of the parotid gland: a 10-year experience. Laryngoscope, 2004; 114: 1652–1655.
5. Bradley MJ. Salivary glands. In: Ahuja AT, Evans RM, eds. Practical head and neck ultrasound. London, England: Greenwich Medical Media, 2000; p. 19–33.
6. Ying M, Ahuja A. Sonography of neck lymph nodes. I. Normal lymph nodes. Clin Radiol., 2003; 58: 351–358.