

Original Research Article


A five year study on differential diagnosis of verruciform penile lesions

S. Sujatha¹, V. Srinivas Kumar^{2*}, K. Durga³

¹Associate Professor, ²Assistant Professor, ³Professor and Head

Department of Pathology, KMC, Warangal, India

*Corresponding author email: vorugantisrinivasacme@gmail.com

	International Archives of Integrated Medicine, Vol. 4, Issue 10, October, 2017.	
	Copy right © 2017, IAIM, All Rights Reserved.	
	Available online at http://iaimjournal.com/	
	ISSN: 2394-0026 (P)	ISSN: 2394-0034 (O)
	Received on: 02-10-2017	Accepted on: 08-10-2017
	Source of support: Nil	Conflict of interest: None declared.
How to cite this article: S. Sujatha, V. Srinivas Kumar, K. Durga. A five year study on differential diagnosis of verruciform penile lesions. IAIM, 2017; 4(10): 123-127.		

Abstract

Background: Verrucous lesions of the penis are difficult to classify.

Materials and methods: The present study included 60 verrucous lesions of the penis in a period of 5 years, at Kakatiya Medical College, Warangal. Ours was a prospective study of 5 years duration.

Results: In our study the age group ranges from 30 years to 80 years. Majority of the lesions were observed between 60-69 years age group. Warty lesions constituted 40 (66.7%), Cauliflower like growths constituted 14 (23.3%), and diffusely infiltrating constituted 6 (10%). Histopathological examination findings showed out of 60, 24 biopsies diagnosed as condyloma accuminata, 9 as simple verrucous hyperplasia, and remaining 27 are diagnosed as carcinomas out of which verrucous carcinoma were 12 followed by condylomatous carcinoma and papillary carcinomas each 6, squamous cell carcinomas were 3 in number.

Conclusion: Each and every grossly visible verrucous lesions of the penis should be adequately biopsied for the early diagnosis of carcinoma.

Key words

Verrucous, Carcinoma, Condyloma accuminata.

Introduction

Verrucous lesions of the penis include both non neoplastic and neoplastic lesions. Non neoplastic lesions are predominantly of infectious in origin. The commonest infectious lesion is condyloma accuminatum caused by HPV (Human papilloma

virus) 90% of which are caused by types 6 and 11 and have low incidence of tumor development [1]. Non neoplastic lesions include simple verrucous hyperplasia. Neoplastic lesions include: Giant condyloma (Buschke-Lowenstein tumor) which is a fungating, locally invasive, low grade tumor attributed HPV, Verrucous

carcinoma, Condylomatous carcinoma, Squamous cell carcinoma.

Condyloma accuminatum of penis is a venereal disease and most commonly seen between the ages of 20-40 years of age. It presents as a papillary growth, at the penile meatus or Fossa navicularis or in other regions of the glans. Microscopically there are complex papillary infoldings of squamous epithelium, accompanied by vacuolization of keratinocytes and nuclear abnormalities (koilocytes) and a lymphocytic infiltrate in the stroma that is predominantly composed of CD4+ cells [1, 2].

Squamous cell carcinoma is relatively infrequent in the United States, but is common in Asian, African and Latin American countries constitutes 10% of all carcinomas. Common in elderly, the incidence increases in 80 yrs and above. The incidence of Squamous cell carcinoma is relatively infrequent in the United States, but is common in Asian, African and Latin American countries and constitutes 10% of all carcinomas. The chances of development are less if circumcision is done shortly after birth. There may be association with other conditions of penis e.g. Lichen sclerosis atrophicans, Balanitis xerotica obliterans, and Lichen planus. HPV Types 16, 18 may be implicated in tumor genesis. They commonly arises in the Glans, followed by prepuce and coronal sulcus. They may be fungating, Verruciform sometimes infiltrative and ulcerating lesions [1, 3].

Verrucous carcinoma constitutes about 5% of all carcinomas of the Penis, has got a more organized architecture especially at the base. It features broad Bulbous expansions of squamous epithelium [5].

Hybrid tumors: Tumors with combined features of both squamous cell carcinoma and Verrucous carcinoma are seen infrequently [4-6].

Differential diagnosis

- Simple Verrucous hyperplasia shows hyperkeratosis, acanthosis and papillomatosis

- Giant condylomas show surface koilocytosis with blunt bulbous rete pegs
- Condylomatous carcinoma shows koilocytosis throughout the lesion and has infiltrating borders.
- Verrucous carcinoma are very well differentiated tumors with lesions showing hyperkeratosis, papillomatosis, acanthosis and prolonged rete ridges with blunt bulbous pushing borders. There is clear demarcation between border and underlying stroma.
- Low grade papillary carcinomas are characterized by hyperkeratosis, acanthosis, papillomatosis with jagged infiltrating borders.
- Verrucous lesions of penis are rare in literature.

Materials and methods

The present study was a prospective study of 5 years duration, conducted from April 2012 to March 2015, in the Department of Pathology, Kakatiya Medical College, Warangal. In our study, the age group ranges from 30 years to 80 years. Majority of the lesions were observed between 60-69 years of age group. Total number of verruciform lesions received was 60, including 20 excision biopsies and 40 penectomy specimens.

Results

Grossly

Warty lesions included 40 (66.7%), Cauliflower like lesions constituted 14 (23.3%), Condyloma accuminata constituted 24.

Histopathology

- Simple verrucous hyperplasias were 9 in number.
- Verrucous carcinomas were 12 in number
- Papillary carcinomas were 6 in number
- Squamous cell carcinomas were 3 in number
- Condylomatous carcinomas were 6 in number (**Figure – 1 to 11**).

Figure - 1: Histological types of verrucous lesions of penis.

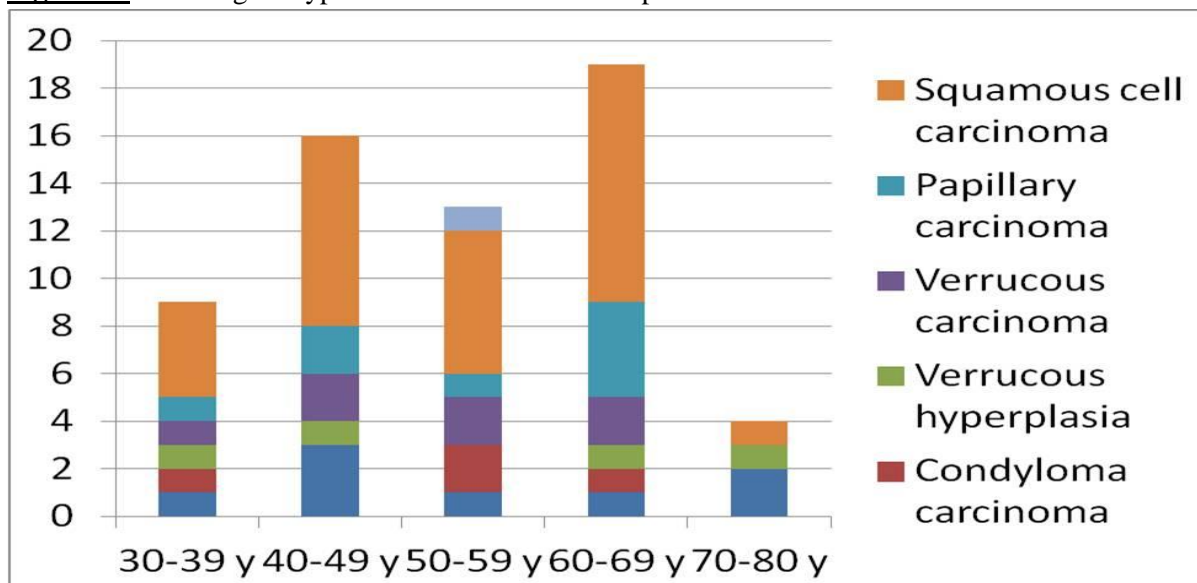


Figure – 3, 4: Simple Verrucous hyperplasia shows hyperkeratosis, acanthosis and papillomatosis.

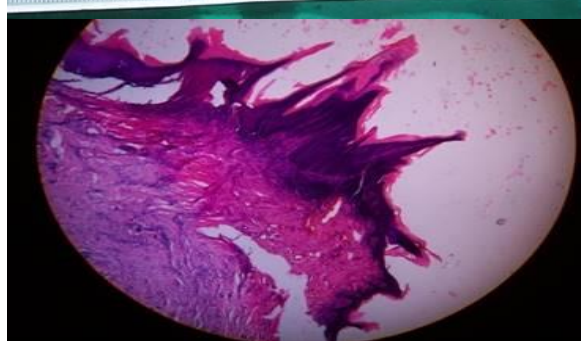


Figure – 4, 5: Giant condylomas show surface koilocytosis.

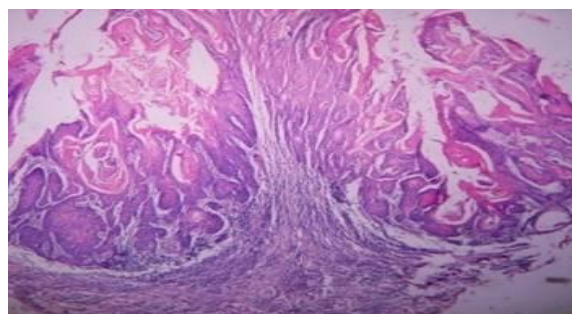


Figure – 6, 7: Condylomatous carcinoma shows koilocytosis throughout the lesion and has infiltrating borders.

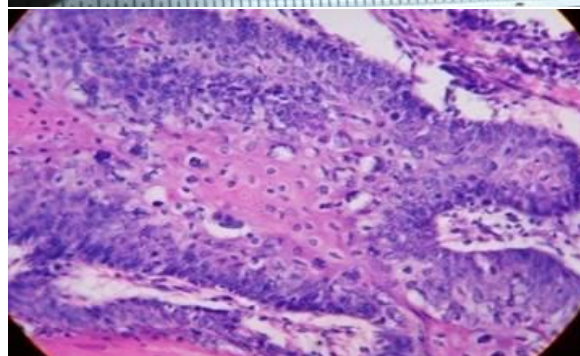
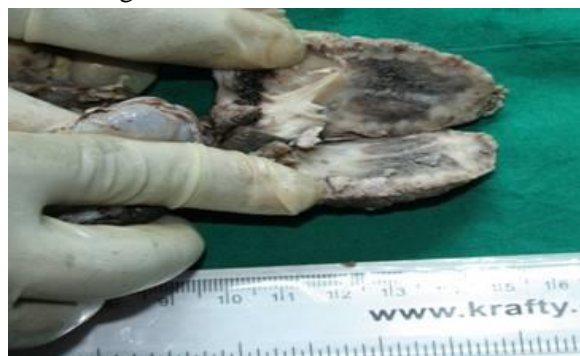


Figure – 8, 9: Verrucous carcinoma with bulbous rete ridges.

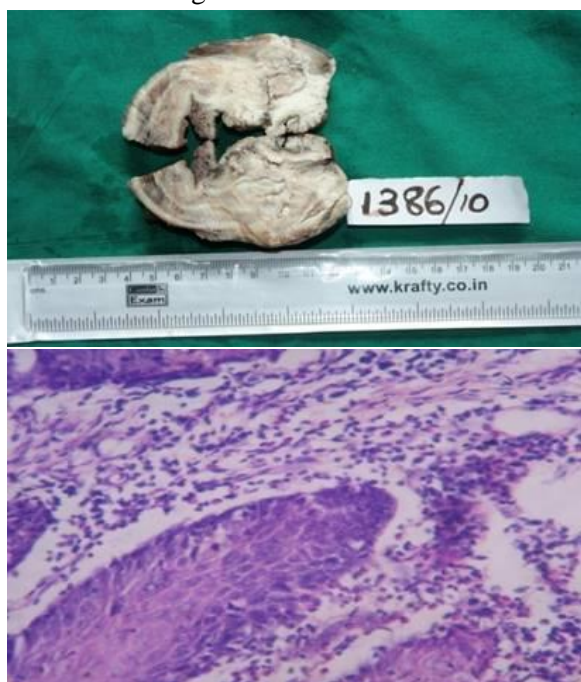
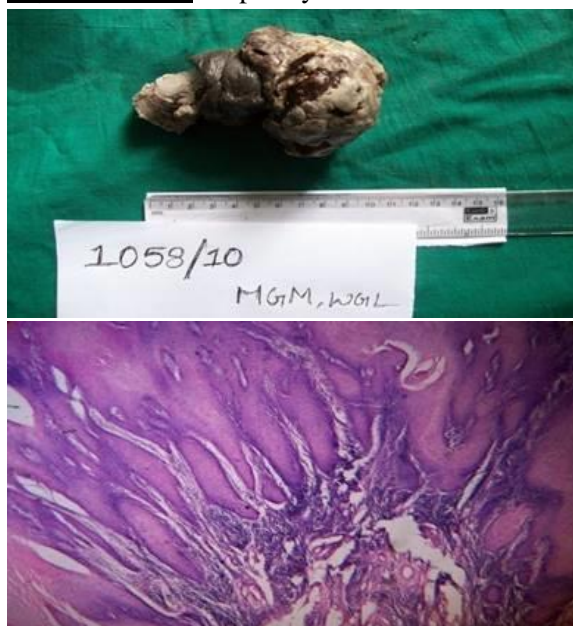

Figure – 10, 11: Papillary carcinoma.



Discussion

Penile verrucous lesions are rare in literature. Majority constitute non neoplastic and infectious lesions. Condyloma accuminatum is a ‘Venereal disease caused by HPV is commonly seen between the ages of 20-40 years. It presents as a papillary growth in the penile meatus, or fossa navicularis, or other regions of the Glans.

Almost 30% of the polypoid lesions of the male urethra are examples of this entity [1].

Microscopy; There are complex papillary infoldings of squamous epithelium accompanied by vacuolization of keratinocytes and nuclear abnormality composed of CD4+ Cells. The viruses can be demonstrated by IHC and insitu hybridization techniques. In our study out of 60 cases 24 constituted condyloma accuminatum [1].

Verrucous carcinoma of penis is an uncommon variant of squamous cell carcinoma. This form of cancer is often seen in those who chew Tobacco or use snuff orally, also referred as “Snuff dippers cancer”. This form of cancer is often seen in those who chew Tobacco or use snuff orally also referred as Snuff dippers cancer. In our study, out of 60 lesions 12 constitute Verrucous carcinomas. Which is correlating with the studies of Lowhagen GB, et al., microscopic features show bulging and broad based rete ridges along with acanthosis and papillomatosis.

Squamous cell carcinoma of penis

It has got infrequent incidence and less than 1% of all malignancies in the males in USA. It is common in, African and Latin American countries. It may constitute over 10% of all carcinomas. It is predominantly a disease of elderly and peak about 80 years of age [6], and may be related to personal hygiene and carcinogenic affect of smegma and also associated with HPV. The common sites are glans, prepuce and coronal sulcus, in this order of frequency. Their pattern of growth may be superficially spreading, predominantly exophytic (Fungating, verruciform) or predominantly endophytic, infiltrating, ulcerating and vertical superficially spreading, predominantly exophytic (Fungating, verruciform) In our study out of 60 cases only 3 were found to be Squamous cell carcinomas constituting 5%.our studies are correlating with Horenblaus, et al. [5].

Conclusions

Verruciform lesions of penis are difficult to sub classify, classification is important as the treatment and prognosis vary. Superficial biopsy in any of the verrucous lesions shows only hyperkeratosis, acanthosis and papillomatosis. Therefore adequate biopsy is a must to show the rete pegs that extends into the deeper tissues. Deeper biopsies are always required for the accurate diagnosis.

References

1. Rosai and Ackermans, Surgical pathology, vol 1, Rosai MD, Penis and scrotum, chapter 18, Elsevier, p. 1385-87.
2. Lowhagen GB. Penile condyloma. Genitourinary Medicine, 1993; 69: 87-90.
3. Kraemer BB. Verrucous xanthoma of the penis. Arch Dermatol., 1981; 117: 516-518.
4. Grossman B. Premalignant and early carcinoma of the penis. Urologic Clinics of North America, 1992; 19: 221-6.
5. Horenblas S. Squamous cell carcinoma of Penis. Journal of Urology, 1991; 146: 1279-83.
6. Seixas AL. Verrucous carcinoma of Penis. Journal of Urology, 1994; 152: 1476-8.