

Original Research Article


Specular microscope as an accurate tool for analysing corneal endothelial cell changes in patients with type 2 diabetes mellitus at tertiary care hospital set up in Kanchipuram District

Dr. D. Sundararajan¹, Dr. N. Sathish Kumar^{2*}

¹Associate Professor, ²Assistant Professor

Department Ophthalmology, Meenakshi Medical College, Hospital and Research Institute, Enathur, Kanchipuram, India

*Corresponding author email: eyesurgeon2004@gmail.com

| | | |
|--|---|--------------------------------------|
|  | International Archives of Integrated Medicine, Vol. 4, Issue 10, October, 2017. Copy right © 2017, IAIM, All Rights Reserved. Available online at http://iaimjournal.com/ | |
| | ISSN: 2394-0026 (P) | ISSN: 2394-0034 (O) |
| | Received on: 28-09-2017 | Accepted on: 12-10-2017 |
| Source of support: Nil | | Conflict of interest: None declared. |
| How to cite this article: D. Sundararajan, N. Sathish Kumar. Specular microscope as an accurate tool for analysing corneal endothelial cell changes in patients with type 2 diabetes mellitus at tertiary care hospital set up in Kanchipuram District. IAIM, 2017; 4(10): 188-193. | | |

Abstract

Background: Diabetic eye disease comprises a group of eye conditions that affect people with diabetes. These conditions include diabetic retinopathy, diabetic macular edema (DME), cataract, and glaucoma. All forms of diabetic eye disease have the potential to cause severe vision loss and blindness. Animal studies have also shown that corneal endothelial cells in diabetic rats have morphological abnormalities. These abnormalities include a decrease in endothelial cell density (CD) and hexagonality, as well as increased polymegathism, polymorphism, and central corneal thickness (CCT).

Aim: To compare corneal endothelial cell changes such as endothelial cell density (ECD) percentage of polymegathism (coefficient of variation) along with central corneal thickness (CCT) in patients with type 2 diabetes mellitus with age-matched control subjects.

Materials and methods: Totally 40 patients among them 20 Patients (40 eyes) with type 2 DM and 20 control (non-diabetic) subjects (40 eyes). The corneal endothelial structure and CCT were examined in all eyes by noncontact specular microscopy using KONAN MEDICAL Specular

Microscope. The endothelial structure was studied for ECD, the coefficient of variation of cell area (CV), and percentage of hexagonal cells. Results were analyzed accordingly.

Results: In our study, 20 patients (40) eyes with HbA_{1c} were 8.5% (Group I) and 20 patients (40) eyes with HbA_{1c} 4.5% (Group II) Endothelial cell density was significantly lower in the diabetic cornea than in control group ($P=0.34$). In (Group I) CV was higher in the diabetic cornea ($P=0.003$). The diabetic cornea group had a lower percentage of hexagonal cells than the control group (II), but the difference was not statistically significant ($P=0.503$). Also, the diabetic cornea was thicker in (Group I) than the control group, (Group II) but not statistically significant ($P=0.210$).

Conclusion: This study documented that type 2 DM causes a significant reduction of endothelial cell density and increased coefficient of variation (polymegathism). Also, the diabetic cornea has increased central corneal thickness and a lower percentage of hexagonal cells than normal subjects, but without statistical significance.

Key words

Central corneal thickness, Diabetes mellitus, Diabetic retinopathy, Specular microscopy.

Introduction

The corneal endothelium is a single layer of uniformly sized cells with a hexagonal shape. Their amount decreases by approximately 0.5%-0.6% (100–200 cells) per year. The endothelial cell dysfunction is observed in myopia and in contact lens wearers. The decreasing number of endothelial cells can also be a result of a surgical injury related to the opening of the anterior chamber [1]. Many studies have shown that even minor changes in the morphology of the endothelial cells may manifest in the disturbances in the tightness of the endothelial barrier [2]. It has been demonstrated that human corneal endothelial cells have the mitotic ability *in vitro*, but *in vivo*, they do not exit the cell cycle but are arrested in G1 phase. The corneal endothelial cell is responsible for maintaining the transparency of the cornea [3]. There is limited ability of mitosis in corneal endothelium and once damaged, remaining cells enlarge to cover up the lost area. There will be an increase in variation of cell area called polymegathism or coefficient of variation (CV) and index of hexagonality (6A) or pleomorphism [4]. Central corneal thickness (CCT) can be used as a marker of endothelial health and can be used to monitor corneal edema. There is a postulated association between corneal thickness and severity of diabetic retinopathy. Age can always be considered as a confounding factor in studying

the disease of corneal endothelium and endothelial cell density has been found to decrease with age specular microscope [5]. The modern noncontact specular microscope to study corneal endothelium employ automated interfacing for obtaining an image through a discrete focusing technology. Corneal changes are diagnosed in about 70% of adult patients with diabetes [6]. The observed disorders include increased fragility and damage of the corneal endothelium and recurrent erosions and increased sensitivity to injuries. The experimental research discovered abnormal basement membrane of the endothelium, a decreased number of hemidesmosomes, and a prolonged healing of the cornea and its decreased sensitivity. Many studies confirmed that diabetes causes abnormalities in morphology and functioning of corneal endothelium cells. Functional disturbances may lead to increased autofluorescence of the cornea and its increased penetrability. Morphological changes may result in a high variability factor of the endothelial cell surface and decreased percentage of hexagonal cells in corneas in patients with diabetes, using noncontact specular microscope, when compared to healthy patients [7].

Materials and methods

This was a prospective study of 40 patients with mean age of 40.5 (± 14.2) years who were

examined at the Department of the Ophthalmology at Meenakshi medical college and research institute, Enathur, Kanchipuram from January 2017 To June 2017. Totally 40 patients among them 20 Patients (40 eyes) with type 2 Diabetes mellitus and 20 control (non-diabetic) subjects (40 eyes). The corneal endothelial structure and CCT were examined in all eyes by noncontact specular microscopy using KONAN MEDICAL Specular Microscope. Informed consent was obtained from all subjects for their participation in the study. Patients with previous ocular surgery, trauma, contact lens use history, corneal dystrophy, corneal edema, high intraocular pressure and any other anterior segment disorders affecting the corneal endothelium were excluded from the study. The corneal endothelial density (ECD) and central corneal thickness (CCT) in its central part were diagnosed using a same specular microscope.

Statistical analysis

Comparisons of age and mean CCT, ECD, and CV were made between diabetic patients and control subjects using unpaired t-tests. Multiple regression analysis was used to assess an interaction term of disease, status, and age (data from control and diabetic subjects were pooled together). One way ANOVA was then used to

compare each of the three ocular parameters under diabetes duration groups (#10 years of duration versus .10 years duration) with control group.

Results

The demographics of the study participants are shown in **Table - 1**. There was no statistically significant difference (unpaired t-test: P=0.344) between the age of control subjects and type 2 DM patients and between the gender distribution of diabetic subjects and normal subjects (chi-square: P= 0.091).

ECD was significantly lower in the diabetic cornea group ($2,010.69 \pm 3.9.5$ cell/mm²) than in the control group (2363.62 ± 241.86 cell/mm²) (P=0.015). CV was higher in the diabetic cornea group (0.23 ± 3.45) (P=0.009, which was considered statistically significant). Diabetic cornea group had a lower percentage of hexagonal cells ($30.38 \pm 9.8\%$) than the control group ($39.78 \pm 8.2\%$), but the difference was not statistically significant (P=0.673). Also, cornea was thicker in the diabetic group ($446.54 \pm 28.84 \mu\text{m}$) than control group ($403.14 \pm 16.82 \mu\text{m}$), but not statistically significant (P=0.301) as per **Table - 2**.

Table – 1: Demographic data and HbA1c level among patients of patients (N=40).

| Groups | Age (mean ±SD) (years) | Gender (n=20) | Mean HbA1c level (%) |
|------------------|------------------------|---------------|----------------------|
| Group –I (n=20) | 38±8.3 | 13/7 | 6.3±4.7 |
| Group –II (n=20) | 41±7.8 | 11/9 | 3.5±3.2 |

Table – 2: Specular microscope parameters analysis among group I and group II.


| Parameters | Diabetic patients (Group I) | Controls (Group II) | P value |
|------------------------------|-----------------------------|----------------------|---------|
| ECD ((cell/mm ²) | 2,010.69±3.9.5 | 2363.62±241.86 | 0.015 |
| CCT(mm) | 446.54 ± 28 .84 | 403.14± 16.82 | 0.894 |
| CV | 0.39±0.05 | 0.23±3.45 | 0.009 |
| Hexagonality (%) | 30 .38± 9.8 | 39.78± 8.2 | 0.301 |

KONAN MEDICAL specular microscope picture showing decreased endothelial cell count, increased the coefficient of variation (CV), a

lower percentage of hexagonal cells and increased (CCT) central corneal thickness in type 2 diabetic patient (**Photo – 1**).

KONAN MEDICAL specular microscope picture showed normal endothelial cell count, the coefficient of variation, central corneal thickness, and hexagonal cells in a control group patient (**Photo - 2**).

Photo - 1: Corneal endothelium cell count picture taken by specular microscope (KONAN MEDICARE) for type 2 diabetes patients (46 years old).

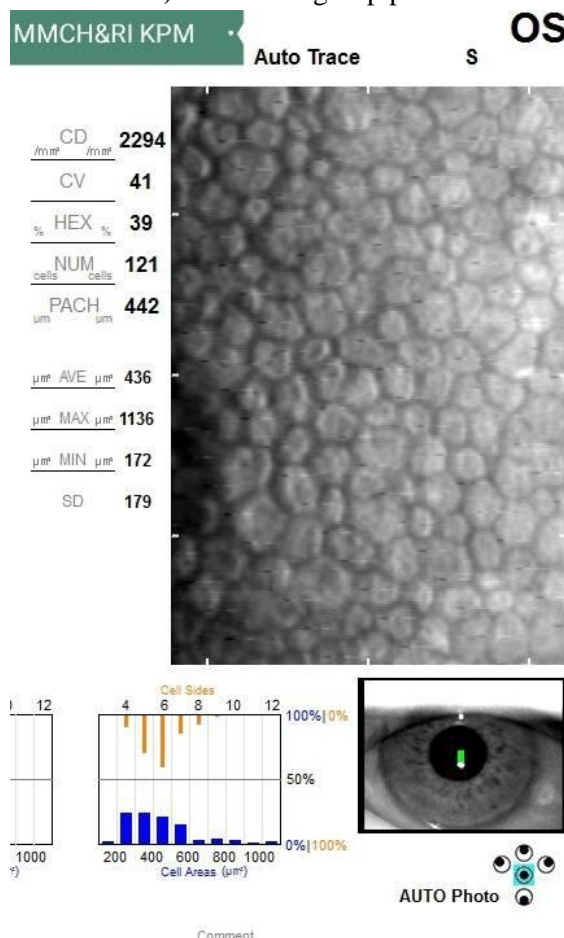


Discussion

According to our results, diabetic patients showed significant differences compared with normal persons in terms of the central corneal thickness and morphological change of the corneal endothelium [8]. Diabetes of over 10 years' duration showed thicker corneas, a lower corneal endothelium density, lower hexagonality ratios, and higher coefficients of variation in cell size than those patients having diabetes of under 10 years' duration. However, there were only

significant differences between diabetes of over 10 years' and under 10 years' duration in corneal thickness and coefficients of variation in cell size [9]. With regard to the corneal endothelial morphology, the coefficient of variation in cell size appears to be the most sensitive to three factors of corneal endothelial morphology: cell density, hexagonality, coefficient variation, according to the duration of diabetes [10].

Photo - 2: Corneal endothelial cell count picture taken by specular microscope (KONAN MEDICARE) for control group patients.



KONANTM
MEDICAL

Overall, this fact is likely to suggest that polymegathism and pleomorphism may precede a decrease in cell density. Modest.al reported that diabetic patients frequently had abnormal corneal

endothelium in contrast to normal persons, but there were no significant differences in terms of the function of the fluorescence permeability of the corneal thickness and endothelium. This means that the corneal endothelium of diabetic patients has a structural disorder, but the functional disorder of the corneal tissues is not affected [11]. M. Matsuda, et al. reported that it took longer for diabetics to recover from damaged corneal tissues compared with normal persons. As the corneal endothelium of diabetic patients has a structural disorder, a functional disorder of the diabetic corneal tissues can be caused by a stimulus like stress or trauma to the corneal tissues or from the lack of an adequate oxygen supply. Therefore, it is necessary to carefully observe functional disorders including disorders in the permeability of the corneal tissues when conducting ophthalmologic procedures such as cataract operations and PRP or when diabetics use contact lenses for a long period of time [12]. The findings on the relation of CCT, ECD, and CV to the mode of glucose control among diabetic participants show the use of insulin injections 1.7 times more likely to predispose patients to have a greater reduction in ECD when compared to those on oral medications [13]. Although diabetic subjects on insulin injection were more likely to show greater reductions in ECD than those on oral medications, this relationship did not reach a statistically significant level [14]. Clinically, patients are switched to insulin due to poor glucose control with oral medication and diet. It is likely that corneal damage may have begun in patients with poor glucose control before they were switched to insulin injections or that corneal thickness increase is present very early in the disease and may thus be an early clinically detectable change in the eyes of subjects with Diabetes mellitus [15]. On the basis of our study's results, diabetes has morphological abnormalities such as greater baseline corneal thickness, a decreased endothelial cell density and percentage of hexagonality, and an increased coefficient of variation in cell size in contrast to normal persons [16]. For diabetic durations of over 10 years, the central corneal thickness and

coefficient of variation in cell size were noted to increase and cellular density and hexagonality were noted to decrease. Especially, the central corneal thickness was significantly correlated with the duration of diabetes after controlling for age.

Pearson correlation analysis reported absence of significant correlations between DM duration, HbA_{1c} levels, and severity of diabetic retinopathy and morphological features of diabetic cornea such as CCT, CV, hexagonality, or ECD [17].

Conclusion

This study documented that type 2 DM resulted in a significant reduction of ECD and increased CV (polymegathism). Also, diabetic cornea had increased CCT and a lower percentage of hexagonal cells than in the cornea of normal subjects, but this is not statistically significant. In addition, our study demonstrated that diabetes mellitus duration, HbA_{1c} levels, and severity of DR had no significant correlations with CCT, CV, hexagonality, or ECD.

References

1. M. Roszkowska, C. G. Tringali, P. Colosi, C. A. Squeri, G. Ferreri. Corneal endothelium evaluation in type I and type II diabetes mellitus. *Ophthalmologica*, 1999; 213(4): 258–261.
2. Diabetes Atlas. International Diabetes Federation; 2016.
3. Goh S, Cooper ME. The role of advanced glycation endproducts in progression and complications of diabetes. *J Clin Endocrinol Metab.*, 2008; 93: 1143-1152.
4. J. S. Lee, B. S. Oum, H. Y. Choi, J. E. Lee, B. M. Cho. Differences in corneal thickness and corneal endothelium-related to the duration of diabetes. *Eye*, 2006; 20(3): 315–318.
5. J. Siribunkum, P. Kosrirukvongs, A. Singalavanija. Corneal abnormalities in diabetes. *Journal of the Medical*

- Association of Thailand, 2001; 84(8): 1075–1083.
6. J. V. Laursen, S. S. Hoffmann, A. Green, M. Nybo, A. K. Sjølie, J. Grauslund. Associations between diabetic retinopathy and plasma levels of high-sensitive C-reactive protein or von Willebrand factor in long-term type 1 diabetic patients. *Currently Research*, 2013; 38(1): 174–179.
 7. K. Inoue, S. Kato, Y. Inoue, S. Amano, T. Oshika. The corneal endothelium and thickness in type II diabetes mellitus. *Japanese Journal of Ophthalmology*, 2002; 46(1): 65–69.
 8. K. Zorena, E. Malinowska, D. Raczynska, M. Mysliwiec, K. Raczynska. Serum concentrations of transforming growth factor-1 in predicting the occurrence of diabetic retinopathy in juvenile patients with type 1 diabetes mellitus. *Journal of Diabetes Research*, 2013, Article ID 614908, 6 pages.
 9. Kaufmann C, Bachmann LM, Thiel MA. Comparison of dynamic contour tonometry with Goldmann applanation tonometry. *Invest Ophthalmol Vis Sci.*, 2004; 45: 3118-3121.
 10. L. I. Larsson, W. M. Bourne, J. M. Pach, R. F. Brubaker. Structure and function of the corneal endothelium in diabetes mellitus type I and type II. *Archives of Ophthalmology*, 1996; 114(1): 9–14.
 11. L. Modis´ Jr., E. Szalai, K. Kertesz, A. Kemeny´-Beke, B. Kettesy, A. Berta. Evaluation of the corneal endothelium in patients with diabetes mellitus type I and II. *Histology and Histopathology*, 2010; 25(12): 1531–1537.
 12. M. Matsuda, N. Ohguro, I. Ishimoto, M. Fukuda. Relation-ship of corneal endothelial morphology to diabetic retina-thy, duration of diabetes and glycemic control. *Japanese Journal of Ophthalmology*, 1990; 34(1): 53–56.
 13. M. Z. Ziadi, P. Moiroux, P. D’Athis, A. Bron, J. M. Brun, C. Creuzot-Garcher. Assessment of induced corneal hypoxia in diabetic patients. *Cornea*, 2002; 21(5): 453–457.
 14. N. Furuse, S. Hayasaka, Y. Yamamoto, T. Setogawa. Corneal endothelial changes after posterior chamber intraocular lens implantation in patients with or without diabetes mellitus. *The British Journal of Ophthalmology*, 1990; 74(5): 258–260.
 15. O’Donnell C, Efron N, Boulton AJM. A prospective study of contact lens wears in diabetes mellitus. *Ophthalmic Physiol Opt.*, 2001; 21: 127-138.
 16. Ogbuehi K, Almubrad T. The relationship between corneal biomechanical properties and intraocular pressure. *Actaophthalmologica*, 2011; 89(Suppl248): S0-0.
 17. R. R. Sudhir, R. Raman, T. Sharma. Changes in the corneal endothelial cell density and morphology in patients with type 2 diabetes mellitus: a population-based study, Sankara Nethralaya Diabetic Retinopathy and Molecular Genetics Study (SN-DREAMS, Report 23). *Cornea*, 2013; 31(10): 1119–1122.