

Original Research Article


Intercalary Non Vascularized Fibular Graft in Pediatric Forearm Bone Defects - Post Chronic Osteomyelitis

Siddharth Goel^{1*}, Sansar Chand Sharma², Harnam Singh Madan³

¹Associate Professor, ²Professor, ³Assistant Professor

Department of Orthopedics, SHKM Govt. Medical College, Mewat, Haryana, India

*Corresponding author email: drsiddharthgoel@gmail.com

	International Archives of Integrated Medicine, Vol. 4, Issue 11, November, 2017. Copy right © 2017, IAIM, All Rights Reserved. Available online at http://iaimjournal.com/ ISSN: 2394-0026 (P) ISSN: 2394-0034 (O)
	Received on: 30-10-2017 Accepted on: 06-11-2017 Source of support: Nil Conflict of interest: None declared.
How to cite this article: Siddharth Goel, Sansar Chand Sharma, Harnam Singh Madan. Intercalary Non Vascularized Fibular Graft in Pediatric Forearm Bone Defects - Post Chronic Osteomyelitis. IAIM, 2017; 4(11): 187-192.	

Abstract

Introduction: For bridging gap in bone defects created by tumor excision, trauma or as sequelae to infection, various treatment modalities are described including iliac crest graft, cortical tibial graft, allograft, bone transport using the principles of Ilizarov, fibula as an intercalary bone graft and vascularized fibula. Various implants used for fixation are wires, screws, plates, and ring or monorail fixator. Free non vascularized fibula is a popular substitute for this method because of its easy accessibility and minimal donor site morbidity. It has the advantage of being a much simpler procedure and avoids the use of costly implants making it a more feasible and practical solution for bone defects in developing countries. The present study was aimed at finding the results of it in bone gap created after debridement of radius/ulna following chronic osteomyelitis in pediatric population.

Material and methods: 12 children of age 4-13 years with diagnosis of chronic osteomyelitis of forearm bones were included in the study. In first stage adequate bone and soft tissue debridement was done. In radial chronic osteomyelitis, to maintain radial length and DRUJ, distractor application was done. Distractor was removed after about 3 weeks and then, “press fit” free non vascularized fibular graft was applied and fixed with intramedullary K wire. The limb was immobilized in plaster till union of fibula at both ends.

Results: The average per operative gap at time of grafting was 7 cm (range 4-8 cm). Union was achieved at both ends in all cases in 12-18 weeks with no major complication. One ulnar osteomyelitis

case had delayed union at one site which gradually healed. At about 1 year children had good forearm range of motion.

Conclusion: Non-vascularized fibular grafting is a good option for bone defects in paediatric population provided adequate debridement, fixation and immobilization has been done.

Key words

Free non-vascularized fibula, Forearm, Chronic osteomyelitis, Children

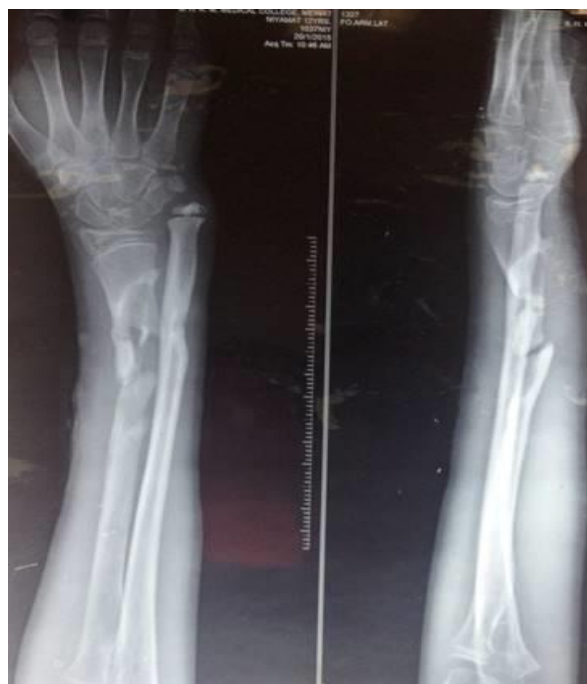Introduction

For bridging gap in bone defects created by tumor excision, trauma or as sequelae to infection, various treatment modalities are described including iliac crest graft [1], cortical tibial graft [2], bone transport using the principles of Ilizarov [3], fibula as vascularized [4] or non-vascularized graft [5], centralization of one bone [6] and allograft. Various implants used for fixation are wires, screws, plates, and ring or monorail fixator [3, 7, 8]. Free non vascularized fibula [9, 10, 11] is a popular substitute for this method because of its easy accessibility and minimal donor site morbidity [12]. It has the advantage of being a much simpler procedure and avoids the use of costly implants making it a more feasible and practical solution for bone defects specially in developing countries. The aim of the present study was to find the results of free non vascularized fibula in bone gap created after debridement of radius/ulna following chronic osteomyelitis in pediatric population.

Materials and methods

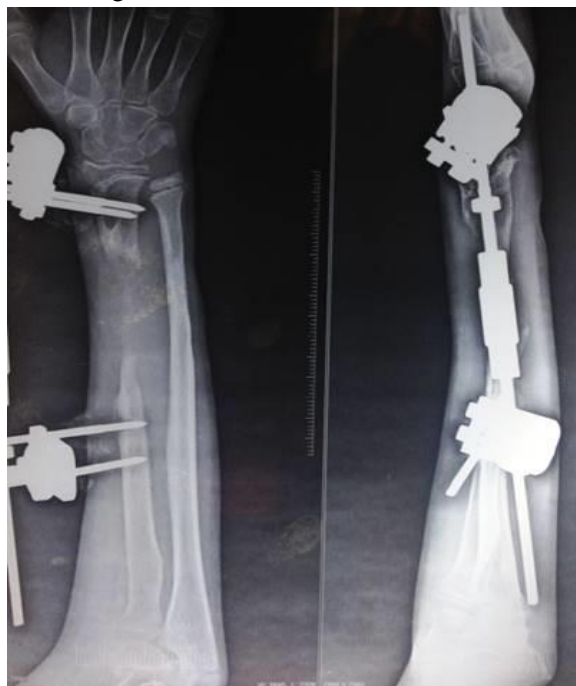The study was a prospective study conducted at a tertiary level state run hospital. 12 children of age 4-13 years with diagnosis of chronic osteomyelitis forearm bones were included in the study. There was 8 Radius and 4 Ulna involved. All children included in study at time of presentation had discharging sinus and radiologically had evidence of sequestrum. In all radial osteomyelitis Distal Radio Ulnar Joint (DRUJ) was disrupted (**Figure – 1**) and ulnar variance was recorded. Preoperative inflammatory markers – ESR and CRP were done.

Figure – 1: Radius Osteomyelitis with positive ulnar variance.



The children were managed in two stages. In first stage adequate bone and soft tissue debridement was done, either of radius or ulna depending on the bone involved. The approach to radius either dorsal or volar depended upon the sinus tract. For ulna standard postero-medial approach was used. Per operatively tissue sample for culture and sensitivity was sent. In radial chronic osteomyelitis, to maintain radial length and DRUJ, distractor application was done. Gradual distraction was done to maintain the ulnar variance (**Figure – 2**) and after about 3 weeks it was removed. Post-operatively initially broad spectrum i.v. antibiotics for 5 days were given and then for 3 weeks oral antibiotics given according to sensitivity report. Simultaneously, CRP and ESR settled, and there were no clinical or radiological sign of infection, second stage operation was done.

Figure – 2: Post Debridement with Distraction correcting the ulnar variance.



In the second stage the bone ends were freshened, again sample taken for culture and the final gap measured. For radius, opposite approach than in first stage, was used. Non-vascularized fibula was harvested of length 1cm more than the gap, placed in the gap after manually distracting the forearm as much as possible and fixed with intramedullary K wire. After releasing the traction fibula got “press fit” between the parent bone (**Figure - 3, 4**). Postoperatively antibiotics continued up to 3 weeks more. The limb was immobilized in plaster slab for about 6-8 weeks till radiological evidence of union commencement of fibula at both ends occurred. The child was followed at 6, 12, 24 weeks and then 3 monthly for at least 1 year post operatively. Follow up included union and functional status along with note of any complications.

Results

Age of the 12 children ranged from 4-13 years. There were 6 boys and 6 girls. 8 radius and 4 ulna were involved. No child had both bone osteomyelitis. One child had osteomyelitis as sequelae to old untreated compound fracture, rest were due to hematological route.

Figure – 3: Fibula grafted in “press fit” manner in 2nd Stage operation.

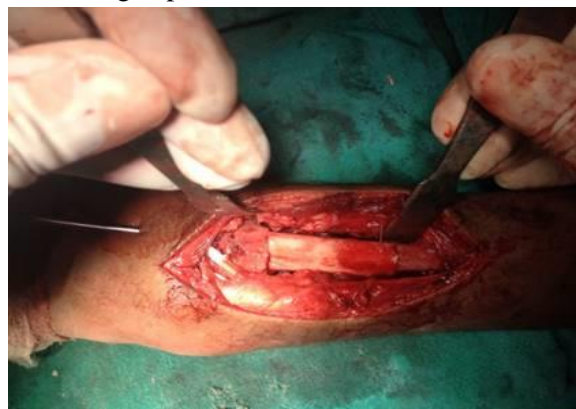
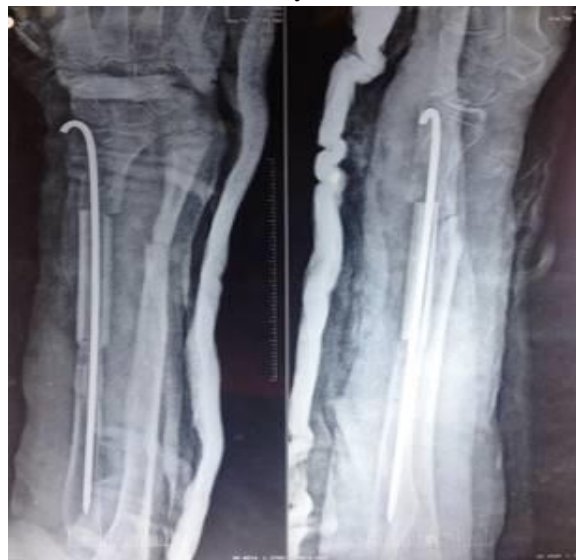
Figure – 4: Post-op X ray- intercalary fibula fixed with intramedullary K wire.



The average per operative gap after 1st stage debridement and 2nd stage bone end freshening i.e. at time of fibular grafting was 7 cm (range 4-8 cm). The average follow up period was 14 months with a range of 12 – 18 months.

After distractor application ulnar variance was maintained in the radial osteomyelitis cases, before the second stage operation. But it was observed that after fibular grafting there was some loss of ulnar variance, though with no effect on functional outcome (**Figure - 5a, 5b, 5c**). Union was achieved at both ends of all cases in 12-18 weeks with average of 14 weeks (**Figure - 6**). One ulnar osteomyelitis had delayed union at proximal graft site which healed at 9 months. No child had deep infection, graft

resorption or donor site morbidity. Two children had superficial infection at cutaneous K-wire insertion site which healed by oral antibiotics.

Figure - 5a, 5b, 5c: Functional outcome.

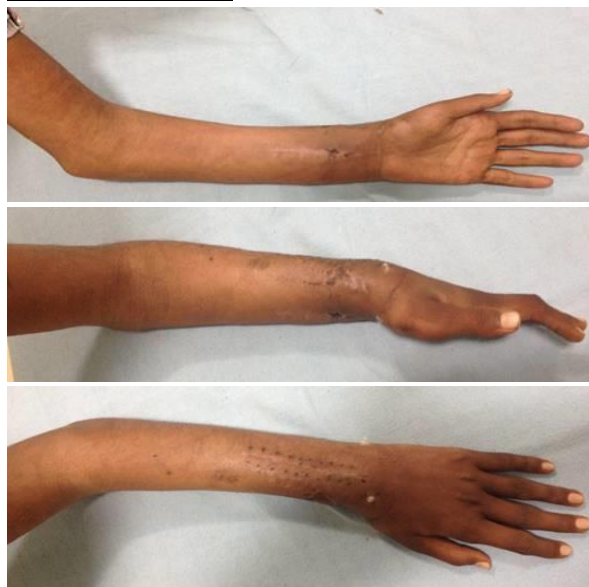
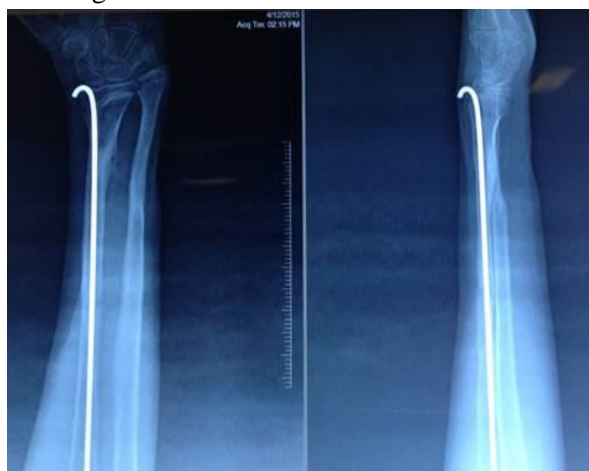
Figure – 6: 6 months post-operative X-ray showing union at both interface site.



At about 1 year follow up children had good wrist, elbow and supination-pronation range of motion, as compared to the normal side. Grip strength tested manually was also comparable to the normal hand. They were doing all the playful activities required for that age without any disability.

Discussion

Bone gap can occur after tumor excision, osteomyelitis debridement and sequelae to trauma in humerus, radius, ulna, neck or shaft of

femur and tibia, in any age group. There are many options available for bridging these defects [3-8]. Free non-vascularized fibular grafting has been used in long bone defects [9-11]. It is a simple procedure and has much better patient compliance when compared to other methods of treating bone defects like bone lengthening procedures using Ilizarov, especially in forearm bones of children.

The advantage of vascularized grafts is that they do not rely on re-vascularization and therefore should become fully incorporated sooner. However, it is a technically demanding procedure, requiring special microscopic instruments, with a high rate of thrombosis of the graft vessels [13, 14].

El-Sayed, et al. [10] reported a study of 12 patients with post-traumatic bone defect. They concluded that non-vascularized fibular grafting is a simple procedure with good results. Although in our study the defect was due to post osteomyelitis debridement but the results are comparable. Al-Zahrani, et al. [9] found good results in 27 patients using non-vascularized fibular graft, augmented with a cortico-cancellous bone graft to bridge bone defects. The indications included infection, fracture with bone loss, non-union, bone tumor, bone cyst and congenital pseudoarthrosis. They achieved union in 92%. They concluded that the non-vascularized fibular graft augmented with cortico-cancellous bone graft along its whole length is a simple procedure to bridge bone defects. In our study after fibular grafting no cortico-cancellous grafting was done, though it did not affect the union in our results.

Steinlechner, et al. [11] reported excellent results in eight patients with non-vascularized fibular grafting in patients with defects of long bones after sequesterectomy. They followed up seven of the eight patients and all had union at a mean of 10 weeks. They used intramedullary K wires as fixation device. Swamy, et al. [15] studied 20 patients with bone defects, 19 of which due to osteomyelitis. They used plate for fixation of

graft and concluded that non-vascularized fibular grafting is a good option for bone defects in pediatric population provide adequate fixation and immobilization has been done. In our study, in all cases we used intramedullary K-wire for fixation and fibula was grafted in a "press fit" manner to attain automatic compression at graft host interface, thereby augmenting union.

When fibular grafting has been undertaken for osteomyelitis or infected non-union, rates of infection of up to 57% have been reported. Even with a previously sterile surgical field infection may lead to loss of the graft [16, 17]. In our study we did two stage procedures for being sure to eradicate infection first, maintaining radial length by distractor, and in second stage reconstructing the forearm with non-vascularized fibular graft fixed with intramedullary K wire. By using this two staged procedure, clinical and inflammatory markers as indicator of infection, we did not encountered deep infection in any of the children.

Conclusion

Non-vascularized fibular grafting is a good option for bone defects in pediatric population provided adequate debridement, fixation and immobilization has been done. It is a simple and cost effective procedure requiring minimal surgical technique with gratifying results.

References

1. Nicoll BA. The treatment of gaps in long bones by cancellous insert grafts. *J Bone Joint Surg Br.*, 1956; 38: 70–82.
2. Boyd HB. The Treatment of difficult and unusual non-union. *J Bone Joint Surg.*, 1943; 25: 535.
3. Tetsworth K, Krome J, Paley D. Lengthening and deformity correction of the upper extremity by the Ilizarov technique. *Orthop Clin North Am.*, 1991; 22: 689–713.
4. Jupiter JB, Gerhard HJ, Guerrero J, Nunley JA, Levin LS. Treatment of segmental defects of the radius with use of the vascularized osteoseptocutaneous fibular autogenous graft. *J Bone Joint Surg Am.*, 1997; 79: 542.
5. Moroni A, Rollo G, Guzzardella M, Zinghi G. Surgical treatment of isolated forearm non-union with segmental bone loss. *Injury*, 1997; 28: 497–504.
6. Haque IU. The production of a one bone forearm as a salvage procedure after hematogenous osteomyelitis: A case report. *J Bone Joint Surg Br.*, 1982; 64: 454–5.
7. Spira E. Bridging of bone defects in the forearm with iliac graft combined with intramedullary nailing. *J Bone Joint Surg Br.*, 1954; 36: 642–6.
8. Ring D, Allende C, Jafarnia K, Allende BT, Jupiter JB. Ununited diaphyseal forearm fractures with segmental defects: Plate fixation and autogenous cancellous bone grafting. *J Bone Joint Surg Am.*, 2004; 86: 2440–5.
9. Al-Zahrani S, Harding MG, Kremlı M, Khan FA, Ikram A, Takroni T. Free fibular graft still has a place in the treatment of bone defects. *Injury*, 1993; 24: 551e554.
10. El-Sayed M, El-Hadidi M, El Adl Wael. Free non-vascularised fibular graft for treatment of post-traumatic bone defects. *Acta Orthop Belg.*, 2007; 73: 70e76.
11. Steinlechner C, Wand M, Kandawire NC. Non-vascularised fibular transfer in the management of defects of long bones after sequestrectomy in children. *J Bone Joint Surg Br.*, 2005; 87-B: 1259-1263.
12. Eh Lee, Goh JC, Helm R, Pho RW. Donor site morbidity following resection of the fibula. *J Bone Joint Surg Br.*, 1990; 72: 129-131.
13. Yajima H, Tamai S, Mizumoto S, Inada Y. Vascularised fibular grafts in the treatment of osteomyelitis and infected non-union. *Clin Orthop.*, 1993; 293: 256-64.
14. Minami A, Kasashima T, Iwasaki N, Kato H, Kaneda K. Vascularised fibular

- grafts. J Bone Joint Surg [Br], 2000; 82-B: 1022-5.
15. M.K.S. Swamy, Akhilesh Rath, Vikas Gupta. Results of non-vascularised fibular grafting in gap non-union of long bones in paediatric age group. Journal of Clinical Orthopaedics and trauma, 2013; 4: 180-184.
16. Enneking WF, Eady JL, Burchardt H. Autogenous bone grafts in the reconstruction of segmental skeletal defects. J Bone Joint Surg [Am], 1980; 62-A: 1039-58.
17. Han C-S, Wood MB, Bishop AT, Cooney WP 3rd. Vascularised bone transfer. J Bone Joint Surg [Am], 1992; 74-A: 1441-9.