

Case Report


A rare case report of primary fallopian tube carcinoma in 40 year old female

Meenu Rani^{1*}, Gursatinder Kaur²

¹3rd year Resident, ²2nd year Resident

Saraswathi Institute of Medical Sciences, CCS Meerut University, India

*Corresponding author email: drmeenudhaiya@gmail.com

	International Archives of Integrated Medicine, Vol. 4, Issue 11, November, 2017. Copy right © 2017, IAIM, All Rights Reserved. Available online at http://iaimjournal.com/ ISSN: 2394-0026 (P) ISSN: 2394-0034 (O)
	Received on: 08-10-2017 Accepted on: 25-10-2017
	Source of support: Nil Conflict of interest: None declared.
How to cite this article: Meenu Rani, Gursatinder Kaur. A rare case report of primary fallopian tube carcinoma in 40 year old female. IAIM, 2017; 4(11): 281-284.	

Abstract

Primary cancer of the fallopian tube is very rare. An average of 20 to 30 new cases are reported each year. The incidence of this cancer varies from 0.14 to 1.8% of all Gynecological cancers. It is possible that the true incidence of PFTC has been underestimated because PFTC may have been mistakenly identified as ovarian tumors during initial surgery and/or during microscopic examination by a pathologist, as the histological appearance of these tumors are identical. Here in we report a classic case of PFTC in 40 year old female.

Key words

Fallopian tube, Primary cancer, Histological appearance.

Introduction

Primary cancer of the fallopian tube is very rare [1-4]. An average of 20 to 30 new cases are reported each year [5-7]. The incidence of this cancer varies from 0.14 to 1.8% of all gynecological cancers [2]. Secondary malignant lesions of the fallopian tube usually arise from the adjacent ovary or uterus, occasionally from the gastrointestinal tract and rarely the breast or peritoneal carcinomatosis [8]. An association is seen in those with BRCA-1 gene [9]. When secondary, these are single and localized in less

than 50% of cases. These cases should be managed aggressively at primary surgery in view of their poor outcome – reportedly worse than that of ovarian cancer, stage for stage [10, 11]. It is possible that the true incidence of PFTC has been underestimated because PFTC may have been mistakenly identified as ovarian tumors during initial surgery and/or during microscopic examination by a pathologist, as the histological appearance of these tumors are identical. Here in we report a classic case of PFTC in 40 year old female.

Case report

A 40 years old woman, came in Gynecological OPD with complaint of bilateral pain in iliac fossae for 7 days, haematuria since 2 days and retention of urine since 1 day. Patients' menstrual history was indicated irregular menses with frequency of 2-3 months. On examination patients' vitals were stable. On per abdomen examination, there was presence of ascites + and freely mobile mass of around 8x7 cm was felt in the right iliac fossa. On per vaginal examination cervix was downward forward, uterus was anteverted normal size, in right adnexa a mass of 8x6 cm size was felt which was freely mobile and left adnexa were free. Patient was not having any complaint of tenderness. All her routine haematological and serological investigations were normal. On trans-abdominal ultrasonography examination showed moderate ascites. Free fluid was seen in supra hepatic, sub hepatic and pelvic cavity and a mixed echogenic mass of 8x5.2x 8.3 cm from right side adnexal region. CT abdomen report was Suggestive of Heterogeneous mass of size 11.7 x 8.9 x 9 cm arising from left ovary. Clinical diagnosis was right sided ovarian malignancy and patient underwent laparotomy. During surgery there was around 15x 10 x 13.8 cm size mass arising from right fallopian tube was found. Following which Total abdominal hysterectomy with bilateral salpingo oophorectomy was done and the specimen was sent for histopathology examination. On gross examination uterus measured 7.8x 5.3x4 cm. Right sided Fallopian tube had mass at fimbrial end measuring 8.9x 5.7x 8 cm. On cut section solid areas, hemorrhages and small cystic areas were seen. On microscopic examination of the right FT mass showed hyperplastic mucosal lining with severe degree dysplasia suggestive of serous adenocarcinoma invading through all layers of fallopian tube. Cuboidal and low columnar tumor cells are arranged mainly around cleft like spaces forming tubular structures. The nuclei were large hyperchromatic with voluminous clear cytoplasm. Overall features were in line with that of serous adenocarcinoma moderately

differentiated grade-II (**Photo - 1, 2**). Section from uterine end of right FT showed hyperplastic changes with high degree of dysplasia at places reaching up to carcinoma in situ. All other adnexa didn't show any remarkable pathology. Patient was explained about the implications of chemotherapy and referred to the oncology center.

Photo – 1: Malignant cells of adenocarcinoma with area of necrosis (H&E stain, 40X).

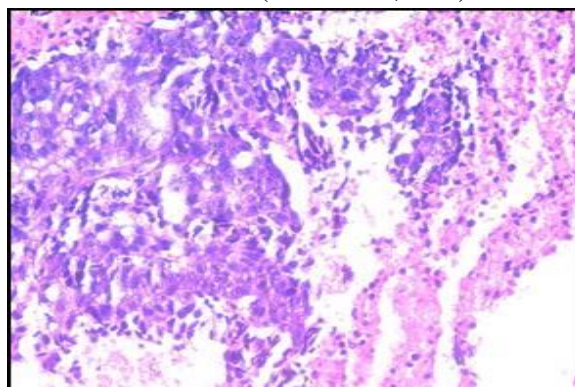
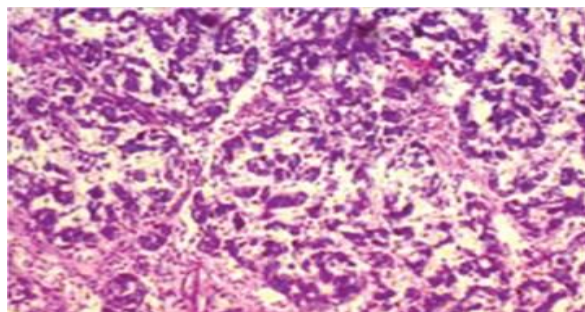


Photo – 2: Tumor cells showed tubular architecture and infiltrating stroma (H&E stain, 40X).



Discussion

Primary cancer of the fallopian tube is a rare gynecological cancer [1, 2]. An average of 20 to 30 new cases reported annually [3, 4]. The rarity of this cancer is due to the fallopian tube low oncogenic potential, in contrast to the vulnerability of the organ to infection. It is generally of poor prognosis [5-7]. The diagnosis can be made wrongly as ovarian cancer, it is during the initial surgery or during the examination and pathology. Cancer of the fallopian tube occurs most often after the fourth decade of life, with an average age of 62 years

(17-88 years) [2, 12, 13]. No case is reported in childhood. The age of our patient is 40 years younger than the average age reported in the literature [2-4]. Abdominal pain, vaginal bleeding, hydrohemorrhage, impaired general condition and palpation of a pelvic mass are the most common symptoms during the primary cancer of the fallopian tube [14]. The concept of pelvic pain in the history of the disease, due to distension of the tubes, combined with lateral uterine pelvic mass on imaging should suspect a tumor of the fallopian tube. Diagnosis is rarely made preoperatively. Intraoperative diagnosis itself is not possible in 50% of cases due to tumor extension [6]. And even when the tumor is resected, it is possible not to report the diagnosis of cancer on pathological examination, and to report it as an ovarian cancer [4, 6]. The current suggested management is to treat such malignancies as epithelial ovarian malignancy.

The other managements suggested are intraperitoneal chemotherapy, second look surgery, radiotherapy, neo adjuvant chemotherapy, and immunotherapy or gene therapy. But the results of these managements are not promising. Intraperitoneal chemotherapy is not so popular because of toxicity concerns and a number of unanswered fundamental questions regarding efficacy such as optimal agent, schedule, future trial designs, and the impact of alternative agents such as biologic therapies (vascular endothelial growth factor and epidermal growth factor targeting) have limited the general acceptance of this strategy in the clinical community [15,16].

Conclusion

Primary tubal cancer is rare, of unknown etiology and sometimes mistaken for uterine or ovarian pathology. The clinical signs are rarely present in full and histopathological examination is the gold standard for the final diagnosis.

References

1. Nappi R, Resta L, Nappi L, Louizzi P. Primary carcinoma of the fallopian tube:

- report on two cases. *Eur J Obstet Gynecol Reprod Biol.*, 1996; 70(1): 93-6.
2. Pectasides D, Pectasides E, Papaxoinis G, Andreadis C, Papatsibas G, Fountzilas G, et al. Primary fallopian tube carcinoma: Results of a retrospective analysis of 64 patients. *Gynecol Oncol.*, 2009; 115(1): 97-101.
3. Asmussen M, Kaern J, Kjoerstad K, Wright PB, Abeler V. Primary adenocarcinoma. *Gynecol Oncol.*, 1988; 30(2): 183-6.
4. Wang PH, Yuan CC, Chao HT, Juang CM, Ng HT. Prognosis of primary fallopian tube adenocarcinoma: report of 25 patients. *Eur J Gynaecol Oncol.*, 1998; 19(1): 571-4.
5. Gadducci A, Landoni F, Sartori E, Maggino T, Zola P, Gabriele A, et al. Analysis of treatment failures and survival of patients with fallopian tube carcinoma: a cooperation task force (CTF) study. *Gynecol Oncol.*, 2001; 81(2): 150-9.
6. Klein M, Rosen AC, Lahousen M, Graf AH, Rainer A. Lymphadenectomy in primary. *Cancer Lett.*, 1999; 147(1-2): 63-6.
7. Kosary C, Trimble EL. Treatment and survival for women with Fallopian tube carcinoma: a population-based study. *Gynecol Oncol.*, 2002; 86(2): 190-1.
8. Colgan TJ. Challenges in the early diagnosis and staging of Fallopian tube carcinomas associated with BRCA mutations. *Int J Gynecol Pathol.*, 2003; 22: 109-20.
9. Klein M, Rosen A, Lahousen M, Graf AH, Rainer A. The relevance of adjuvant treatment in primary carcinoma of fallopian tube stage 1 & 2: Irradiation v/s chemotherapy. *Int J Radia Oncol Biol Phys.*, 2000; 48(5): 1427-31.
10. Sedlis A. Carcinoma of the fallopian tube. *Surg Clin North Am.*, 1978; 58: 12-19.

11. Woolas RP, Smith JHF, Sarharnis P, et al. Fallopian tube carcinoma: an under-recognized primary neoplasm. *Int J Gynecol Cancer*, 1997; 7: 284–288.
12. Gemignani ML, Hensley ML, Cohen R, Venkatraman E, Saigo PE, Barakat RR. Paclitaxel-based chemotherapy in carcinoma of the fallopian tube. *Gynecol Oncol.*, 2001; 80(1): 16-20.
13. Baekelandt M, Jorunn Nesbakken A, Kristensen GB, Trope CG, Abeler VM. Carcinoma of the fallopian tube. *Cancer*, 2000; 89(10): 2076-84.
14. Deffieux X, Morice P, Thoury A, Camatte S, Duvillard P, Castaigne D. Extension lymphatique pelvienne et lombo-aortique dans le cancer de la trompe: topographie et implications chirurgicales. *Gynecol Obstet Fertil.*, 2005; 33(1-2): 23-8
15. Takeshima N, Hasumi K. Treatment of fallopian tube cancer. Review of the literature. *Arch Gynecol Obstet.*, 2000; 264: 13–19.
16. Rose PG, Piver MS, Tsukada Y. Fallopian tube cancer. The Roswell Park experience. *Cancer*, 1990; 66: 2661–2667.