

## Case Report

# Schwannoma of forearm – Difficult clinical diagnosis


Shweta P. Bijwe<sup>1\*</sup>, Arunkumar D. Chopwad<sup>2</sup>, Praveen Lagdive<sup>3</sup>

<sup>1</sup>Department of Pathology, IGGMC, Nagpur, Maharashtra, India

<sup>2</sup>Department of Pathology, Seth GS Medical College, Mumbai, Maharashtra, India

<sup>3</sup>Department of Pathology, SRTR Medical College, Ambejogai, Maharashtra, India

\*Corresponding author email: [dr.shwetabijwe@gmail.com](mailto:dr.shwetabijwe@gmail.com)

	International Archives of Integrated Medicine, Vol. 5, Issue 1, January, 2018.	
	Copy right © 2018, IAIM, All Rights Reserved.	
	Available online at <a href="http://iaimjournal.com/">http://iaimjournal.com/</a>	
	ISSN: 2394-0026 (P)	ISSN: 2394-0034 (O)
	Received on: 01-01-2018	Accepted on: 07-01-2018
	Source of support: Nil	Conflict of interest: None declared.
<b>How to cite this article:</b> Shweta P. Bijwe, Arunkumar D. Chopwad, Praveen Lagdive. Schwannoma of forearm – Difficult clinical diagnosis. IAIM, 2018; 5(1): 149-151.		

## Abstract

Benign tumors involving peripheral nerves of the upper extremity are uncommon. The swelling may be misdiagnosed as other soft tissue neoplasm like lipoma, ganglion or lymph node. Schwannomas also known as neurilemmoma usually originate from Schwann cells located in the peripheral nerve sheaths. They account for about 5% of all the benign soft-tissue neoplasms in the adults and 19% of the tumors occur in upper extremities. Schwannomas generally presented as an asymptomatic mass causing discomfort. With the increasing size of the tumor pain, numbness, and fatigue may occur. We report a case of schwannoma on forearm which was clinically misdiagnosed as foreign body granuloma and was excised. Diagnosis was made on histopathology. Diagnosing the peripheral nerve schwannomas can be challenging clinically. Hence, a detailed clinical, radiological and histopathological evaluation is essential. Peripheral nerve schwannoma is rare and observation of a single patient can add to our understanding this rare disease.

## Key words

Peripheral schwannoma, Nerve sheath tumor, Location forearm.

## Introduction

Benign tumors involving peripheral nerves of the upper extremity are uncommon [1]. The swelling may be misdiagnosed as other soft tissue neoplasm like ganglion, lipoma or lymph node. Schwannomas also known as neurilemmoma

usually originate from Schwann cells located in the peripheral nerve sheaths occurs in the age group of 20 to 70 years. They account for about 5% of all the benign soft-tissue neoplasms in the adults [2] and 19% of the tumors occur in upper extremities [3]. Schwannomas generally presented as an asymptomatic mass causing

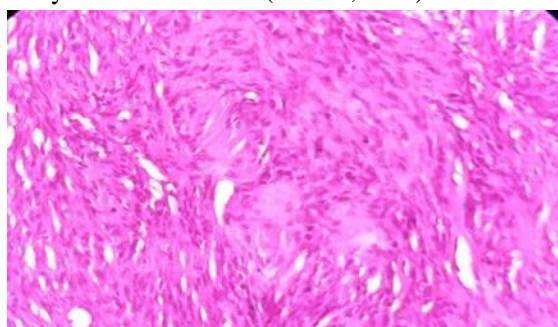
discomfort. With the increasing size of the tumor pain, numbness, and fatigue may occur. They are solitary and found along the anterior aspect of the extremities by the side of the nerves. EMG, MRI, and USG are helpful in the diagnosis. Surgical removal is usually curative.

### Case report

40 year female presented with painless, slowly growing swelling on right forearm near anticubital fossa since 2 years. On clinical examination it was a solitary nodule measuring 2x3 cm in size, non-tender, mobile. Overlying skin was normal. Clinical diagnosis of foreign body granuloma was kept as patient gave history of trauma 2 years back. Any radiological investigations were not performed. Nodule was excised and sent for histopathology.

**On microscopy** – Histopathological examination showed neoplasm composed of hyper- and hypocellular areas. The hypercellular areas are composed of spindle-shaped cells, whereas the hypocellular areas are composed of loosely arranged cells with round-to-oval nuclei. Verocay bodies, collection of lipid-laden cells and cystic changes are also seen. Features are consistent with schwannoma (**Figure - 1** and **Figure – 2**).

**Figure – 1:** Microphotograph showing Verocay body in schwannoma (H & E, 40X).

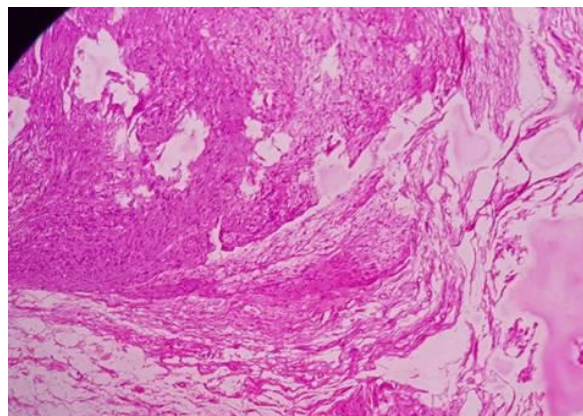


### Discussion

Schwannomas are rare tumors. They are usually solitary and benign lesions; however they can be multiple suggesting an underlying tumor predisposition syndrome and may be associated

with neurofibromatosis type 1 and schwannomatosis [4].

**Figure – 2:** Antoni A and Antoni B areas in schwannoma (H & E, 40X).



Schwannomas are slowly growing, and encapsulated benign nerve sheath neoplasms separated from the surrounding tissues. These tumors are soft in consistency, mobile and generally presented as an asymptomatic mass causing discomfort. With the increasing size of the tumor pain, numbness, and fatigue may occur. They may be misdiagnosed clinically as soft tissue neoplasm like lipoma, fibroma, ganglion, or xanthoma. Holdsworth [5] and Phalen [6] reported low rates of correct diagnosis. Microscopically, two types of cells have been described namely Antoni A and Antoni B, which are found in typical schwannomas and Verocay bodies seen [7, 8]. The tumor cells are considered to be strongly immunopositive for the S-100 protein [7].

MRI is considered to be the most important radiological imaging technique for diagnosing the nerve sheath tumors, but differentiating between schwannomas and neurofibromas remains difficult even today [9].

Rate of malignant transformation and recurrence are very low in schwannoma, resection of the tumor after careful dissection is recommended. There may be slight impairment of the nerve function after the tumour resection due to dissection and nerve retraction, but it returns to normal after few months [8].

In our case clinical diagnosis of foreign body granuloma was kept as patient gave history of trauma and lesion was asymptomatic. Radiological investigations were also not performed. Final diagnosis was made on histopathological examination. Thus it shows that diagnosis of peripheral nerve schwannoma, can be very challenging clinically.

### **Conclusion**

Diagnosing the peripheral nerve schwannomas can be challenging clinically. Hence, a detailed clinical, radiological and histopathological evaluation is essential. Peripheral nerve schwannoma is rare and observation of a single patient can add to our understanding this rare disease.

### **References**

1. Louis D S, Hankin F M. Benign nerve tumors of the upper extremity. *Bulletin of the New York Academy of Medicine*, 1985; 61(7): 611–620.
2. Forthman C L, Blazar P E. Nerve tumors of the hand and upper extremity. *Hand clinics*, 2004; 20(3): 233–242.
3. Dadgupta T K, Brasfield R D, Strong E W, Hsjdu S I. Benign solitary schwannomas (neurilemmomas). *Cancer*, 1969; 24(2): 355–366.
4. Harun Kütahya, Ali Güleç, Yunus Güzel, Burkay Kacira, Serdar Toker. Schwannoma of the Median Nerve at the Wrist and Palmar Regions of the Hand: A Rare Case Report. *Case Reports in Orthopedics*, 2013; Article ID 950106, 4 pages, 2013.
5. Holdsworth B J. Nerve tumours in the upper limb a clinical review. *Journal of Hand Surgery*, 1985; 10(2): 236–238.
6. Phalen G S. Neurilemmomas of the forearm and hand. *Clinical Orthopaedics and Related Research*, 1976; 114: 219–222.
7. Trăistaru R, En ăchescu V, Manu CD, Gruia C, Ghiluși M. Multiple right schwannoma. *Rom J Morphol Embryol.*, 2008; 49(2): 235-9.
8. Ozdemir O, Ozsoy MH, Kurt C, Coskunol E, Calli I. Schwannomas of the hand and wrist: long term results and review of the literature. *J Ortho Surg (Hong Kong)*, 2005 Dec; 13(3): 267-72.
9. VanHerendael B, Heyman S, Schepper Am, Gielen J, Parizel PM. Schwannoma of left ulnar nerve. *JBR-BTR*, 2006 May–Jun; 89(3): 156-7.