

Original Research Article


# Comparison of various techniques in the management of fistula in ano

Manivannan Dhanraj<sup>1</sup>, Nachiappan Meenakshisundaram<sup>2\*</sup>,  
Vinodh Duraisami<sup>3</sup>, Vinayak Rengan<sup>4</sup>

<sup>1</sup>Assistant Professor, <sup>2</sup>Resident, <sup>3</sup>Assistant Professor, <sup>4</sup>Resident

Department of General Surgery, Madras Medical College, Chennai, Tamil Nadu, India

\*Corresponding author email: [nachiappanms@gmail.com](mailto:nachiappanms@gmail.com)

	International Archives of Integrated Medicine, Vol. 5, Issue 5, May, 2018. Copy right © 2018, IAIM, All Rights Reserved. Available online at <a href="http://iaimjournal.com/">http://iaimjournal.com/</a> ISSN: 2394-0026 (P) ISSN: 2394-0034 (O)	
	Received on: 12-04-2018 Source of support: Nil	Accepted on: 19-04-2018 Conflict of interest: None declared.
<b>How to cite this article:</b> Manivannan Dhanraj, Nachiappan Meenakshisundaram, Vinodh Duraisami, Vinayak Rengan. Comparison of various techniques in the management of fistula in ano. IAIM, 2018; 5(5): 14-20.		

## Abstract

**Introduction:** Fistula in ano is the benign anorectal condition, but became a major problem for surgeons to cure the disease. For proper treatment of fistula in ano, a thorough knowledge of Anorectal anatomy and etiopathogenesis of the anorectal abscess is required. More than 90% cases of perianal abscess and anal fistulas occur due to cryptoglandular infections in the intersphincteric plane. Less than 10% occurs due to the complications of Crohn's disease, malignancy, Tuberculosis, and Radiation Exposure.

**The aim of the study:** To study the different modalities of treatment for fistula in ano (Fistulotomy/ Fistulectomy/ Fibrin Glue Injection/ LIFT procedure).

**Materials and methods:** Patients who met inclusion and exclusion criteria for the study selected and all patients discussed the nature of the disease and possible complications (recurrence, anal incontinence, and anal stricture) expected after surgery was explained. Written consent for the study and surgery was obtained. In proforma, thorough history, signs and symptoms, we identified internal opening and external opening by thorough digital rectal examination and proctoscopic examination under the adequate light were noted.

**Results:** In our study, out of those 15 cases of Fistulectomy, 4 cases developed intraoperative bleeding, 3 cases developed sphincter injury and 3 cases had prolonged surgery more than 1 hour. Of 10 cases with Fistulotomy, 3 patients developed intraoperative bleeding, 2 developed sphincter injury and 2 cases had prolonged surgery more than 1 hour. Cases proceeded with Fibrin Glue Injection did not develop any obvious intraoperative complication.

**Conclusion:** Fistulectomy has a moderate degree of intraoperative and postoperative complications with a moderate chance for stricture and incontinence and less chance for recurrence. Moreover few cases required second sitting for the completion of treatment.

## Key words

Fibrin Glue Treatment, Sepsis, Fistulotomy, Fistulectomy.

## Introduction

Fistula in ano is a common, benign treatable condition. Most common cause for fistula in ano is a cryptoglandular infection [1]. Even though 90% of anal fistulas caused by cryptoglandular infection, 10% may occur due to tuberculosis, Crohn's disease, malignancy, actinomycosis, and radiation [2]. Most of the fistula in ano occurs after incision and drainage or spontaneous drainage of the anorectal abscess [3]. An anal fistula is an abnormal, chronic epithelial tract with the internal and external opening. Surgery is the treatment of choice for the eradication of the fistulous tract. The cardinal goals to be considered while treating fistula in ano are as follow: Sepsis should be controlled, Entire fistulous tract should be identified and excised, Sphincter tone should be preserved, so as the continence. It is important to review many older techniques for fistula in ano (fistulotomy, fistulectomy, SETON treatment) and newer techniques (fibrin glue injection, fibrin plug, LIFT procedure, Endoanal advancement flap, stem cell therapy) and their pitfalls [4]. Even though all the above-mentioned techniques are practiced by the surgeons, there are no any high-quality randomized studies available to guide proper decision making about the appropriate procedure. An attempt is made in this study to compare various techniques in the management of fistula in ano and its outcome [5].

## Materials and methods

Patients admitted in Rajiv Gandhi Government General Hospital – Chennai with features of Fistula in Ano between the period of August 2014 to August 2016 were included in the study. Data was collected by thorough history taking, clinical examination, investigations, a collection

of per-operative and postoperative complications, and follow up.

### Inclusion criteria

- All cases presenting with features of simple low anal or high anal fistula in general surgery ward.

### Exclusion criteria

- Patients age < 12 years.
- Complex fistula in ano with multiple internal and external opening and very high anal fistula from our study.
- Patients developed fistula in ano as a complication of inflammatory bowel diseases like Crohn's disease and ulcerative colitis.
- Those patients who developed fistula in ano as a complication of radiation therapy.
- A patient who developed fistula in ano as a complication of extrapulmonary tuberculosis.
- Patients who developed fistula in ano as a complication of anorectal malignancy.

Those cases were internal opening or external opening were not identified, we suggested MRI perineum to trace the entire fistulous tract suggest colonoscopy and CECT abdomen for 6 patients who were the suspects of colonic malignancy. Colonoscopy revealed ulceroproliferative growth at a rectosigmoid junction in 1 case and hence excluded from the study. Colonoscopy was normal in remaining cases and included in the study. We suggest Montoux test and CECT chest in 4 cases who are the suspect for extrapulmonary tuberculosis. Montoux test was negative in all the 4 cases and CT chest revealed fibrotic lesion with cavity formation suggestive of reactivation of pulmonary tuberculosis in one case and hence

excluded from the study. We took wound swab for culture and sensitivity for all cases. Organisms that growing and its antibiotics sensitivity were identified and treated accordingly. All patients optimized before surgery and sepsis kept under control. In our study, of the 50 cases, 30 cases selected for fistulectomy (15) and LIFT procedure (15), and 10 cases each selected for fistulotomy and Fibrin Glue injection treatment. All cases were done under spinal anesthesia. All cases are done in the Lithotomy position. Methylene Blue dye was injected through the external opening to determine the patency of the tract. H<sub>2</sub>O<sub>2</sub> was mixed along with Methylene Blue before injection to increase the chance of identifying internal opening. Because Oxygen-derived free radicals liberate gas through the stenotic internal opening. Gentle probing of the tract through external opening done. After completing the procedure, anal pack kept and T bandage applied. Patients were shifted to the ward and adequate analgesics and antibiotics are given. Oral fluids

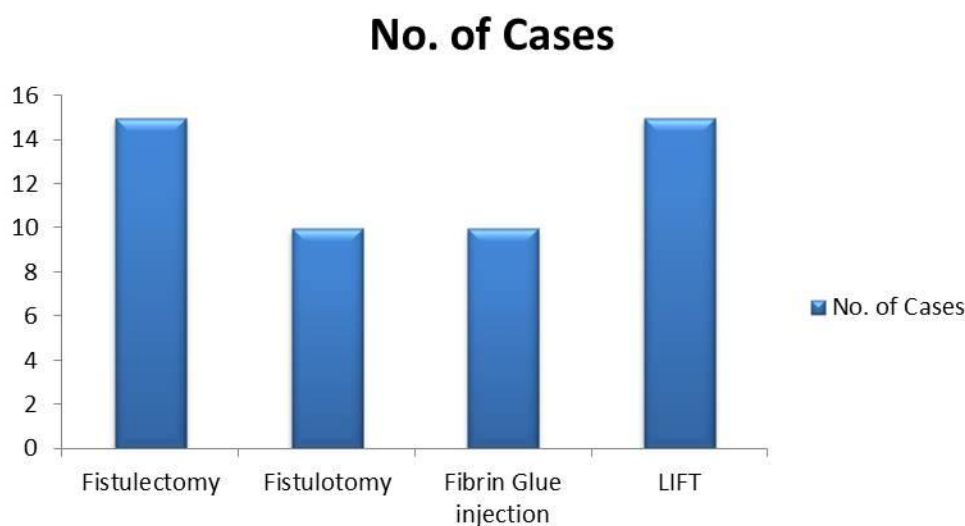
started after 8 hours of surgery. The anal pack was removed on the first postoperative day. Normal diet was started from the 1<sup>st</sup> postoperative day. If patients improved clinically, they were discharged and advised to attend surgical OPD for regular follow up.

## Results

In our study of 50 cases with fistula in ano, about 40 cases (i.e.) 80% of cases have the previous history of Incision and drainage for a perianal abscess. Of those 40 cases, about 25 patients have I, and D history within 1 year of duration, 7 patients have I and D history 1 - 2-year interval, 5 patients have I and D history 2 - 3-year interval and 3 patients have I and D history before 3 years.

In our study of 50 cases of fistula in ano, we had done Fistulotomy in 15 cases, LIFT procedure in 15 cases, SETON treatment in 10 cases and Fistulectomy in 10 cases (**Graph – 1**).

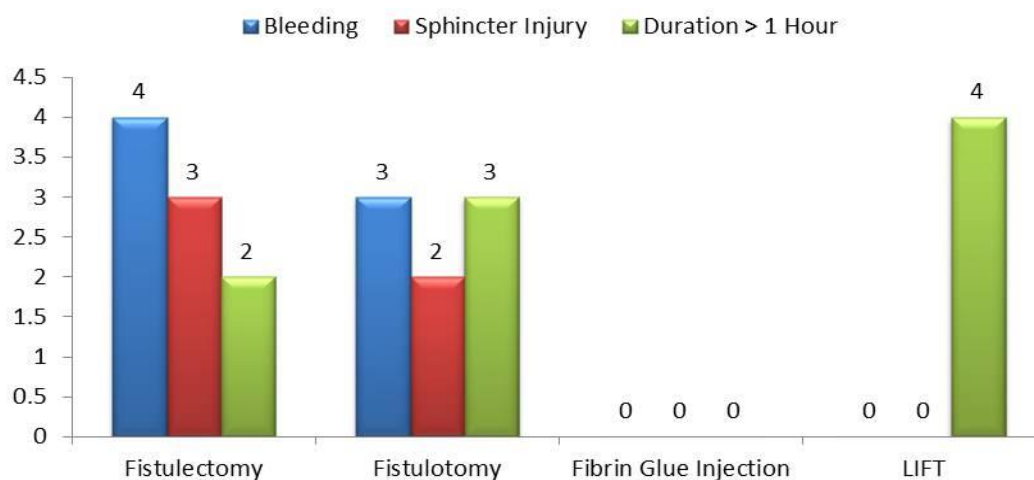
**Graph – 1:** Procedure done.



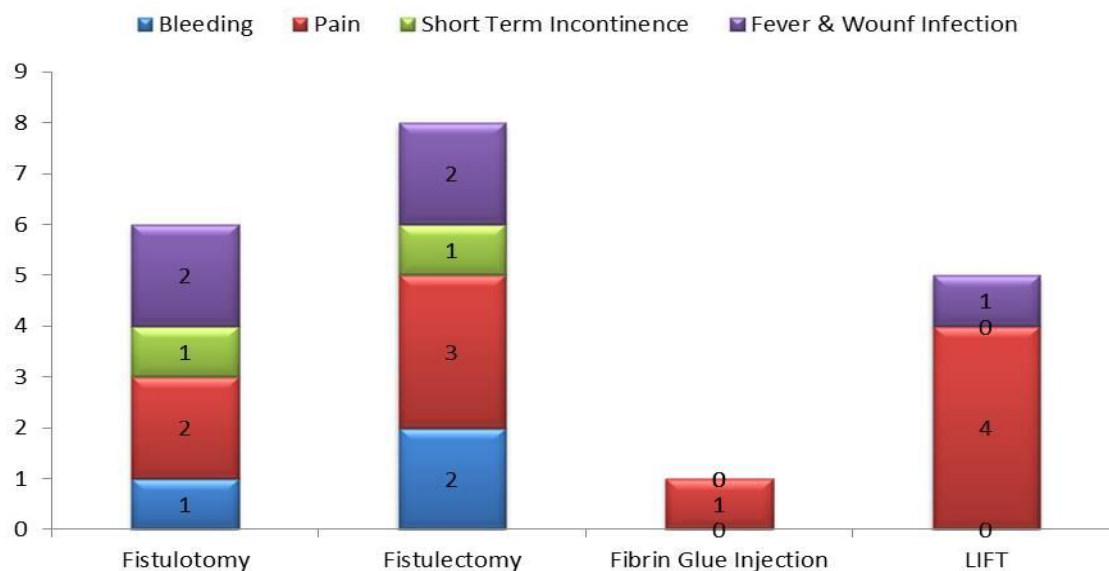
In our study, of those 15 cases of Fistulectomy, 4 cases developed intraoperative bleeding, 3 cases developed sphincter injury and 3 cases had prolonged surgery more than 1 hour. Of 10 cases with Fistulotomy, 3 patients developed intraoperative bleeding, 2 developed sphincter injury and 2 cases had prolonged surgery more

than 1 hour. Cases proceeded with Fibrin Glue Injection did not develop any obvious intraoperative complication. Of 15 cases with LIFT, 4 patients had prolonged surgery more than 1 hour (**Graph – 2**).

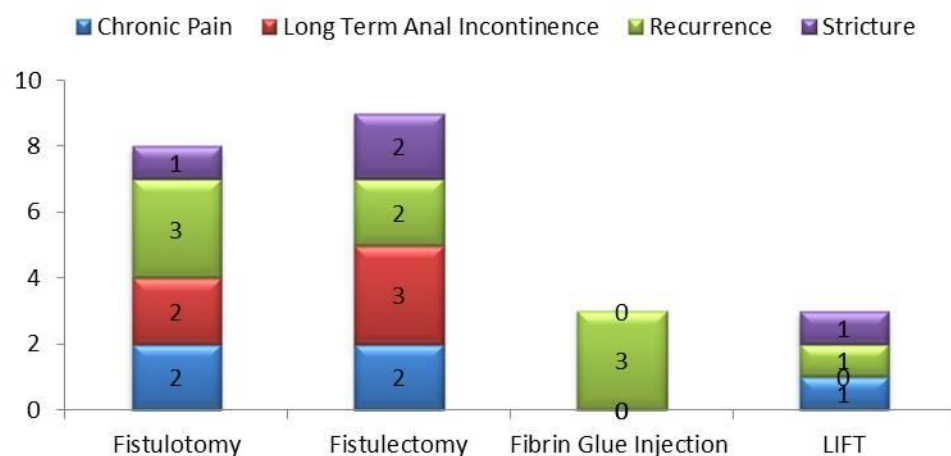
**Graph – 2:** Post-operative complications among patients.



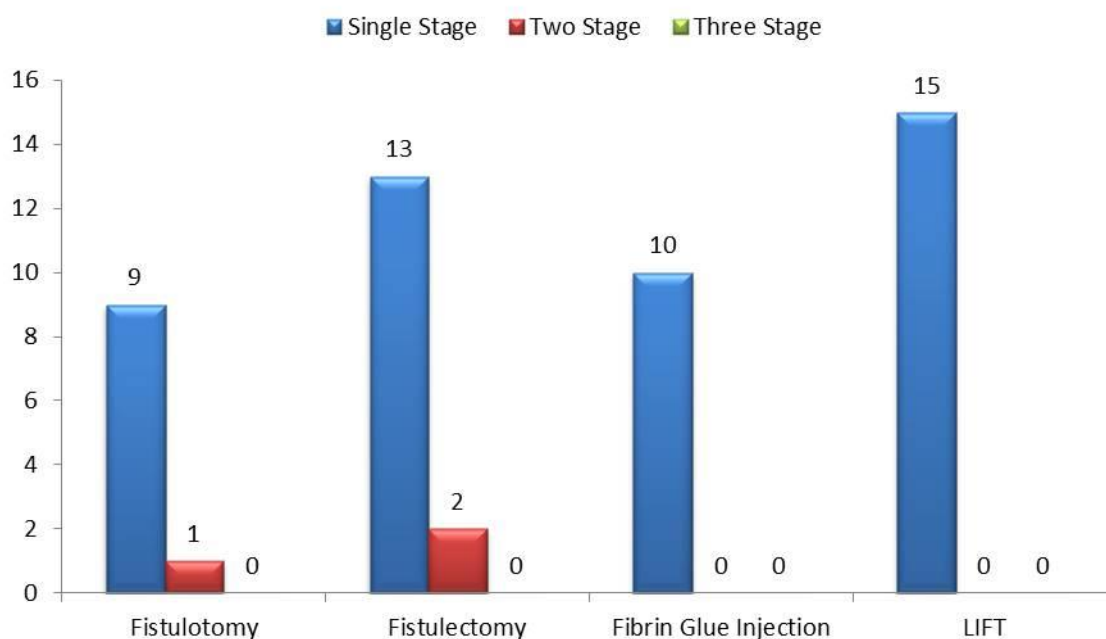
**Graph – 3:** Short term post-operative complications among patients.



**Graph – 4:** Complications on follow up.



**Graph – 5:** Stages of surgery.



In our study, of 10 cases of Fistulotomy, 1 patient developed bleeding postoperatively, 2 patients developed pain, 1 patient developed short-term anal incontinence and 2 patients developed a fever with wound infection. In our study, of 15 cases of Fistulectomy, 2 patients developed bleeding postoperatively, 3 patients developed pain, 1 patient developed short-term anal incontinence and 2 patients developed fever with wound infection. Rarely patients with Fibrin Glue Injection and LIFT procedure developed complications postoperatively. 1 patient with Fibrin Glue developed the pain, 4 patients with LIFT developed pain and 1 patient each with LIFT procedure and Fibrin Glue developed fever and wound infection (**Graph – 3**).

Complications we expected on long term follow up were chronic pain, anal incontinence, recurrence and anal stricture. Chronic pain was seen in, 2 cases of fistulotomy, 2 cases of fistulectomy and 1 cases of LIFT treatment. Long term anal incontinence was seen in 2 cases of fistulotomy and 3 cases of fistulectomy. 3 cases of fistulotomy, 2 cases of fistulectomy and 1 LIFT and 3 Fibrin glue injection procedure encountered recurrence. The anal stricture was

seen in 1 case of fistulotomy and LIFT and 2 cases of fistulectomy (**Graph – 4**).

In our study, treatment was completed in a single stage in all cases of LIFT procedure, Fibrin Glue Injection and most of the cases of fistulotomy and fistulectomy. One case of fistulotomy and two cases of fistulectomy required second sitting for completion of the treatment (**Graph – 5**).

### **Discussion**

In our study also, most of the patients give a history of incision and drainage for a perianal abscess (i.e.) about 80% of the patients gave a history of incision and drainage for perianal abscess and of those about 63% of cases have a history of incision and drainage within 1 year. Only meager (<20%) cases do not have incision and drainage history our study, about 80% patients are males and 20% cases are females. Male / female ratio of fistula in ano is 4:1 [6]. Tan Kk, et al. [7] reported that discharge from the external opening is the most common symptom of fistula in ano. In our study also most common symptom is perianal discharge from the external opening. Nigel Barwood in a prospective study of 107 cases with fistula in ano, he mentions that more than 90% of cases

obeys Goodsall's rule [7]. Similarly in our study also, more than 85% of cases obeys Goodsall's rule. Lunniss PJ and Armstrong P in his study of fistula in ano, mentioned that 72% low anal fistula and 28% are a high anal fistula. In our study of 50 cases, 70% cases are low anal fistula and 30% cases are a high anal fistula [8]. In our study of 50 cases, 30 cases selected for fistulectomy (15) and LIFT procedure (15), and 10 cases each selected for fistulotomy and Fibrin Glue Injection. We observed per operative and immediate postoperative complications in each procedure carefully. Results shows, more complications occur with fistulectomy than other procedures. In most of the cases, we identified both external and internal opening clinically. We offered MRI fistulogram for those cases in which fistula tract is not identified [9]. Ayoub SF, et al. [10] in his study reports that incontinence rate with fistulotomy is about 23%. In our study, long term incontinence rate in fistulotomy case is about 20%. Setaro G, Derosa M in their prospective study of fibrin glue injection treatment for fistula in ano observed that success rate was 76.9% and recurrence rate 23%. In our study recurrence rate for Fibrin, Glue Injection was 30%. Intraoperatively we experienced bleeding in 2 cases of fistulotomy and 4 cases of fistulectomy. Intraoperative Bleeding was not noted in Fibrin Glue Injection and LIFT procedure [10]. Sphincter was injured in 2 cases of fistulotomy and 3 cases of fistulectomy. Sphincter injury was not noted in LIFT procedure and Fibrin Glue Injection treatment. Operating time was extended for more than 1 hour in 2 cases of fistulotomy, 3 cases of fistulectomy and 4 cases of LIFT procedure and Fibrin Glue Injection procedure completed within 1 hour. About 2 patients of fistulotomy, 3 patients of fistulectomy, 1 patient of Fibrin Glue Injection and 4 patients of LIFT procedure experienced postoperative pain for more than 3 days. Post-operative bleeding occurs in 1 patient with fistulotomy and 2 patients with fistulectomy. No patients with LIFT procedure and Fibrin Glue Injection experienced a postoperative Bleeding complication. About 1 patient with fistulotomy and 1 patient with

fistulectomy developed acute temporary anal incontinence which settled down in 3 week time. Patients with LIFT procedure and Fibrin Glue Injection did not experience any incontinence [11]. Post-operative fever wound infection and wound discharge occur in 2 cases of fistulotomy and fistulectomy, 1 case of LIFT procedure which was settled down with the administration of appropriate antibiotics. Patients with fistulotomy discharged on mean hospital stay of 7 days [12]. Mean hospital stay for fistulectomy was 8.5 days, for LIFT procedure was 5 days and for Fibrin Glue Injection was 3 days. LIFT procedure was presented by Rojanasky in 2007 with a healing rate of about 94% [13]. However, later study shows healing rate in LIFT procedure ranges from 57% to 83%. Vesalii Bruxellensis Andreae in 2010 report incontinence rate with LIFT procedure is 0%. In our study healing rate in LIFT procedure is 80% and incontinence rate is 0%, anal stricture rate is 0%. Only 20% cases developed recurrence [14]. Second stage procedure was required for 1 case of fistulotomy and 2 cases of fistulectomy. Hence all cases of LIFT procedure, Fibrin Glue Injection and most of the fistulotomy and fistulectomy cases required single stage surgery [15].

## Conclusion

Fibrin Glue Treatment has no intraoperative and post-operative complications with shorter hospital stay has a moderate recurrence rate. LIFT procedure least or literally no intraoperative or postoperative complications, with a short hospital stay, no risk of anal incontinence or stricture and mild risk of recurrence. Patient able to proceed normal day to day life as early as possible without any inconvenience. So, we conclude that Fistulectomy and LIFT procedure was the acceptable procedures for simple, uncomplicated low lying, and high lying fistula.

## References

1. Abramson DJ. The valves of Houston in Adults. Am J Surg., 1978; 136: 334–336.

2. Shafik A. A new concept of the anatomy of the anal sphincter mechanism and the physiology of defecation. *Investigative Urology*, 1975; 12: 175–182.
3. Oh C, Kark AE. Anatomy of the external anal sphincter. *Br J Surg.*, 1972; 59: 717–723.
4. Bollard RC, Gardiner A, Lindow S, Phillips K, Duthie GS. Normal female anal sphincter: Difficulties in interpretation explained. *Dis Colon Rectum*, 2002; 45: 171–175.
5. Fritsch H, Brenner E, Lienemann A, Ludwikowski B. Anal sphincter complex: reinterpreted. *Dis Colon Rectum*, 2002; 45: 188–194.
6. Jorge JMN, Habr-Gama A. sphincter asymmetry index in anal incontinence. *Int J Colorectal Dis.*, 2000; 15: 303–310.
7. Tan KK, Tan IJ, Lim FS, Koh DC, Tsang CB. The anatomy of failures following the ligation of intersphincteric tract technique for anal fistula. *Dis Colon Rectum*, 2011; 54(11): 1368-1372.
8. Boxall TA, Smart JPG, Griffiths JD. The blood supply of the distal segment of the rectum in the anterior resection. *Br J Surg.*, 1963; 50: 399–404.
9. Miscusi G, Masoni L, Dell’Anna A, Montori A. Normal lymphatic drainage of the rectum and the anal canal. *Coloproctology*, 1987; 9: 171–174.
10. Ayoub SF. Arterial supply of the human rectum. *Acta Anat (Basel)*, 1978; 100: 317–327.
11. Michels NA, Siddharth P, Kornblith PL, Park WW. The variant blood supply to the small and large intestines. *J Int Coll Surg.*, 1963; 39: 127–31.
12. Klosterhalfen B, Vogel P, Rixen H, Mitterman C. Topography of the inferior rectal artery. *A Dis Colon Rectum*, 1989; 32: 43–52.
13. Milligan ETC, Morgan CN. Surgical anatomy of the anal canal. *Lancet*, 1934; 2.
14. Vesalii Bruxellensis Andreae, de Humani corporis fabric. *De Recti intestine muscles*, 1<sup>st</sup> edition, 1543, p. 228.
15. Church JM, Raudkivi PJ, Hill GL. The surgical anatomy and physiology of the rectum *Int J Colorectal Dis.*, 1987; 2: 158–166.