


Original Research Article

# Study on clinical assessment of volume status and correlation to the respiratory variation in inferior vena cava diameter by echocardiography, a non-invasive method of measuring volume status

Gnanaprakasam J<sup>1</sup>, Vasantha Kumar M<sup>2\*</sup>, Praveenkumar M<sup>3</sup>, Lakshmi Priya R<sup>4</sup>

<sup>1</sup>Assistant Professor, <sup>2</sup>Assistant Professor, <sup>3</sup>Post Graduate Student, <sup>4</sup>Post Graduate Student  
Department of General Medicine, Kilpauk Medical College and Hospital, Chennai, Tamil Nadu, India

\*Corresponding author email: [drmvasanth@gmail.com](mailto:drmvasanth@gmail.com)

	International Archives of Integrated Medicine, Vol. 5, Issue 5, May, 2018. Copy right © 2018, IAIM, All Rights Reserved. Available online at <a href="http://iaimjournal.com/">http://iaimjournal.com/</a>	
	ISSN: 2394-0026 (P)	ISSN: 2394-0034 (O)
	Received on: 01-05-2018	Accepted on: 09-05-2018
	Source of support: Nil	Conflict of interest: None declared.
<b>How to cite this article:</b> Gnanaprakasam J, Vasantha Kumar M, Praveenkumar M, Lakshmi Priya R. Study on clinical assessment of volume status and correlation to the respiratory variation in inferior vena cava diameter by echocardiography, a non-invasive method of measuring volume status. IAIM, 2018; 5(5): 104-110.		

## Abstract

**Introduction:** Giving more fluid causes edema and less gives rise to hypoperfusion causing improper delivery of oxygen and substrate leads to cellular dysfunction and multiorgan dysfunction involving the brain, liver, kidneys, heart, lungs and causing death. Diffusion, filtration, osmosis and adequate reabsorption help in continuous exchange of water and solutes among compartment. Daily water intake from the food and water get equalized with losses in the kidneys as urine, from the gastrointestinal system as feces and evaporation of water through lung and skin. Various hormones like Angiotensin II, Aldosterone ADH, Atrial natriuretic peptide maintain sodium and water balance and hence volume status. To maintain normovolemia there is every need for meticulous evaluation for patient Volume status in each patient for adequate volume replacement.

**Aim of the study:** Correlating the Clinical Assessment of Volume Status to the volume assessment By Echocardiography using Respiratory Variation in Inferior Vena Cava Diameter.

**Materials and methods:** Study population consisted of 200 patient of medicine department both inpatient and outpatient of Chengalpattu Medical college. The patient was examined clinically, history suggestive of volume depletion and history suggestive of volume overload were noted, signs and symptoms of both hypovolemia and hypervolemia were noted. Echocardiography was used as a noninvasive method of measuring volume status.

**Results:** Correlation of assessment of volume status by the clinical method and IVC method as low, normal and high was represented. Correlation – 0.797, P value < 0.001 which tell that there was a statistically significant correlation between your two variables. That means, increases or decreases in IVC do significantly relate to increase or decrease.

**Conclusion:** The use of echocardiography as a non-invasive mode of volume assessment is helpful to empower the clinical assessment methods and hence improves diagnostic accuracy.

## Key words

Hypervolemia, Hypovolemia, Echocardiography, Inferior Vena Cava diameter.

## Introduction

Giving the ideal fluid in the ideal time is essential in the management of medical and surgical patients. Giving more fluid causes edema and less gives rise to hypoperfusion causing improper delivery of oxygen and substrate leads to cellular dysfunction and multiorgan dysfunction involving the brain, liver, kidneys, heart, lung and causing death [1]. However, overzealous fluid resuscitation and replacement leads to cellular swelling and extravasation of fluid in the interstitial space causing edema, congestion and distension of organs like lung, liver, heart causing pulmonary edema, hepatomegaly, cardiomegaly and third spacing causing fluid accumulation in part of the body where it is not easily exchanged, like ascites, and pleural and pericardial effusion has been associated with morbidity, organ failure, and death [2]. There is every need for meticulous evaluation in the patient. Volume assessment for each patient is essential for adequate volume replacement [3]. Volume assessment can be done by Clinical methods, Laboratory methods, Invasive monitoring like Central Venous Pressure (CVP) And Pulmonary Artery Occlusion Pressure (PAOP) by catheterization of the internal jugular vein, Arterial waveform analysis [4]. Non-invasive methods by echocardiography looking for IVC diameter and collapsibility with a sniff, Stroke Volume

Variation detected by Arterial cannulation and the Pulse Pressure Variation using the same technique using Thermo-Dilution Principle helps both the Static and Non-Static Measurement of volume evaluation. In this era of evidence-based medicine, there is a need to empower our clinical examination skills with various diagnostic modalities available for accurate assessment of the patient's volume status [5].

## Materials and methods

Study population consisted of 200 patient of medicine department both inpatient and outpatient of Govt Royapettah Hospital, Kilpauk Medical College in the year of 2017-2018. The patients were examined clinically and history suggestive of volume depletion and signs of volume depletion like Sunken eyes, Dry mucose membrane, Slow Skin Recoiling, low volume pulse, Low Blood pressure, Postural Tachycardia, Postural hypotension were noted. History suggestive of volume overload and signs of volume overload like Tachycardia, Hypertension, Jugular Venous Pulse, Basal crepitations, S3-Third Heart Sound were noted. The patient was clinically assessed with signs and symptoms of both hypovolemia and hypervolemia and labelled as low volume status and high volume status, and those without any feature of them were labelled as normal volume status, and at last the Echocardiographic

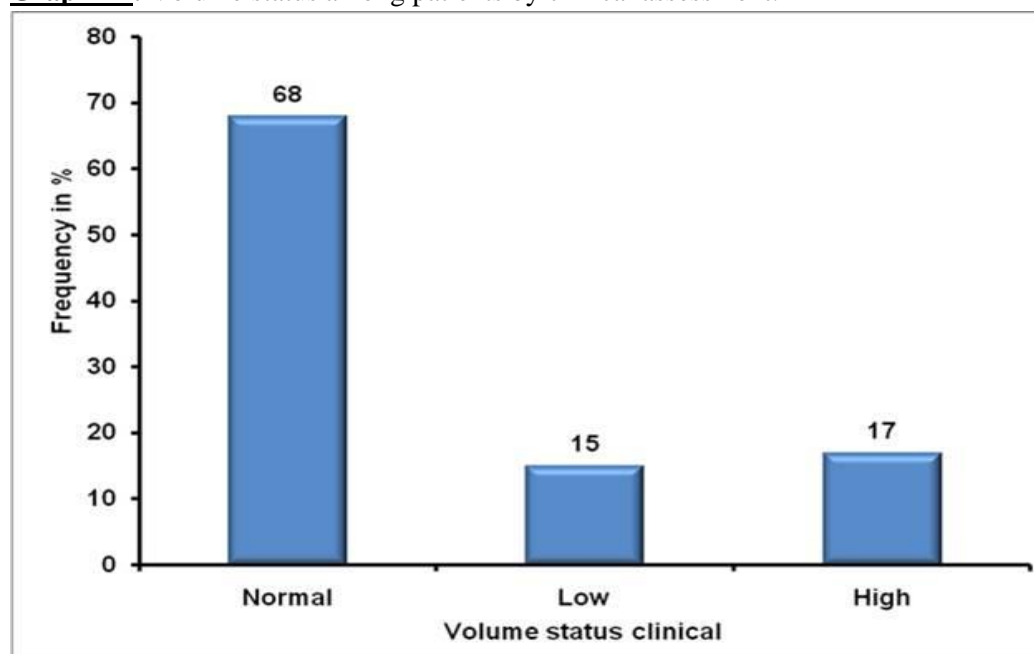
assessment of volume, status was done. Echocardiographic assessment of volume status was done under latest Guidelines for the Echocardiographic Assessment of the Right Heart from the American Society of Echocardiography – 2010. Positioning -supine position. The diameter of the inferior vena cava (IVC) is measured 1-2 cm distal to the junction

of the right atrium, by a subcostal approach in Transthoracic Echocardiography, in which transducer is placed a few centimeters beneath the xiphisternum, slightly right to the midline with the marker point facing the sternal notch. The volume status assessment using the American Society of Echocardiography – 2010 guidelines was followed as per **Table – 1**.

**Table – 1:** American Society of Echochardiography – 2010 guidelines.

Collapsibility with sniff (%)	Volume status	IVC diameter (mm)	Predicted Right Atrial Pressure (mmHG)
Complete collapse	Low volume	< 12	low
>50% collapse	Normal volume	< 21	Normal 3 (0-5)
< 50% collapse	High volume	>21	High (10-15)

**Graph - 1:** Volume status among patients by clinical assessment.



Patients with Signs of increased Intra-abdominal pressure, Respiratory distress, Inability to visualize the IVC, Mechanically ventilated patients were excluded from the study.

## Results

Among 100 patients, 68% had a normal volume of fluid status, low volume status was observed in 15% patients, 17% had high volume status when the volume was assessed by the clinical method as per **Graph – 1**.

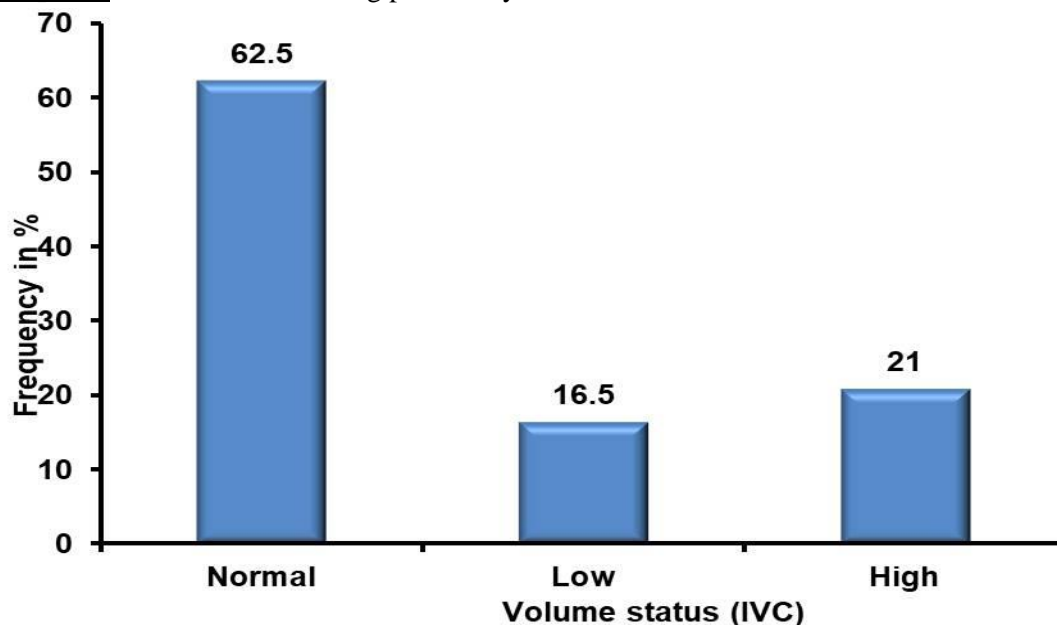
Among 100 patients, 62.5% had a normal volume of fluid status, low volume status was observed in 16.5% patients, 21% had high volume status when the volume was assessed by IVC as per **Graph – 2**.

The study showed there was 92.8 % correlation among the normovolemic, 66.7% with hypovolemic and 78.6% with hypervolemic patients and the overall correlation was 79.7%. Correlation – 0.797, P value < 0.001 which showed that there was a statistically significant

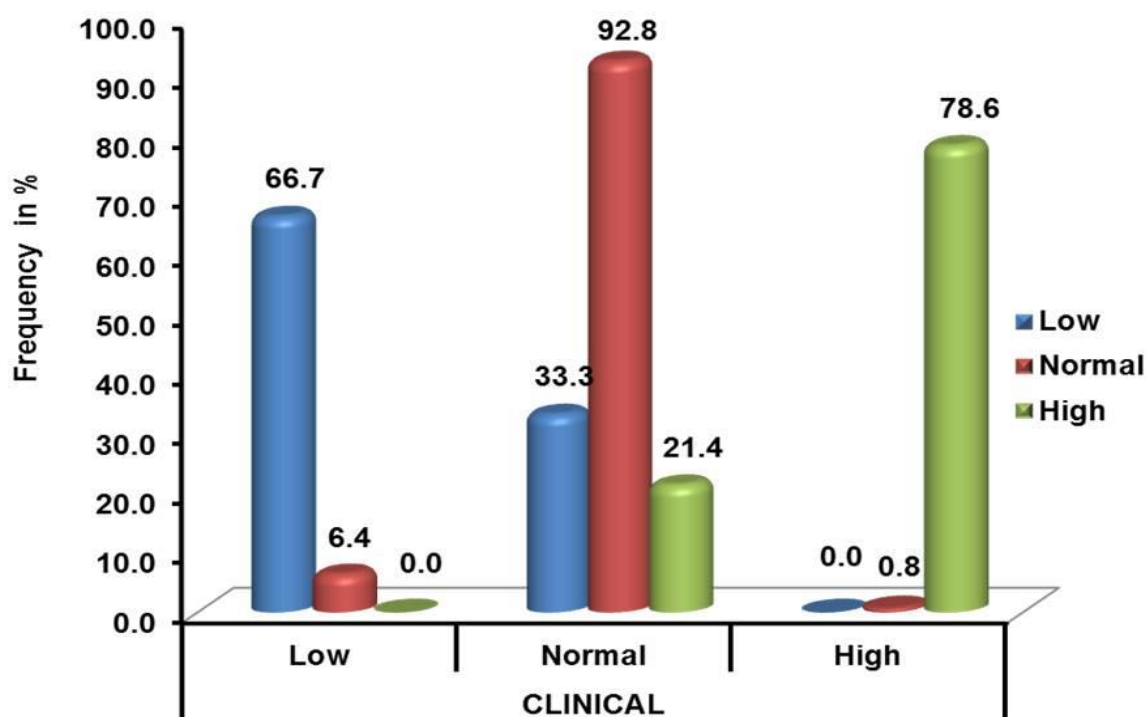
correlation between your two variables. That means increases or decreases in IVC diameter with respiration do significantly relate to increases or decreases in Clinical assessment as per **Graph – 3**. Volume status among patients by

clinical assessment in age-specific population was as per **Graph – 4**. Volume status among patients by IVC diameter assessment in echocardiography image specific population was as per **Graph – 5**.

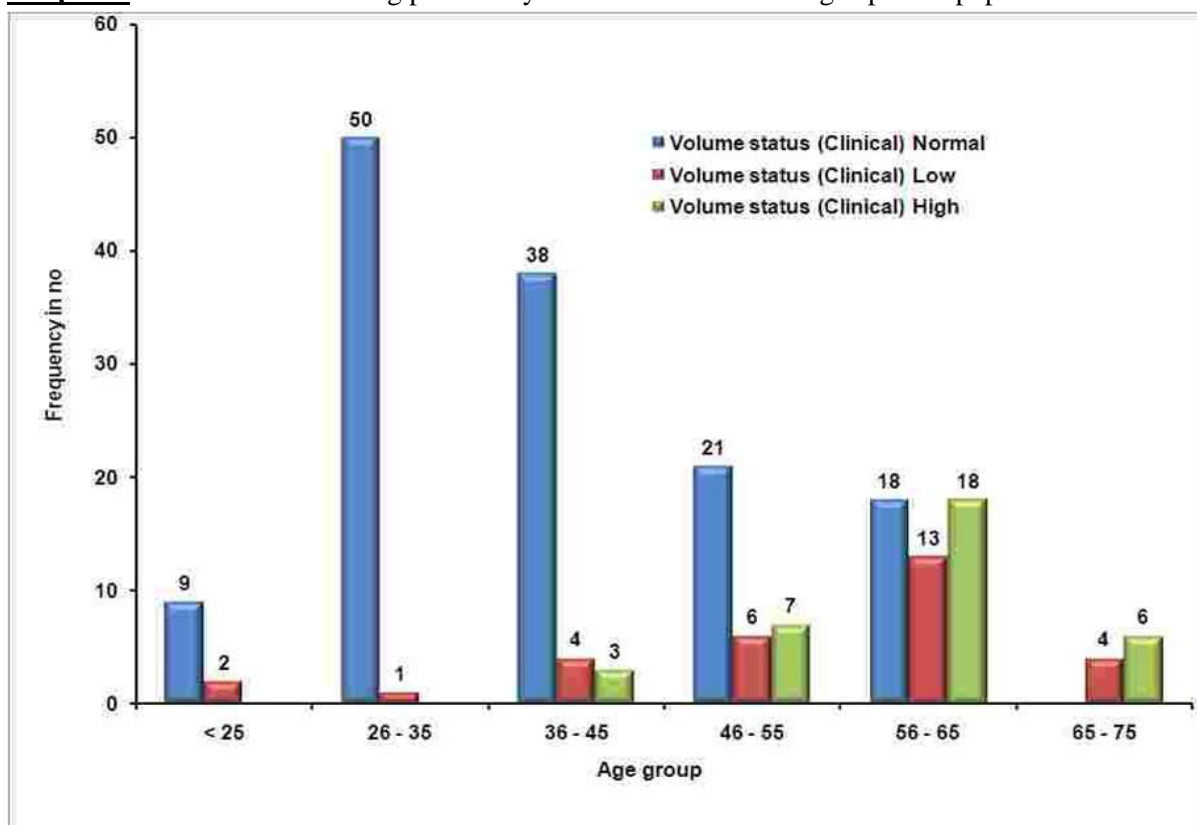
**Graph - 2:** Volume status among patients by IVC diameter assessment.



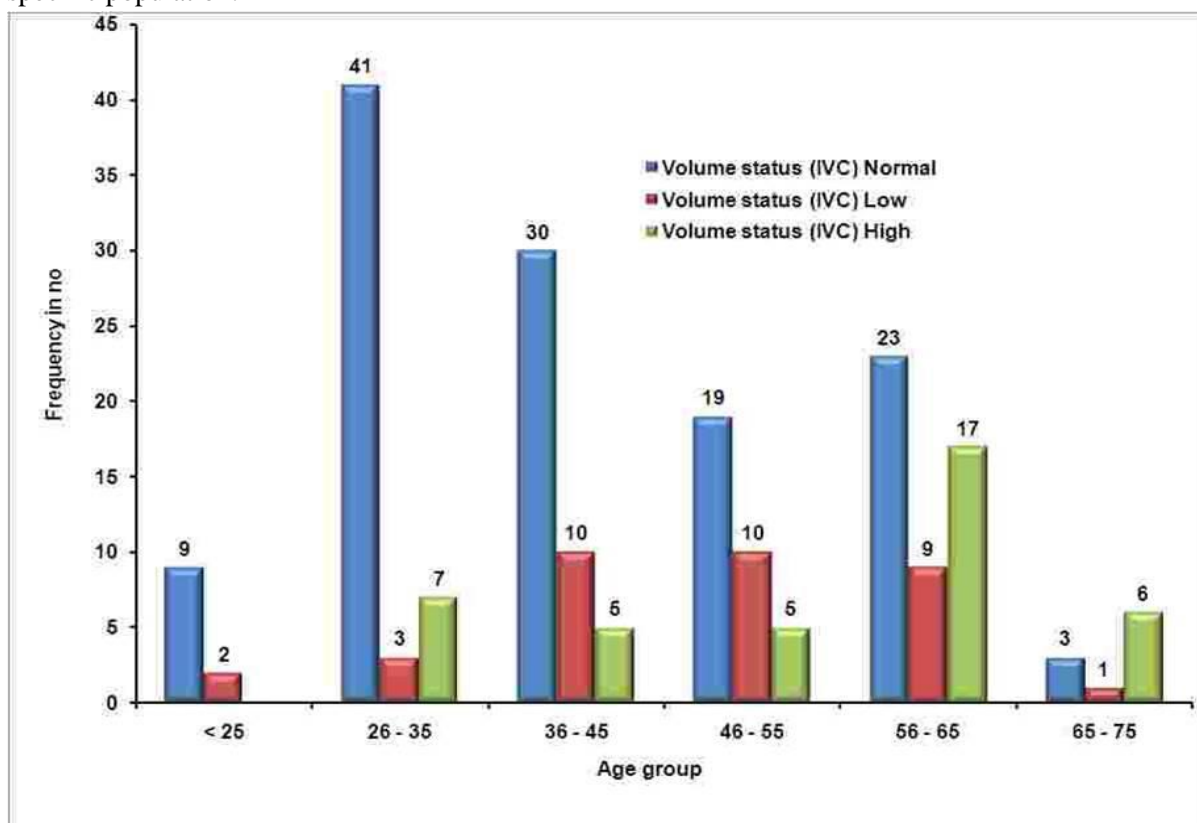
**Graph - 3:** Correlation of assessment of volume status by clinical method and IVC method as low, normal and high is represented below.



**Graph - 4:** Volume status among patients by clinical assessment in age-specific population.



**Graph - 5:** Volume status among patients by IVC diameter assessment in echocardiography image specific population.



## Discussion

The determination of volume status of the patients becomes one of the most important components of patient management in the wards and Intensive Therapy Unit to prevent complications arising from both volume depletion and overload [6]. The clinical assessment of volume inclusive of history will help in this process effectively. But there is a need to confirm the assessment we have made with diagnostic tools either invasive or noninvasive to empower our clinical assessment skills at every time [7]. In this study clinical assessment of volume inclusive of history was correlated with the diameter of the Inferior vena cava and collapsibility with a sniff (short quick inspiratory effort) using echocardiography in subcostal view with M mode. This correlation was not yet done in any of the previous studies [8]. The study showed there is 92.8 % correlation among the normovolemic, 66.7 % with hypovolemic and 78.6 with hypervolemic patients and the overall correlation was 79.7%. Among the remaining 33.3% of the patients who were clinically normal but identified as volume depleted by echocardiography, probably is attributed to the old age [9]. Horng H, et al. in his study also described the age-related decrease in inferior vena cava diameter which is due to age-related decrease in compliance, this would be the same reason in this study also. In the 21.4 of the patients who were clinically normal but the echocardiography showing it as volume overload is probably attributed to the younger age group [10, 11]. David Gaieski, et al. in his study on dilated inferior vena cava showed that young athletes have dilated IVC because of adaptation of extracardiac structures to chronic exercise and it holds the same in this study too. There is a good correlation in this study among the male and female population and as overall, correlations remains the same even in the different age groups [12]. Few clinical trials concluded that the estimation of the volume status of a Patient cannot be relied on only history and clinical examination, as the accuracy ranges between 35 and 45% [13] while other

clinical trials resulted in a reliable estimation of volume status of a patient by history and clinical examination. Certain studies showed bedside non-invasive imaging modalities assisted with a routine physical examination improves the diagnostic accuracy of volume assessment like this study [14, 15].

## Conclusion

The clinical assessment of volume status in this study correlated well with the assessment of volume status by the subcostal method of echocardiography using respiratory variation in Inferior Vena Cava Diameter. Non-invasive mode of volume assessment by inferior vena cava diameter using echocardiography is a helpful tool to assess the patient's volume status.

## References

1. Ronald Maier, Approach to shock, Harrison's Principles of Internal Medicine, 18<sup>th</sup> edition, McGraw Hill, chapter 270; p. 2215.
2. Vincent JL, Sakr Y, Sprung CL, et al. Sepsis in European intensive care units: results of the SOAP study. Crit Care Med., 2006; 34: 344–353.
3. The National Heart, Lung, and Blood Institute Acute Respiratory Distress Syndrome (ARDS) Clinical Trials Network. Comparison of two uid-management strategies in acute lung injury. N Engl J Med., 2006; 354: 2564–2575.
4. Mintz GS, Kotler MN, Parry WR, Iskandrian AS, Kane SA. Real-time inferior vena cava ultrasonography: normal and abnormal findings and its use in assessing right-heart function. Circulation, 1981; 64: 1018–25.
5. Brennan JM, Blair JE, Goonewardena S, et al. Reappraisal of the use of inferior vena cava for estimating right atrial pressure. J Am Soc Echocardiogram, 2007; 20: 857– 86.

Gnanaprakasam J, Vasantha Kumar M, Praveenkumar M, Lakshmi Priya R. Study on clinical assessment of volume status and correlation to the respiratory variation in inferior vena cava diameter by echocardiography, a non-invasive method of measuring volume status. IAIM, 2018; 5(5): 104-110.

6. Wiwatworapan W, et al. Correlation between inferior vena cava diameter and central venous pressure in critically ill patients. J Med Assoc Thai, 2012; 95(3): 320-4.
7. Gerald J. Tortora. Principles of anatomy and physiology, Wiley publishers, 2009, Chapter 27: Fluid, electrolyte, and acid-base homeostasis.
8. William F. Ganong. Review of Medical Physiology, twenty-first edition, chapter 1; Introduction.
9. Robbins' basic pathology, 9<sup>th</sup> edition; Chapter 3 Hemodynamics disorders, thromboembolism, Shock.
10. William F. Ganong. Review of Medical Physiology, twenty-first edition; chapter 24. Endocrine Functions of the Kidneys, Heart, & Pineal Gland.
11. Horng H. Chen, Robert W. Schrier. Pathophysiology of Volume Overload in Acute Heart Failure Syndromes. The American Journal of Medicine, 2006; 119(12A): S11–S16.
12. David Gaieski, Scott Manaker. General evaluation and differential diagnosis of shock in adults, 2005.
13. Marik P.E. Hand book of evidence-based critical care, 2010.
14. Long More M. Wilkinson oxford handbook of clinical medicine, 7<sup>th</sup> edition, 2007, p. 24-27.
15. Dornon T, Oneill P. Core clinical skills for use in medicine, 2<sup>nd</sup> edition, p. 160-162.