

## Original Research Article


# Study of various X-ray presentations for the symptom of cough of more than 2 weeks duration in a tertiary care hospital

A. Shaik Sulaiman Meeran<sup>1</sup>, Anuradha Hariharan<sup>2\*</sup>, M. Praveenkumar<sup>3</sup>

<sup>1</sup>Professor, <sup>2</sup>Assistant Professor, <sup>3</sup>Junior Resident

Department of General Medicine, Government Royapettah Hospital, Government Kilpauk Medical College, Chennai, Tamil Nadu, India

\*Corresponding author email: [doctoranu28@gmail.com](mailto:doctoranu28@gmail.com)

	International Archives of Integrated Medicine, Vol. 5, Issue 10, October, 2018. Copy right © 2018, IAIM, All Rights Reserved. Available online at <a href="http://iaimjournal.com/">http://iaimjournal.com/</a>	
	ISSN: 2394-0026 (P)	ISSN: 2394-0034 (O)
	Received on: 11-09-2018	Accepted on: 18-09-2018
	Source of support: Nil	Conflict of interest: None declared.
<b>How to cite this article:</b> A. Shaik Sulaiman Meeran, Anuradha Hariharan, M. Praveenkumar. Study of various X-ray presentations for the symptom of cough of more than 2 weeks duration in a tertiary care hospital. IAIM, 2018; 5(10): 10-13.		

## Abstract

**Background:** A cough can be the result of a respiratory tract infection such as the common cold, acute bronchitis, pneumonia, pertussis, or tuberculosis. In the vast majority of cases, acute coughs, i.e. coughs shorter than 3 weeks, are due to the common cold. In people with a normal chest X-ray, tuberculosis is a rare finding. Pertussis is increasingly being recognized as a cause of troublesome coughing in adults.

**Aim:** It was diagnosed mainly by simple sputum acid-fast staining, and in some cases, gene expert was needed to prove the diagnosis for starting ATT

**Materials and methods:** This observational study was conducted in Govt. Royapettah Hospital, Chennai, included patients presenting with >2 weeks duration of a cough irrespective of age and sex. Among 45 patients for a chronic cough, with X-ray finding, the diagnosis was confirmed by other radiological and laboratory methods.

**Results:** Among other infective causes, major organisms causing pneumonia was Klebsiella pneumonia, Streptococcus pneumonia, and E.coli. All these patients were treated with culture-specific antibiotics and recovered. 7 patients (14%) were admitted for a chronic lung in X-ray. All these patients were chronic smokers and had a cough for the long term with minimal mucoid sputum production.

**Conclusion:** Thus from our observational study it was concluded that Tuberculosis is still the most common etiology for a chronic cough, and how simple X-ray could guide us to diagnosis is seen

## Key words

X-ray, Symptom, Cough, 2 week.

## Introduction

A cough is a common symptom of many respiratory illnesses, and also other systemic illness. Although most cough is short lived and self-limiting those that persist have an impact on the quality of life. Patients with a chronic cough are usually a diagnostic challenge [1]. Although infective etiology is the most common cause for a cough, many other noninfective conditions also present with a cough. A single chest X-ray can direct us to make a diagnosis and treatment. This study explained the various X-ray presentation of a chronic cough for more than 2 weeks [2].

## Aim of the study

- To study the various X ray presentations for chronic cough, and to observe how a simple X-ray could guide to diagnosis and management.

## Materials and methods

This observational study was conducted in Govt. Royapettah Hospital, Chennai, included patients presenting with >2 weeks duration of a cough irrespective of age and sex. Total of 45 patients who presented with >2 weeks of a cough was admitted as an inpatient and evaluated. Exclusion criteria included as patients on ACE therapy, a

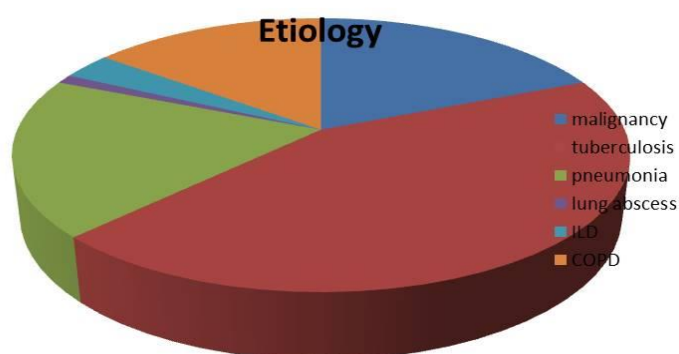
cough <2 weeks duration and patients who were recently treated for a cough.

## Results

Among 45 patients for a chronic cough, with X-ray finding, the diagnosis was confirmed by other radiological and laboratory methods.

It was diagnosed mainly by simple sputum acid-fast staining, and in some cases, gene expert was needed to prove the diagnosis for starting ATT. Next common cause was malignancy (an endobronchial tumor, bronchogenic carcinoma, lung secondaries) mainly diagnosed by CT Chest and biopsy (CT guided, BAL). Pleural cytology for malignant cells was positive in 3 cases. Among other infective causes, major organisms causing pneumonia was Klebsiella pneumonia, Streptococcus pneumonia, and E.coli. All these patients were treated with culture-specific antibiotics and recovered. 7 patients (14%) who were admitted for a chronic cough but their laboratory and radiological parameters were normal except emphysematous lung in X-ray. All these patients were chronic smokers and had a cough for the long term with minimal mucoid sputum production. They were diagnosed as chronic bronchitis and treated (**Table – 1, Graph – 1**).

**Graph – 1:** Etiological finding.



**Table – 1:** X-ray findings among cases.

X-ray finding	Diagnosis (cause)	No. of patients	%
Pleural effusions	Tuberculosis, pneumonia, Malignancy	9	26.6%
Emphysematous changes	COPD	7	
Pneumothorax	Tuberculosis	3	6.66%
Bronchiectatic changes (honeycomb appearance)	Tuberculosis	6	15.5%
Hydropneumothorax	Malignancy, Tuberculosis	2	4.4%
Thin-walled cavity	Tuberculosis	4	11.1%
Thickly walled cavity	Lung abscess	1	2.2%
Collapsed lung	Malignancy	3	13.3%
Cannonball appearance	Malignancy	2	
Multiple fluffy opacities	Tuberculosis, pneumonia	6	15.5%
Reticonodular pattaern	Interstitial lung disease	3	8.88%
Fibrosis	Tuberculosis	4	11.1%

## Discussion

A cough is an essential protective function for human airways and lungs. Without an effective cough reflex, we are at risk for retained airway secretions and aspirated material predisposing to infection, atelectasis and respiratory compromise [3]. The duration of a cough is a clue to its etiology. An acute cough (<3 weeks) is most commonly due to respiratory tract infections, aspiration, inhalation of noxious chemicals or smoke. A subacute cough (3-8 weeks in duration) is a common residuum of tracheobronchitis, as in pertussis or “postviral tussive syndrome “. A chronic cough (>8 weeks) may be caused by a wide variety of cardiopulmonary diseases, infections, neoplastic and cardiovascular etiologies [4]. With initial assessment with chest examination and radiography, it was found normal, cough variant asthma, GERD, nasopharyngeal drainage and medications (ACE inhibitors) are the most common causes of a chronic cough [5]. Cough receptors are located in the respiratory tract from the hypopharynx and larynx to the segmental bronchi. 3 Several different types of sensory nerve receptors respond to chemical, mechanical, Inflammatory or thermal stimuli activating cough receptors connected to the vagal afferent nerve [6]. A cough center in the medulla receives signals from these activated cough receptors via afferent fibers in the vagus nerve [7]. Voluntary

inhibition or production of a cough is possible because of the influence of higher cortical centers on this cough center. Efferent signals are then sent to the muscles that produce the expiratory effort. WHO guidelines of systematic screening for active tuberculosis 5 describe 10 algorithms for screening TB. Eight options include symptom screening and two options use chest X-ray as the initial screening test [8, 9, 10].

## Conclusion

Thus from our observational study it was concluded that Tuberculosis is still the most common etiology for a chronic cough, and how simple X-ray could guide us to diagnosis is seen. If symptom screening is used initially, then chest X-ray can be used as a second screen to improve the pre-test probability of the subsequent diagnostic test and to reduce the number of people who need to undergo further diagnostic evaluation.

## References

1. Pratter M. R., Brightling C. E., Boulet L. P., Irwin R. S. An empiric integrative approach to the management of a cough: ACCP evidence-based clinical practice guidelines. Chest, 2006; 129: 222S–231S.

2. Morice A. H., McGarvey L., Pavord I. Recommendations for the management of a cough in adults. *Thorax*, 2006; 61(Suppl 1): i1–i24.
3. Chung K. F., Pavord I. D. Prevalence, pathogenesis, and causes of a chronic cough. *Lancet*, 2008; 371: 1364–1374.
4. Morice A. H., et al. The diagnosis and management of a chronic cough. *Eur. Resp. J.*, 2004; 24: 481–492.
5. Irwin R. S., French C. T., Lewis S. Z., Diekemper R. L., Gold P. M. Overview of the management of a cough: CHEST guideline and expert panel report. *Chest*, 2016; 146: 885–889.
6. Ojoo J. C., et al. Management of patients with a chronic cough using a clinical protocol: a prospective observational study. *Cough*, 2013; 9: 2–4.
7. Mackley R., Schatzberger T., Parker S. Management of a chronic cough in primary care [abstract]. *Thorax*, 2013; 68: A20.
8. Harding R., et al. Primary care management of chronic cough. *Eur. Resp. J.*, 2014; 42: 683s.
9. Levy M. L., et al. Diagnostic spirometry in primary care: proposed standards for general practice compliant with American Thoracic Society and European Respiratory Society recommendations. *Prim. Care Respir. J.*, 2009; 18: 130–147.
10. Birring S. S. Controversies in the evaluation and management of a chronic cough. *Am. J. Respir. Crit. Care Med.*, 2011; 183: 708–715.