

Original Research Article


Comparative study of Hepatico-duodenostomy Vs. Hepatico-jejunostomy surgical procedures in the management of choledochal cyst in children

K.V. Sathyanarayana¹, Sri Aparna Mummaneni^{2*}

¹Assistant Professor, ²Senior Resident

Department of Pediatric Surgery, Osmania Medical College, Niloufer Hospital for Women and Children, Telangana, India

*Corresponding author email: kvsn.kotte@gmail.com

	International Archives of Integrated Medicine, Vol. 5, Issue 10, October, 2018. Copy right © 2018, IAIM, All Rights Reserved. Available online at http://iaimjournal.com/	
	ISSN: 2394-0026 (P)	ISSN: 2394-0034 (O)
	Received on: 11-09-2018	Accepted on: 17-09-2018
	Source of support: Nil	Conflict of interest: None declared.
How to cite this article: K.V. Sathyanarayana, Sri Aparna Mummaneni. Comparative study of Hepatico-duodenostomy Vs. Hepatico-jejunostomy surgical procedures in the management of choledochal cyst in children. IAIM, 2018; 5(10): 127-137.		

Abstract

Background: Choledochal cyst is a congenital anomaly of the ducts of the extrahepatic biliary tree. This condition is considered rare in the view of western population with an incidence of 1 in 100,000 to 150,000 births, while it defers in the Asian population where in the incidence is nearly 1 in 1000 live births.

Aim: To compare and assess the advantages and disadvantages between the two standard procedures in the surgical management of choledochal cyst in children.

Materials and methods: The required sample size was collected prospectively over a period of two years from November 2014 to October 2016. The decision for biliary-enteric anastomosis (Hepatico-duodenostomy Vs. Hepatico- jejunostomy) made was not influenced or directed by the study. The type of anastomosis was left to the surgeon's personal preference in each case. 15 cases of each type of biliary-enteric anastomosis – Hepatico-duodenostomy and Hepatico-jejunostomy were chosen.

Results: The age distribution in cases undergoing hepatico-duodenostomy was almost near to equal, female to male ratio was of 1.25: 1. Out of 15 patients 5 in hepatico-duodenostomy group and 3 in hepatico-jejunostomy had a palpable mass in the right upper quadrant. This means that a palpable mass was seen in 26% of our patients who present for surgical correction of a CC. Second most important presenting complaint in CC was pain. Thirteen out of 30 children presented with bilious vomiting. On an average, we had initiation of feeds in the hepatico-duodenostomy group was of 5

days and that of the hepatico-jejunostomy group was of 7 days. Average stay for the hepatico-duodenostomy group was around 7.6 days when compared to 10.5 days in the hepatico-jejunostomy group. One case in hepatico-jejunostomy group was seen to have bile leak on the 4th post-operative day. No other early complications were seen in the hepatico-duodenostomy group. One child belonging to hepatico-duodenostomy group had been admitted three months post-operatively with the complaint of recurrent pain abdomen and fever. In cases of hepatico-duodenostomy, none of them presented with any symptoms of pain abdomen or recurrent vomiting.

Conclusion: Our results also support HD as the preferred procedure for biliary reconstruction after resection of CC, in view of the advantages of relative simplicity, and low rate of complications.

Key words

Choledochal cyst (CC), Hepatico-duodenostomy (HD), Hepatico-jejunostomy (HJ).

Introduction

Choledochal cyst is a congenital anomaly of the ducts of the extrahepatic biliary tree. This condition is considered rare in the view of western population with an incidence of 1 in 100,000 to 150,000 births [1], while it defers in the Asian population where the incidence is nearly 1 in 1000 live births [2]. Continuity in the biliary tract is achieved by performing two standard procedures, Hepaticoduodenostomy – direct anastomosis of the bile duct to the duodenum and Hepaticojejunostomy with creation of Roux-en-Y loop jejunum.

The procedure of preference is not clear as various surgeons follow their own methods for their own reasons. Not many series have shown the Indian pediatric demography of choledochal cyst that compares the two procedures. We in our institute have been performing both the procedures since the past. This study projected the demography and the presenting complaints in our institute. We tried to compare the outcomes after either of the two procedures and signify the differences between the early and late complications individually and combined. Postoperative complications were screened by a pre-written proforma which were interviewed the patient during follow up.

A description of the radiological features and complicated presentations were also noted. Analysis that compares the outcomes of the two groups of patients were done – early, late and a

combined complication rate. At the end of the study, we described how children present to us with choledochal cyst and how they do, after having undergone either of the two types of biliary enteric anastomosis. We suggested if any one procedure is better.

Materials and methods

A prospective study of a total of 30 cases had been analysed over a period of 2 years from November 2014 – October 2016. A planned research methodology had been devised for the study between the two standard procedures done for choledochal cyst. All children who underwent surgery for choledochal cyst in the department of pediatric surgery in Niloufer hospital were included.

All cases of type I and type IV choledochal cyst that have undergone surgery in our department of pediatric surgery had been included in the study. Children with type II, III and type V choledochal, patients who had undergone surgery elsewhere and presented here for complications, Patients who had undergone procedures, other than the two prescribed methods, like incomplete cyst excision had been excluded from our study.

Demographic study we had recorded are, Age at presentation, Sex distribution, Presenting complaints as Pain, Jaundice, Palpable mass, Pale stools, Vomiting and Fever.

Intra-operative outcomes were taken as Duration of surgery and Requirement of blood transfusions.

Immediate postoperative course taken as Onset of oral feeds, Bile leak, Cholangitis, Normal coloured stools, Wound infections and Length of hospital stay were studied.

Laboratory data as Total bilirubin levels and Biopsy report were taken. Long term follow up of Recurrent pain abdomen episodes, Abdominal distension with vomiting, Recurrent epigastric pain episodes, Need for re-exploration, Abnormal liver function tests and Upper GI endoscopy.

Results

The required sample size was collected prospectively over a period of two years from November 2014 to October 2016. The decision for biliary-enteric anastomosis (Hepatico-duodenostomy Vs. Hepatico- jejunostomy) made was not influenced or directed by the study. The type of anastomosis was left to the surgeon's preference in each case. Fifteen cases of each type of biliary-enteric anastomosis – Hepatico-duodenostomy and Hepatico-jejunostomy were chosen. Cases where other modalities used – such as the Lilly's procedure, drainage of cysts (tube drainage) were excluded from our sample collection as there was a potential for bias in their selection and outcomes.

The age distribution in cases undergoing hepatico-duodenostomy was almost near to equal according to the age group classification taken. The mean age of undergoing surgery was 52.8 months for those of the hepatico-duodenostomy group and 59.8 months for those undergoing hepatico-jejunostomy (**Table – 1, Figure – 1**).

The sex ratio was a carefully studied baseline characteristic in CC. The hepatico-duodenostomy group had 9 girls and 6 boys and the same pattern of female and male distribution has been

seen in hepatico-jejunostomy group with a female to male ratio of 1.25: 1.

The typical presentation of CC, as described by many authors, is right upper quadrant mass. In our series, right upper quadrant mass was found in 5 of 15 in hepatico-duodenostomy group and 3 in hepatico-jejunostomy group (**Figure – 2**). This means that a palpable mass was seen in 26% of our patients who present for surgical correction of a CC.

Table - 1: Baseline Characteristics.

	Hepatico-duodenostomy	Hepatico-jejunostomy
Age	52.8 months	59.8 months
Sex (F:M)	1.5:1	1.5:1
Palpable mass RUQ	5/15	3/15
Pain	8/15	5/15
Jaundice	4/15	3/15
Vomiting	6/15	7/15
Pale stools	2/15	0/15
Fever	3/15	5/15
Spontaneous rupture	0/15	1/15
Type	13/15 type 1 2/15 type 4	14/15 type 1 01/15 type 4
Cyst wall	4 cm	5 cm
Other features	2 cases of pancreatitis 2 choledocholithiasis	1 ruptured cyst 2 accessory ducts, pancreatic divisum 1 Post ERCP stenting

Pain

The second most important presenting complaint in CC was pain in the triad of symptoms. From a total of 30 cases 13 patients, 8 from Hepatico-duodenostomy group and 5 from Hepatico-duodenostomy group presented with pain in the right upper quadrant.

Jaundice

The classical triad of clinical presentation in CC was pain, palpable mass and jaundice. This

classical triad was seen only in 3 cases and individually as a presenting complaint was seen in 7 cases altogether (**Figure – 3**).

Vomiting

The other major presenting complaint was recurrent episodes of bilious vomiting. Thirteen out of 30 children presented with bilious vomiting.

Size of the cyst

The size of the cyst was an important factor in the diagnosis of the type of disease and plays a major key role in determining the surgical procedure. The size of choledochal cyst were either recorded/ derived from the preoperative imaging (ultrasonography, CT, MRI) or intraoperative assessment of the cyst.

Figure - 1: Age distribution.

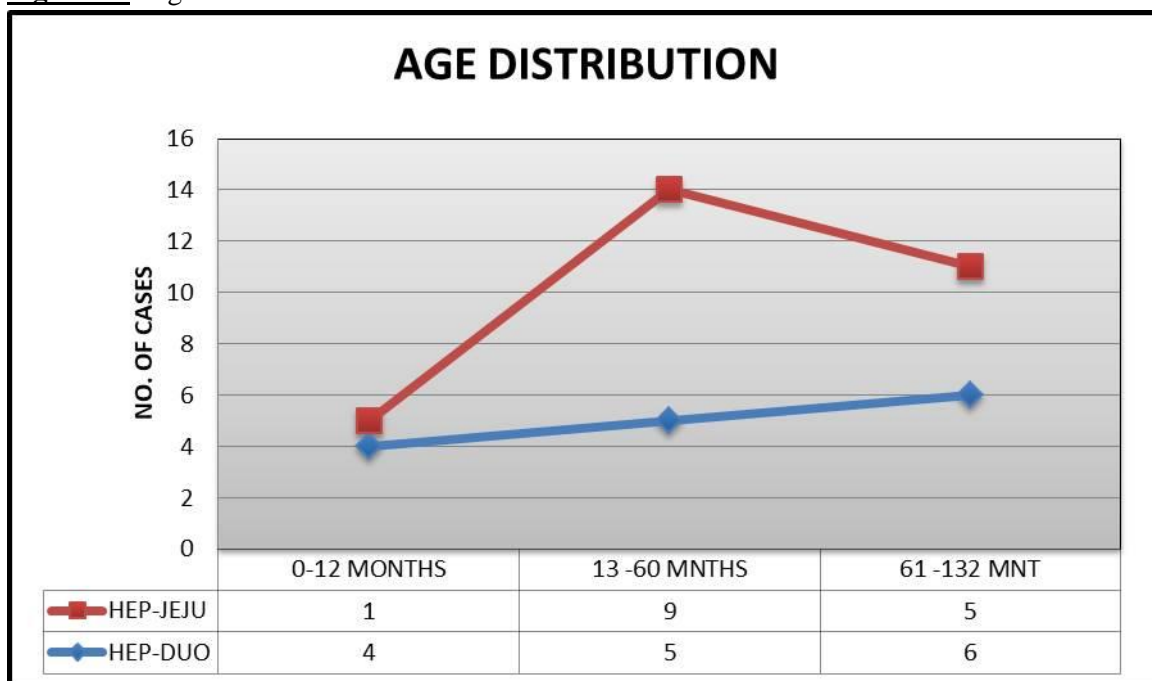


Figure - 2: Palpable right upper quadrant mass.

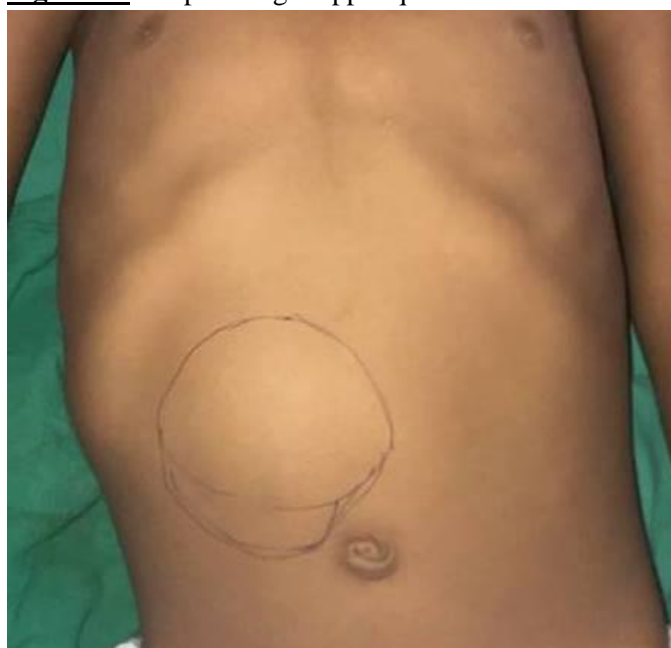

Figure - 3: Triad of symptoms.

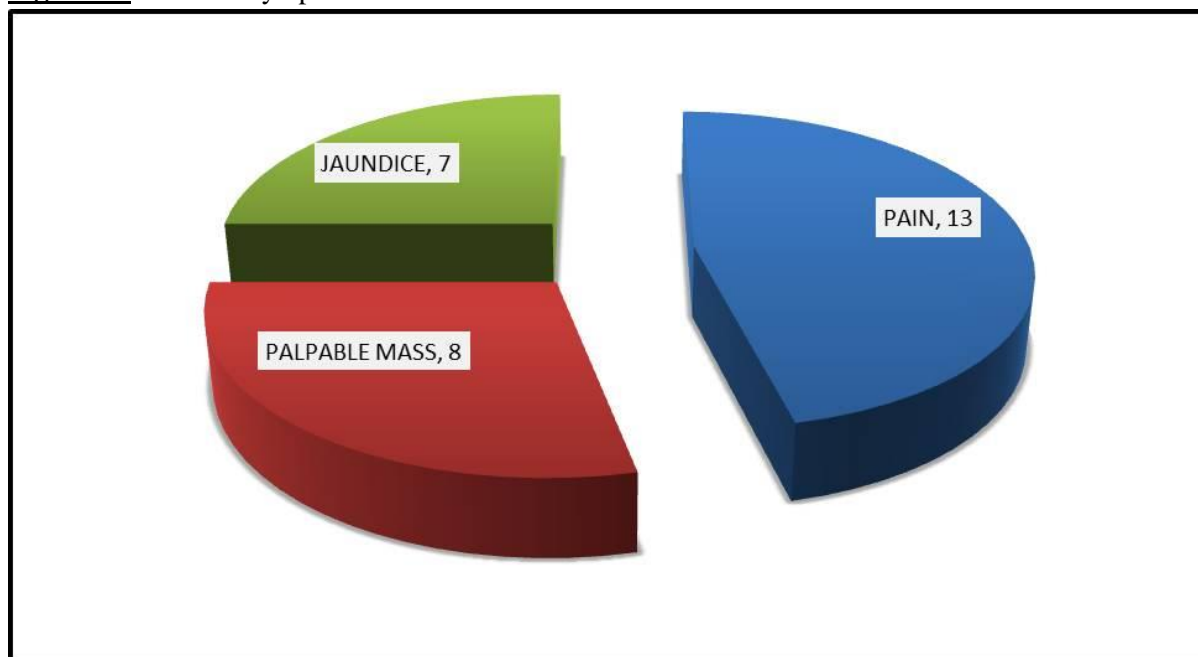


Table - 2: Serum Bilirubin.

Serum bilirubin in mg/dL	Hepatico-duodenostomy	Hepatico-jejunostomy
0.2-1.0	7	8
1.1-2.0	3	2
2.1-10.0	3	3
>10.0	0	1

The average size of choledochal cyst in Hepatico-duodenostomy group was 43 mm. the range of the cyst size measured from 15 mm to 120 mm in size in 13 cases. The Hepatico-jejunostomy group had the size of the choledochal cyst recorded in 10 /15 patients with an average size of the cyst 33 mm and the range of 12-80 mm.

Choledocholithiasis

Only 2 out of the 30 cases were preoperatively assessed to have stones in the biliary tree with the help of CT. Both the cases belonged to the Hepatico-duodenostomy group and were treated with saline irrigation with a catheter to flush them out of the system and none of the patients were found to have residual stones or complications of retained stones during follow up.

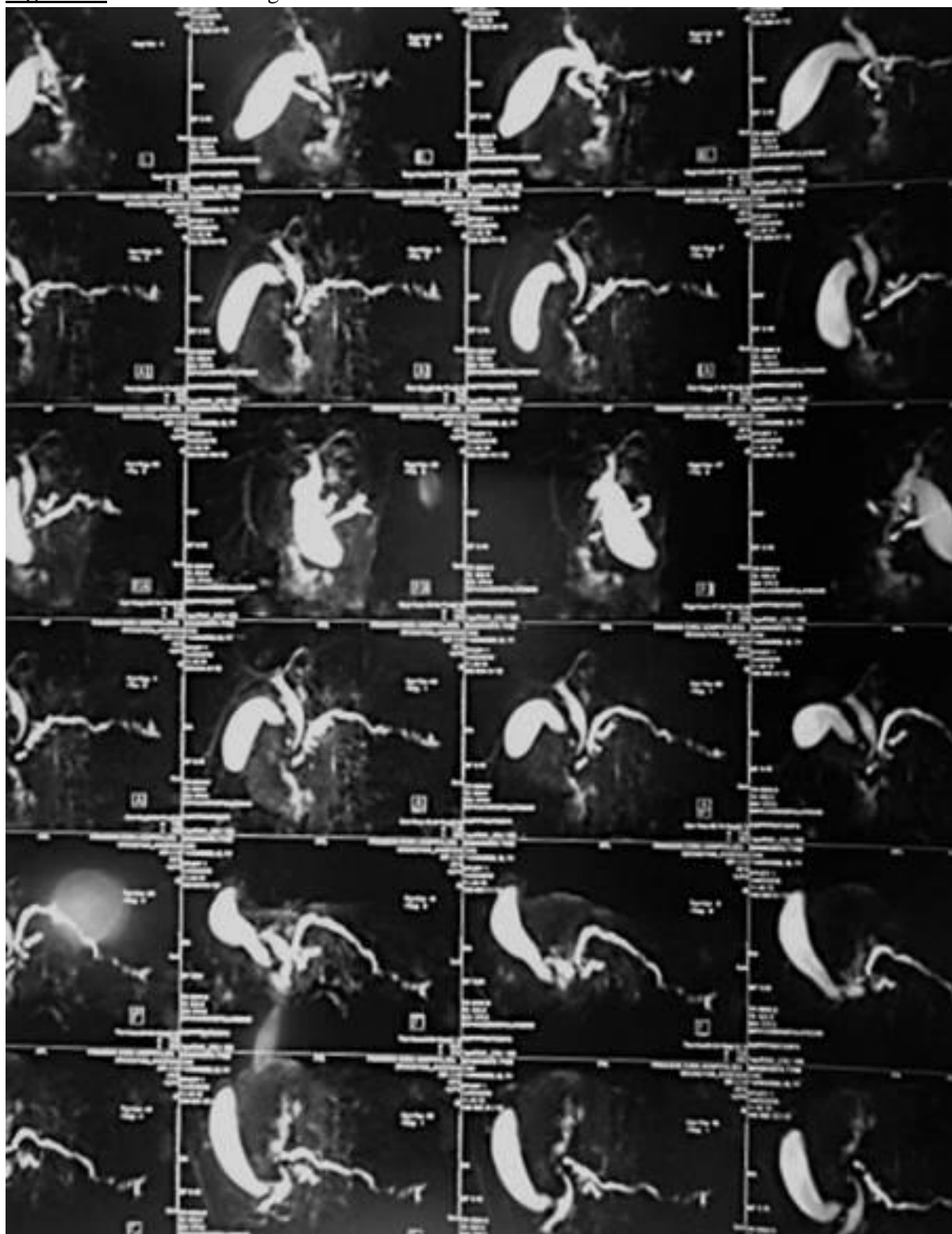
Bilirubin levels

Earlier it was mentioned that, 8 out of 30 children presented with jaundice. As a mandatory step all the patients were subjected to screening for biochemical jaundice. The average range of bilirubin levels in Hepatico-duodenostomy group were ranging from 0.3 to 9.8 mg/dl with an average of 2.68 mg/dl. The average range of bilirubin levels in Hepatico-jejunostomy group were ranging from 0.2 to 19.6 mg/dl with an average of 2 mg/dl. Hence all the children undergoing both the procedures were having biochemical jaundice (**Table – 2**).

Pathology

All the excised specimens were sent for histopathological examination (HPE). Three cases were found to have hepatic fibrosis and majority of the cases had chronic cholecystitis, and 2 cases showed features of biliary atresia. One case had cirrhosis of liver with associated atresia.

Figure – 4: MRCP with long common channel.



Long common channel or anomalous pancreatico-biliary junction (APBJ)

The Babbitt theory of an abnormal pancreatic – biliary junction is a commonly expanded theory for the development of choledochal cyst. In our study, one case was shown to have long common

channel on MRI and two cases were shown to have pancreatic divisum. In many cases the recording of the common channel was poorly done or not commented, upon hence the number may be higher than what was actually present (**Figure – 4**).

Figure - 5: Initiation of Feeds.

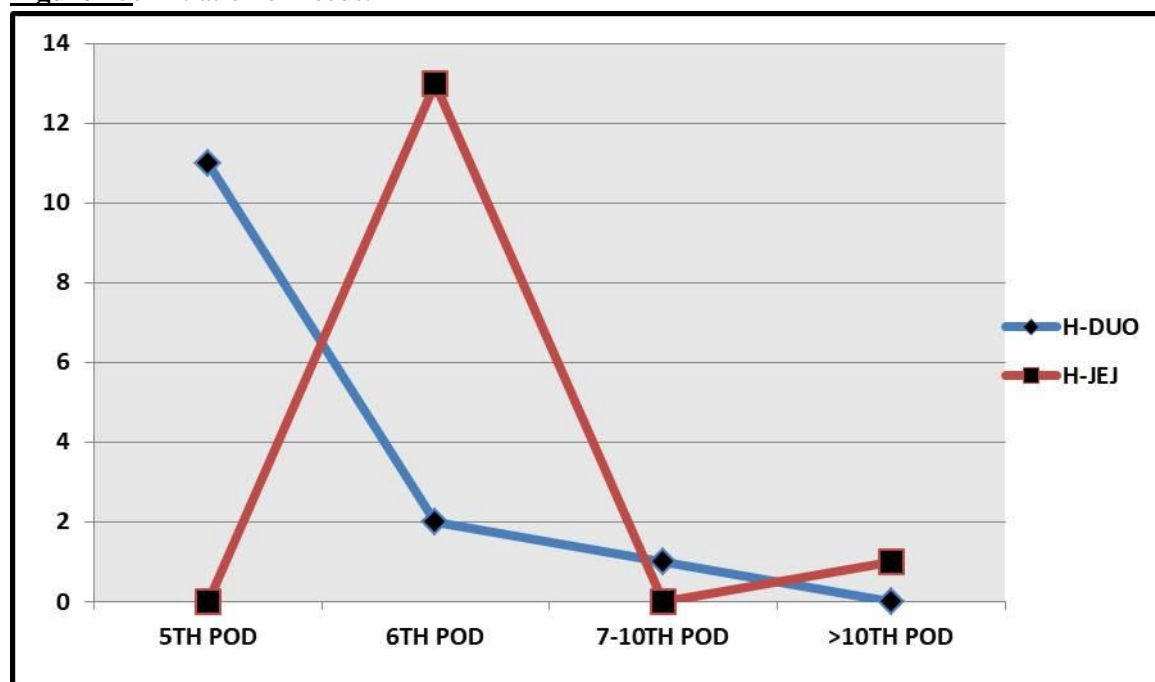
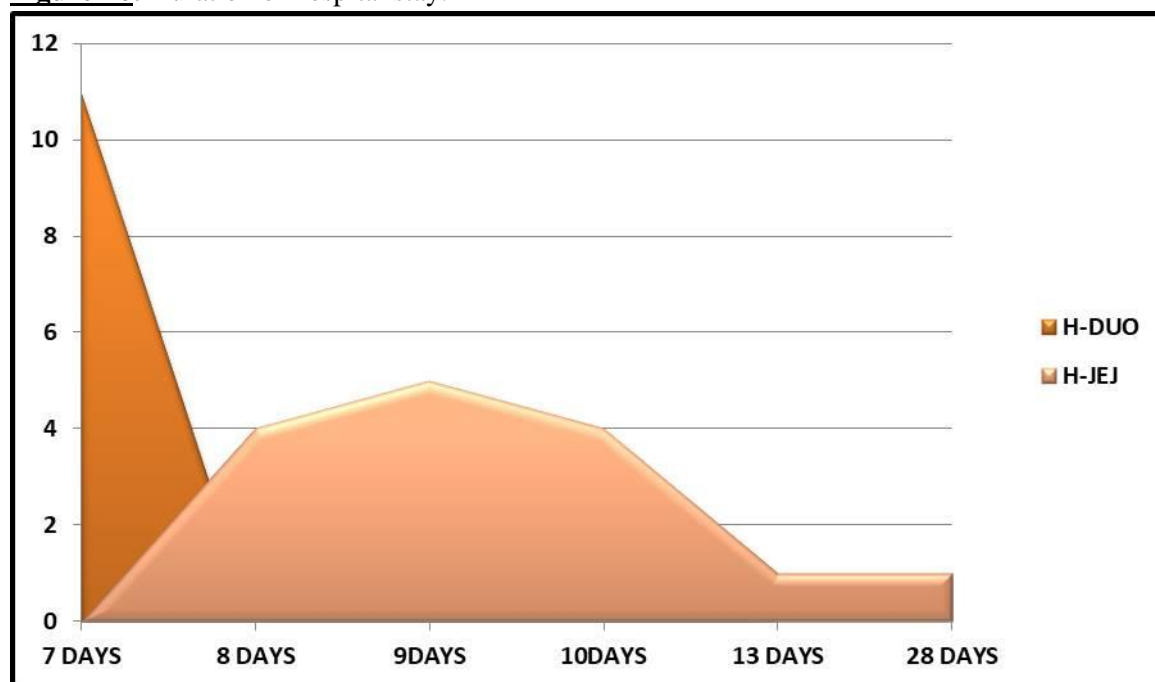


Figure - 6: Duration of hospital stay.



Surgeon's preference of Hepatico-enteric anastomosis

Many surgeons have got trained in a particular type of anastomosis and are comfortable to do the biliary enteric anastomosis in a particular method. Both Hepatico- enteric anastomosis have been advocated in our institution from the past. For surgeons, who usually do hepatico-

duodenostomy; perform hepatico-jejunostomy, in instances like

1. Inability to mobilize the duodenum to the biliary anastomosis without tension.
2. The presence of peri-choledochal cystic inflammation or in cases of ruptured cyst

The advantages of Hepatico-duodenostomy over Hepatico-jejunostomy as we observed are

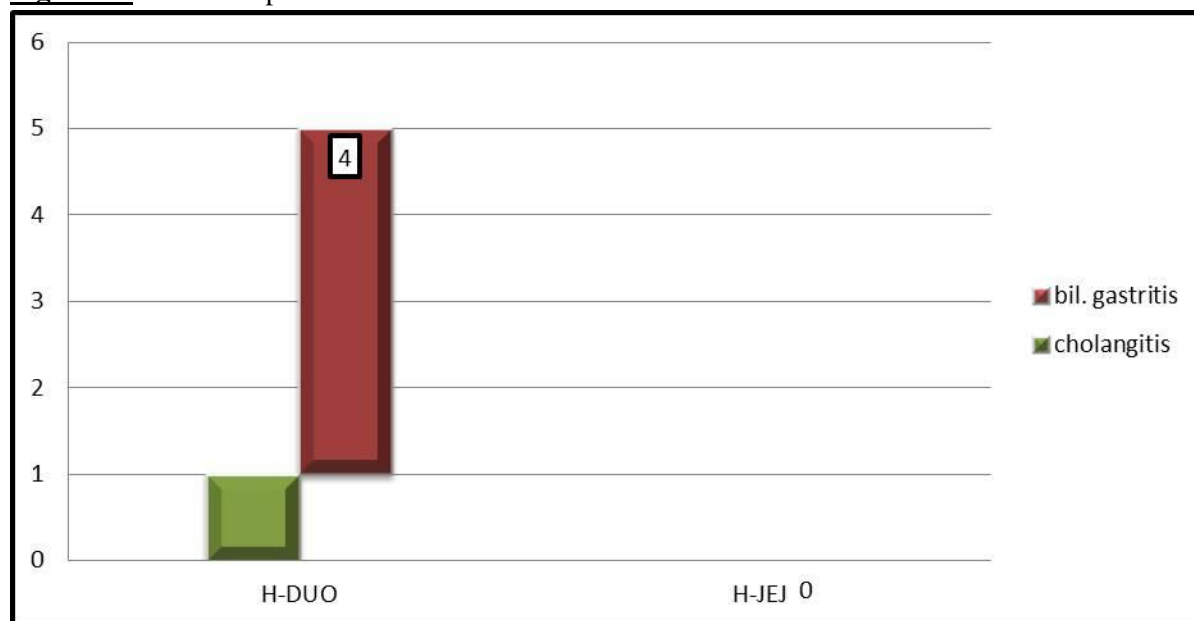
1. Single anastomosis with shorter operative time
2. Decreased need for blood transfusion post-operatively

Oral feeds

Early initiation of feeds and early mobilization of the patient facilitate early discharge. For all the children undergoing Hepatico-duodenostomy, feeds were initiated on 5th POD, and those undergoing Hepatico-jejunostomy were allowed

to take orals on the 6-7th post-operative day. One case in Hepatico-duodenostomy was allowed orals on 10th post-operative day as the intra-operative anatomy, and the general condition of the child demanded. One case who presented with ruptured cyst was allowed feeds on the 16th post-operative day with Hepatico-jejunostomy. The average time of initiation of feeds in the Hepatico-duodenostomy group was of 5 days, and that of the Hepatico-jejunostomy group 7 days (**Figure – 5**).

Figure - 7: Late Complications.



Duration of hospital stay

Length of hospital stay gives a good indicator to compare two procedures of choice. We analysed the length in hospital stay for all patients admitted for CC surgery. The length of stay was calculated from day of the surgical procedure to the day the patient was discharged. Average stay for the Hepatico-duodenostomy group was around 7.6 days when compared to 10.5 days in the Hepatico-jejunostomy group. One case, presented with ruptured cyst underwent Hepatico-jejunostomy, had an extended stay of 28 days for the poor post-operative condition (**Figure – 6**).

Complications

Early: in one case of Hepatico-jejunostomy group bile leak was observed on the 4th post-

operative day and taken up for re-exploration, was observed to have anastomotic dehiscence, and redo anastomosis done. The patient recovered well post-operatively and no other complications seen during follow up. No other early complications were seen in the Hepatico-duodenostomy group.

Late: One child of Hepatico-duodenostomy group had been admitted three months post operatively on the complaints of recurrent pain abdomen and fever. On examination the child had raised blood counts indicating cholangitis. Upper GI endoscopy ruled out biliary reflux. The child was managed conservatively with intravenous antibiotics over a period of 7 days and was advised prokinetics on discharge. On follow up, no similar complaints were noted. All the cases of Hepatico-duodenostomy have been

planned for upper GI endoscopy to rule out biliary reflux. Three cases lost to follow up. Twelve cases have turned up for follow up, underwent upper GI endoscopy, out of which 4 cases showed biliary reflux. But none of them presented with any symptoms of pain abdomen or recurrent vomiting. It was only an incidental finding in all the cases (**Figure – 7**).

Discussion

In Indian population very limited data is available on choledochal cyst. In our study conducted between October' 2014 to November' 2016, thirty patients have undergone definitive procedure for treatment of Choledochal cyst in our institution. The presentation varied from antenatal diagnosis to severe life threatening complications of ruptured cysts with biliary peritonitis. We had a similar baseline comparison for the two groups despite having varied presentations. In the presentation of the baseline characteristics, there is no significant difference between the two groups of children who came for surgery. The demographic data such as the sex ratio and age of presentation are not statistically significant. The median age of children who presented with CC was between 6 to 7 years.

The sex ratio of 1:1.5 in our series is more in keeping with Atul Mishra, et al. [2] series where there a similar female to male ratio. The presence of jaundice, a palpable mass and history of pancreatitis are equivalent. The average child that presented with CC had a baseline serum bilirubin level of 2.2 mg/dl. The level of jaundice measured biochemically were no different between the two groups. What does stand out in our baseline characteristics is the unusual presentations. These include 1 ruptured cyst, 1 post ERCP stenting, two cases of accessory ducts, pancreatic divisum and two cases of pancreatitis.

To draw a conclusion on the two procedures is difficult in our series as the study group is small and it was a short term series. Long term follow

up could have given us a better insight of the long term complications in both the procedures as complications like intestinal obstructions, strictures and cholangiocarcinomas which are better seen on long standing follow up. Hence here we are picking up short term complications like biliary gastritis and biliary leak. The debate surrounding biliary reconstruction by HJ vs HD, centres are of the opinion that HD reconstruction is more frequently complicated by bile gastritis, cholangitis, and are associated with a higher on-going risk of cholangiocarcinoma. A review of the literature, however, finds surprisingly little data supporting these concerns and there have been relatively few studies published comparing HD to HJ [3-7].

In an early report, Todani, et al. [8] compared 19 patients undergoing HD and 11 undergoing HJ and found no significant difference in biliary complications between the 2 procedures and advocated the HD procedure because of its "more physiologic state" and fewer postoperative intestinal complications. Our study group was much similar in number compared with Todani, et al. We have done endoscopy routinely for patients to monitor bile gastritis. The influential publication is by Shimotakahara, et al. [9], which compared 28 patients reconstructed by HJ with 12 patients reconstructed by HD after CC resection. They observed complications of bile gastritis in 4 of 12 HD patients compared with 0 of 28 HJ patients and had 2 postoperative adhesion-related bowel obstructions in the HJ group with none in the HD group. The same number was observed by us in this study in view of biliary gastritis.

Shimotakahara, et al. [9] concluded that HJ as the procedure of choice because of the high incidence of duodenogastric reflux after HD. Out of 15 patients that underwent HD, in our group, three patients were lost to follow-up. The rest have undergone upper GI endoscopy, of which 4 out of the 12 patients were showing biliary gastritis though they were not showing any signs or history consistent with the endoscopic findings. A study by Takada, et al. [10] in which

3 patients who underwent HD reconstruction and 5 who underwent HJ reconstruction were compared by monitoring with a Bilitec probe (Medtronic, Minneapolis, MN) and were subjected to endoscopy to assess the presence and severity of duodenogastric reflux. Although none of the patients were symptomatic, all 3 of the HD patients and none of the HJ patients had chemical and endoscopic evidence of duodenogastric reflux. However, biopsies showed only superficial gastritis in both groups. As none of the patients in our HJ group were shown having symptomatic gastritis, this study gives us an insight that all the cases of CC excision should undergo endoscopic studies.

Our results were no different from those of Shimotakahara, et al. [9] as we observed no incidence of symptomatic bile gastritis. Our construction of the HD anastomosis is at the junction of the first and second portions of the duodenum performed after an extensive Kocher maneuver to prevent any tension on the anastomosis. This is well distal to the pylorus and did not impact pyloric function or gastric emptying significantly. We had seen one case of cholangitis in the absence of stricture formation in HD procedure. One case of long common channel was noted, who would in particular need a long term follow up in view of particular relevance to intrahepatic cholangiocarcinoma as noted by Goto, et al. [11], where a patient who underwent resection of a type Ia cyst (no intrahepatic dilation) presented with development of an intrahepatic cholangiocarcinoma after 10 years. That patient had a Roux-en-Y HJ reconstruction. Thus, there may be a field risk of carcinoma of intrahepatic ducts in patients with anomalous pancreaticobiliary junctions irrespective of the type of reconstructive procedure done.

In this series we could find a few significant differences in our outcomes with HD compared to HJ. It is clear that HD reconstruction requires less operative time and then HJ. There was also a trend towards early enteral feeds and shorter length of stay after HD given to the reduced

bowel manipulation in this procedure. Importantly, there is no increase in the rate of bile leak in the HD group. One of the bile leak patients who underwent an HJ illustrates another clear advantages over HJ. Finally, our HJ patients had a higher rate of reoperation than the HD group. When compared with late complications it has been analysed that HJ is more of a preferred option in view of post-operative complications like biliary gastritis as late complications could not be assessed in this group.

Our results also support HD as the preferred procedure for biliary reconstruction after resection of CC, in view of the advantages of relative simplicity, avoidance of complications related to the Roux-en-Y conduit, and restoration of relatively physiologic bile drainage outweigh the potential disadvantages of HJ approach, which for the most part remain unproven.

Conclusions

Hepatico-duodenostomy can be advocated because of its technical simplicity and being more physiological in attaining biliary drainage. Hepatico-duodenostomy also has no bile leak rate and has advantages of early commencement of feeds and shorter hospital stay. Hepatico-jejunostomy can be advocated in view of absent post-operative biliary gastritis and cholangitis. The procedure of choice has no effectiveness in cases with associated pancreaticobiliary malformations in prevention of cholangiocarcinoma and they need a long term follow up to study the complications of the procedures in detail. All the cases undergoing surgical procedure for biliary enteric anastomosis should undergo upper GI endoscopy post procedure irrespective of the type of the procedure to rule out gastritis. The debate of preferred procedure of choice still continues as the study is short and a long term study is required for better analysis and a larger sample the post-operative complications of each procedures.

References

1. Howard ER. Choledochal cysts. In Howard ER, ed. Surgery of liver disease in children. Oxford; Butterworth-Hienemann, 1991; p. 78-90.
2. Atul Mishra, Nitin Pant, Rajiv Chadha, S. Roy Choudhury. Choledochal Cysts in Infancy and Childhood. Indian Journal of Pediatrics, 2007; 74.
3. Singham J, Schaeffer D, Yoshida E, et al. Choledochal cysts: analysis of disease pattern and optimal treatment in adult and paediatric patients. HPB (Oxford), 2007; 9: 383-7.
4. Sugiyama M, Haradome H, Takahara T, Izumisato Y, Abe N, Masaki T, et al. Biliopancreatic reflux via anomalous pancreaticobiliary junction. Surgery, 2004; 135: 457-9.
5. Okada A, Hasegawa T, Oguchi Y, Nakamura T. Recent advances in pathophysiology and surgical treatment of congenital dilatation of the bile duct. J Hepatobiliary Pancreat Surg., 2002; 9: 342-51.
6. Lee HC, Yeung CY, Fang SB, et al. Biliary cysts in children — long-term follow-up in Taiwan. J Formos Med Assoc., 2006; 105: 118-24.
7. Kiresi DA, Karabacakoglu A, Dilsiz A, et al. Spontaneous rupture of choledochal cyst presenting in childhood. Turk J Pediatr., 2005; 47: 283-6.
8. Todani T, Watanabe Y, Urushihara N, et al. Biliary complications after excisional procedure for choledochal cyst. J Pediatr Surg., 1995; 30: 478-81.
9. Shimotakahara A, Yamataka A, Yanai T, et al. Roux-en-Y hepaticojejunostomy or hepaticoduodenostomy for biliary reconstruction during the surgical treatment of choledochal cyst: which is better? Pediatr Surg Int., 2005; 21: 5-7.
10. Takada K, Hamada Y, Watanabe K, et al. Duodenogastric reflux following biliary reconstruction after excision of choledochal cyst. Pediatr Surg Int., 2005; 21: 1-4.
11. Goto N, Yasuda I, Uematsu T, et al. Intrahepatic cholangiocarcinoma arising 10 years after the excision of congenital extrahepatic biliary dilation. J Gastroenterol., 2001; 36: 856-62.