

Case Report


Malignant Peripheral Nerve Sheath Tumor of Thigh Region - A Case Report

Sahil Parikh^{1*}, Kuntal Patel², Bhavik Shah¹, Vaibhavi Chaudhari¹

¹Resident Doctor, ²Assistant Professor

Pathology Department, SBKS MI & RC, Sumandeep Vidyapeeth, Vadodara, Gujarat, India

*Corresponding author email: sahilparikh333@gmail.com

	International Archives of Integrated Medicine, Vol. 5, Issue 10, October, 2018. Copy right © 2018, IAIM, All Rights Reserved. Available online at http://iaimjournal.com/ ISSN: 2394-0026 (P) ISSN: 2394-0034 (O)
	Received on: 02-09-2018 Accepted on: 08-09-2018 Source of support: Nil Conflict of interest: None declared.
	How to cite this article: Sahil Parikh, Kuntal Patel, Bhavik Shah, Vaibhavi Chaudhari. Malignant Peripheral Nerve Sheath Tumor of Thigh Region - A Case Report. IAIM, 2018; 5(10): 142-146.

Abstract

Malignant peripheral nerve sheath tumor (MPNST) is derived from Schwann cells or pluripotent cells of the neural crest. MPNSTs (Malignant Peripheral Nerve Sheath Tumor) commonly arise in adult patients ranging from 20 to 50 years of age. They originate from a major or minor peripheral nerve branch or its sheath. The common sites of origin include the extremities and trunk. We reported a case of MPNST in 35 years old female patient with rapidly growing mass in her left thigh. Histopathological examination and immunohistochemistry confirmed the diagnosis of MPNST. This case report of Malignant peripheral nerve sheath tumor (MPNST) is presented because of its rarity.

Key words

Malignant Peripheral Nerve Sheath Tumor, Extremities, Histopathology.

Introduction

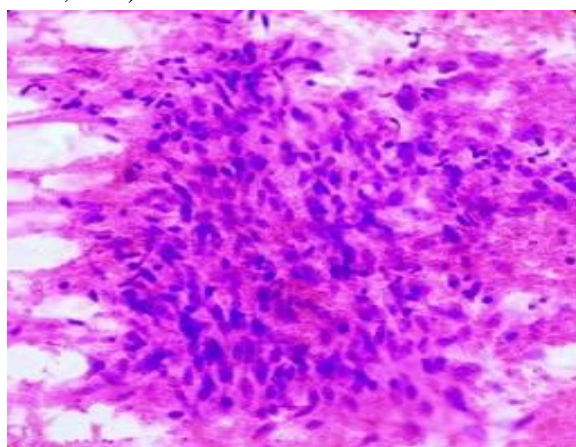
MPNST (Malignant Peripheral Nerve Sheath Tumor) is the preferred term for tumors originating from peripheral nerves or from cells associated with the nerve sheath, such as schwann cells, perineural cells replacing previous entities such as malignant schwannoma, malignant neurilemmoma and neurofibrosarcoma. They represent approximately 10% of all soft tissue sarcomas [1]. MPNSTs commonly arise in adult patients

ranging from 20 to 50 years of age. They originate from a major or minor peripheral nerve branch or its sheath. The common sites of origin include the extremities and trunk usually sciatic nerve, brachial plexus and the sacral plexus. We presented here a case of MPNST located over left thigh region which was diagnosed cytologically and confirmed by histopathology and immunohistochemistry. Here in the present case report, we were able to find and document the typical features of MPNST.

Case report

A 35 Year old female, presented with a rapidly growing mass in her left thigh for a duration of 1 year, with complaint of pain for 7 months, in the Surgical out-patient department of SBKS Medical College, Dhiraj Hospital, Waghodia. There was no clinical evidence or family history of NF1. She had no surgeries in the past. On examination, there was presence of 9×6 cm swelling in the medial side of the left thigh. Fine Needle Aspiration Cytology (FNAC) was advised by the clinicians and patient was referred to the cytology laboratory. FNAC was performed [2-15] from left thigh swelling. The smears were prepared, fixed with the methanol and stained with Hematoxylin and eosin stain. Microscopy revealed high cellularity comprising of plump and spindle shaped cells with wavy and tapering nuclei arranged in whirling pattern and in tight clusters interspersed with fibroblasts in a hemorrhagic background. From overall cytomorphological findings a diagnosis of spindle cell neoplasm was established (**Photograph - 1**). All the hematological, biochemical and serological examinations were normal.

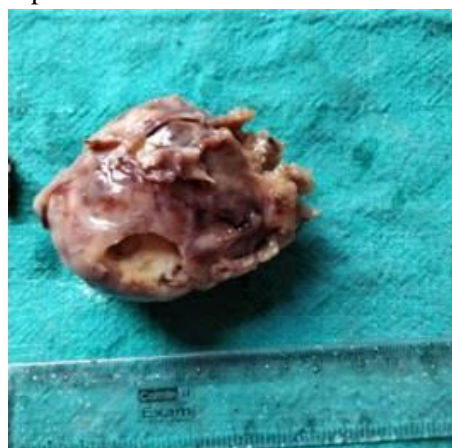
Photograph – 1: FNAC smear showed plump spindle cells with pleomorphic nuclei (H&E stain, 40X).



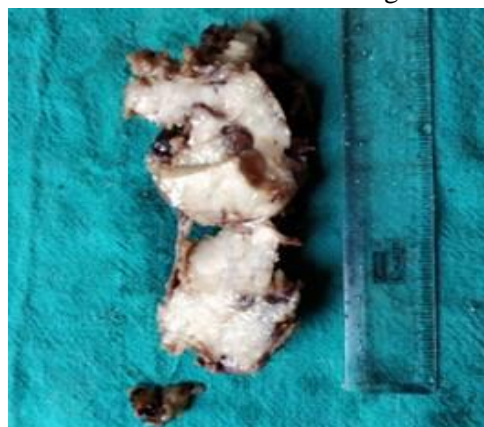Wide and local excision of thigh lesion was done and the specimen sent for histopathological examination. We had received single, irregular, solid mass measuring 7×4.5×4 cm. The cut surface showed whitish solid tumor tissue with

areas of hemorrhage and necrosis (**Photograph - 2, 3**). On histopathological examination multiple section showed areas of dense cellular fascicles which alternate with hypocellular myxoid areas which inter-digitate and swirl to form a “marbleized pattern”. The cell was spindle shaped with irregular contours, rounded or fusiform. The nuclei were wavy, with lightly stained and indistinct cytoplasm. Nuclear palisading was also present (**Photograph - 4, 5**). From histopathological examination the diagnosis of MPNST was made. For confirmation of the MPNST we had also performed Immunohistochemistry (IHC). We had positive S100, Ki 67 showed 10-12/hpf proliferative index, CD 99 positive and Vimentin positive. Based on these findings final diagnosis of MPNST (Malignant Peripheral Nerve Sheath Tumor) was given (**Photograph - 6, 7, 8**).

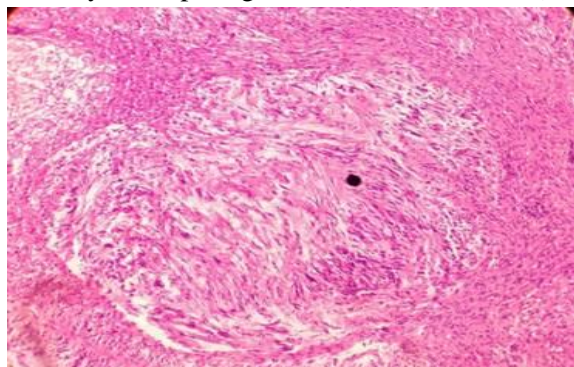
Photograph – 2: Single and non-encapsulated Gross specimen of MPNST.



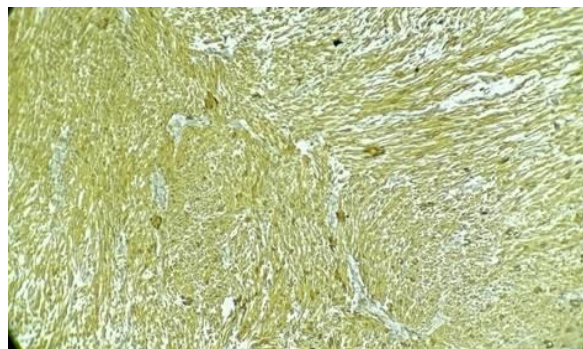
Photograph – 3: Cut surface of whitish in colour with areas of necrosis and hemorrhage.



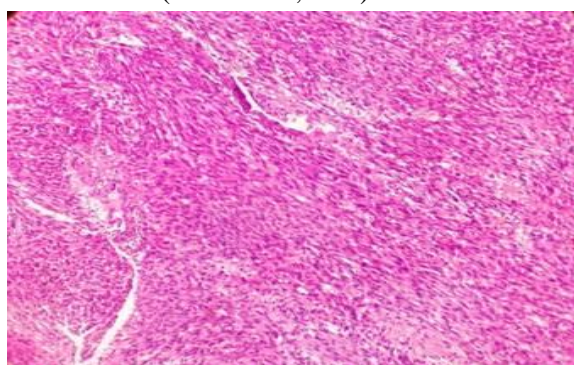
Photograph – 4: Storiform pattern comprising of wavy and tapering nuclei (H&E stain, 20X).



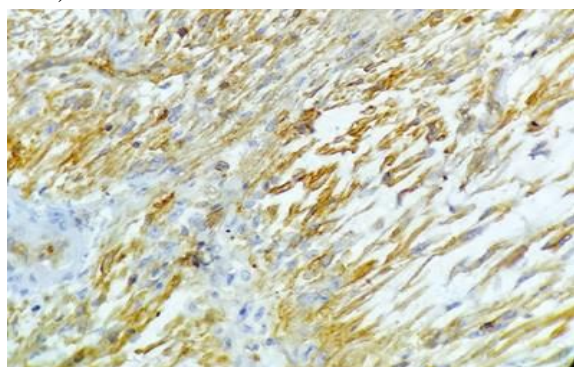
Photograph – 8: Vimentin positivity (IHC stain, 10X).



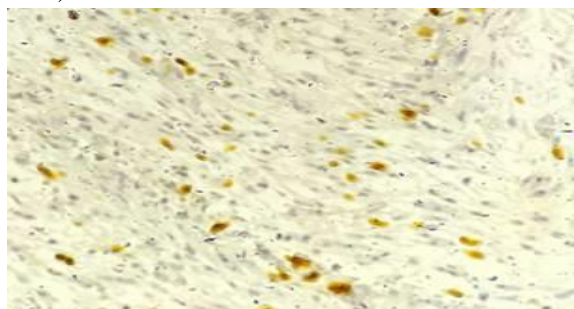
Photograph – 5: Marbleised pattern formed by tumour cells (H&E stain, 40X).



Photograph – 6: CD 99 positivity (IHC stain, 40X).



Photograph – 7: Stain with Ki 67 (IHC stain, 40X).



Discussion

Malignant peripheral nerve sheath tumor (MPNST) is derived from Schwann cells or pluripotent cells of the neural crest [16-20] MPNST is a very rare tumor, accounting for 5-10% of all soft tissue sarcomas with an incidence of approximately 0.001% in general population [21]. It may occur either sporadically in 40% of cases or in association with Neurofibromatosis1 (NF1) in 50% of cases, 10% of cases has been reported in patients with history of radiation exposure [22, 23]. In our patient there was no history of NF1.

Clinically, MPNST occurs as a solitary, deep seated palpable mass with sudden enlargement, aggressive, locally invasive and may cause erosion of adjacent bone with high rate of recurrence. The most common site is upper and lower extremities and neck. Our patient also presented with rapidly growing mass in her left thigh. For the diagnosis FNAC is the easiest and cost effective tool but architectural pattern of the tumor cannot be demonstrated in FNAC. This is the reason for difficulty in definite diagnosis of MPNST with FNA smear. In our case also in FNAC we were not able to give the diagnosis of MPNST firmly. As FNAC cannot give a definite diagnosis, excisional biopsy was done in the present case. Grossly, the tumour specimen may be fusiform, oval with areas of hemorrhage and necrosis. On Histopathology multiple bits show tumour tissue arranged in whirling pattern and in fascicles having wavy and tapering nuclei, areas of necrosis also seen along with areas of

hemorrhage. Areas of hyper and hypocellularity comprising of plump spindle shaped cells also noted. There was also presence of whirling pattern and marbled pattern. The most important differential diagnosis of MPNST is spindle cell sarcoma which includes synovial sarcoma, dedifferentiated liposarcoma, leiomyosarcoma and fibrosarcoma [24]. For the final confirmation of the diagnosis role of IHC is must. Immunostaining shows focal staining for S-100, CD57 and Leu-7 and myelin basic protein in 50% of the cases. In the present case we had performed CD-99, S-100, Vimentin and Ki 67 which confirmed our diagnosis of MPNST. Metastasis occurs in 39% of patients and 68% die from this tumor [17]. Surgery is the main stay of the treatment, but postoperative radio- and chemotherapy are part of adjunctive therapy [25].

Conclusion

As FNAC can't demonstrate architectural pattern of many neoplasms like MPNST, histopathological examination with IHC stain remains gold standard method for final diagnosis.

References

1. Weiss SW, Goldblum JR. Malignant tumors of the peripheral nerves. In Enzinger and Weiss's Soft Tissue Tumours. 4th edition, Edited by Strauss M, Grey L. St. Louis: Mosby, Inc; 2001, p. 1209-64.
2. Gunvanti Rathod, Pragnesh Parmar. Fine needle aspiration cytology of swellings of head and neck region. Indian Journal of Medical Sciences, 2012; 66: 49-54.
3. Gunvanti Rathod, Sangita Rathod, Pragnesh Parmar, Ashish Parikh. Diagnostic efficacy of fine needle aspiration cytology in cervical lymphadenopathy – A one year study. International Journal of Medical and Pharmaceutical Sciences, 2014; 4(5): 18.
4. Rathod GB, Ghadiya V, Shinde P, Tandan RK. Pleomorphic sarcoma in 60 years old male – A case report. International Journal of Current Microbiology and Applied Sciences, 2014; 3(8): 510-517.
5. Gunvanti Rathod, Pragnesh Parmar, Sangita Rathod, Ashish Parikh. Suprascapular malignant fibrous histiocytoma – A case report. Discovery, 2014, 12(31): 50-53.
6. Rathod GB, Goyal R, Bhimani RK, Goswami SS. Metaplastic carcinoma of breast in 65 years old female - A case report. Medical Science, 2014; 10(39): 77-81.
7. Disha Singla, Gunvanti Rathod. Cytodiagnosis of renal cell carcinoma – A case report. IAIM, 2015; 2(2): 133-137.
8. Mobeen Alwani, Gunvanti B. Rathod. Diagnosis of anaplastic thyroid carcinoma on fine needle aspiration cytology - A rare case report. IAIM, 2015; 2(3): 183-187.
9. Annie Jain, Gunvanti Rathod. Oncocytoma of parotid gland: A rare case report. IAIM, 2015; 2(4): 166-169.
10. Nupur Singla, Gunvanti Rathod, Disha Singla. Adenoid cystic carcinoma of the parotid gland - A case report and review of literature. IAIM, 2015; 2(4): 182-186.
11. Anchal Bhola, Gunvanti Rathod, RK Tandan. Cystic metastatic squamous cell carcinoma - A case report. IAIM, 2015; 2(5): 195-199.
12. Rathod GB, Jain A. Role of FNAC in diagnosis of gouty tophi - A case report. IAIM, 2015; 2(7): 137-140.
13. TH Kalidas Singh, Gunvanti B. Rathod. Diagnosis of fat necrosis on FNAC - A case report. IAIM, 2015; 2(6): 236-239.
14. Rathod GB, Rai P. Audit of repeat fine needle aspiration in cytopathology laboratory. IAIM, 2015; 2(9): 20-25.
15. Rathod GB, Rai P, Rai S. A prospective study of ultrasonographic and FNAC correlation of thyroid pathology. IAIM, 2015; 2(11): 46-51.
16. Danid NL, Hiroko O, Otmar DW, et al. WHO classification of tumors - pathology and genetics of tumors of the

- nervous system; 4th Edition, WHO, 2007, p. 160.
17. Rodriguez FJ, Folpe AL, Giannini C, Perry A. Pathology of peripheral nerve sheath tumors: diagnostic overview and update on selected diagnostic problems. *Acta Neuropathol.*, 2012; 123: 295-319.
 18. Kar M, Deo SV, Shukla NK, et al. Malignant peripheral nerve sheath tumors (MPNST)--clinicopathological study and treatment outcome of twenty-four cases. *World J Surg Oncol.*, 2006; 22: 55-63.
 19. Yamaguchi U, Hasegawa T, Hirose T, et al. Low grade malignant peripheral nerve sheath tumour: varied cytological and histological patterns. *J Clin Pathol.*, 2003; 56: 826-830.
 20. Rekhi B, Abhijeet I, Rajiv K, et al. Malignant peripheral nerve sheath tumors: Clinicopathological profile of 63 cases diagnosed at a tertiary cancer referral center in Mumbai, India. *Indian J Pathol Microbiol.*, 2010; 53: 611-618.
 21. Wanebo J.E., J.M. Malik, S.R. VandenBerg, H.J. Wanebo, N. Driesen, J.A. Persing. Malignant peripheral nerve sheath tumors: a clinicopathological study of 28 cases. *Cancer*, 1993; 71: 1247-1253.
 22. Adamson, D.C., C.T. Friedman. AH: Malignant peripheral nerve sheath tumor of the spine after radiation therapy for Hodgkin's lymphoma. *Clin Neuropathol*, 2004; 23(5): 245-55.
 23. Amin A.S.A., A. Flanagan, D. Patterson, J. Lehovsky. Radiotherapy-induced malignant peripheral nerve sheath tumor of the cauda equina. *Spine*, 2004; 29(21): E506-9.
 24. Ducatman S.B., W.S. Bernd, G.P. David, M.R. Herbert, M.I. Duare. Malignant peripheral malignant nerve sheath tumor. A clinicopathological study of 120 cases. *Cancer*, 1986; 57: 12.
 25. Aguiar VS, Sarrazin D, Henry-Amar M, Spielmann M, Genin J, Bernheim A, Contesso G. Neurosarcoma associated with Von Recklinghausen disease: Apropos of 25 cases observed at the Gustave Roussy Institute from 1967 to 1990. *Bulletin du cancer*, 1991 Dec; 79(1): 101-12.