

Original Research Article


Clinical study and management of genitourinary tuberculosis

Immadi Chandrasekhar¹, Pasalapudi Anurag Jose^{2*}

¹Assistant Professor, Department of Urology, Andhra Medical College, Visakhapatnam, Andhra Pradesh, India

²Consultant Urologist, GITAM Institute of Medical Sciences and Research (GIMSR), Visakhapatnam, Andhra Pradesh, India

*Corresponding author email: dranuragjose5@gmail.com

	International Archives of Integrated Medicine, Vol. 6, Issue 1, January, 2019. Copy right © 2019, IAIM, All Rights Reserved. Available online at http://iaimjournal.com/ ISSN: 2394-0026 (P) ISSN: 2394-0034 (O)	
	Received on: 11-12-2018	Accepted on: 17-12-2018
Source of support: Nil		
Conflict of interest: None declared.		
How to cite this article: Immadi Chandrasekhar, Pasalapudi Anurag Jose. Clinical study and management of genitourinary tuberculosis. IAIM, 2019; 6(1): 48-57.		

Abstract

Background: Tuberculosis can affect any organ system of the body, including the genitourinary tract. Genitourinary TB is the most common form of extra pulmonary TB accounting for 27% (14- 41%) worldwide.

Aim and objectives: To study distribution of GU TB in relation to age, sex, anatomical site, signs and symptoms and to study various diagnostic modalities, treatment and role of surgery in GU TB.

Materials and methods: This study was a cross sectional study done at department of Urology, King George hospital, Visakhapatnam. The study was done over a period of 30 months, which was from September 2014 to February 2017. All the patients reporting to the hospital with proven genitourinary tuberculosis or diagnosed after coming to the hospital were included in the study. Total number of cases was 35. 10 were males and 25 were females. History, physical examination, laboratory and radiological investigations were done on the patients and the primary focus of the disease and organs involved are determined. All the patients received treatment as indicated.

Results: Most of the patients (33 out of 35) belonged to low socio-economic status and came from rural settings. Of them 10(28.57%) were males and 25(71.43%) were females. The mean age of patients was 36 years (range 16-60years). 2 patients were <20 years, 11 patients were between 21-30 years, 11 patients were between 31-40 years, 8 patients were between 41-50 years and 3 were above 50 years. In this study, kidney was involved in 19 cases and was the most common organ involved, followed by bladder (14 cases) and ureter(10 cases). Irritative voiding symptoms were the most common symptom seen in 23 cases. Flank pain was noted in 20 cases, sterile pyuria in 22 cases and hematuria in 7 cases. Six(17.14%) out of thirty five patients had renal failure at the time of presentation and diagnosis. Nephrectomy was done in 12 cases. Nephrectomy with augmentation

cystoplasty and ureteric reimplantation was done in another 6 cases. Ileal conduit was done in 6 cases. Ureteric reimplantation with psoas hitch was done in 3 cases.

Conclusion: Genitourinary tuberculosis is often silent and has nonspecific clinical features. Irritative voiding symptoms are the common presentation. Kidney is the most commonly affected organ in GU TB. GU TB is a disease of young adults, with majority affected in the 3rd and 4th decades. CT scan is replacing IVU as an imaging modality of choice in GU TB. Diagnosis of GU TB can be baffling, compelling a high index of suspicion owing to paucibacillary load in the biological specimens and the difficulty to isolate or grow TB bacilli. Hence a strong clinical suspicion is necessary for correct diagnosis. Anti-tubercular therapy is the mainstay of treatment. Genitourinary tuberculosis results in sequel which may require major organ removing and reconstructive surgeries.

Key words

Cystoscopy, DMSA (dimercaptosuccinic acid) scan, Ileal conduit, Mantoux test, Mycobacterium tuberculosis, Nephrectomy, Renogram, Ureteric reimplantation.

Introduction

Tuberculosis can affect any organ system of the body, including the genitourinary tract. Genitourinary TB is the most common form of extra pulmonary TB accounting for 27% (14-41%) worldwide [1]. Genitourinary tuberculosis (GU TB) is still a major health problem in many developing nations including India and had been declared by World Health Organization as “public health emergency” in 1993 [2, 3]. GU TB requires long term anti-tuberculous treatment. The present study was undertaken to study the trends in GU TB in our tertiary care hospital.

Aim and objectives

- To study the distribution of GU TB in relation to age, sex, anatomical site, symptoms and signs.
- To study various diagnostic modalities, treatment and role of surgery in GU TB.

Materials and methods

This study was a cross sectional study done at department of Urology, King George Hospital, Visakhapatnam, a tertiary care centre. The study was done over a period of 30 months, which is from September 2014 to February 2017.

Inclusion criteria: All the patients reporting to the hospital with proven genitourinary

tuberculosis or diagnosed after coming to the hospital and were treated as in patients were included in the study.

Exclusion criteria: Patients who were not willing to come for follow up were excluded from the study.

Total number of cases was 35. 10 were males and 25 were females. History, physical examination, laboratory and radiological investigations were done on the patients and primary focus of the disease and the organs involved were determined. All the patients received treatment as indicated. The laboratory tests were done included urinalysis, full blood picture with ESR, Mantoux (tuberculin) skin test and screening for HIV. Urine cultures for Mycobacterium tuberculosis were done using the first voided urine specimen and collections were repeated on three consecutive days in some cases. Urine PCR for Mycobacterium tuberculosis DNA was done in few cases [4]. Radiological evaluation included chest X-ray, ultrasound KUB in all cases. CT scan was done in most of the cases. IVU was done in some cases. DTPA (diethylene triamine penta acetic acid) renogram and DMSA (dimercaptosuccinic acid) scan were obtained as and when necessary. Cystoscopy and bladder biopsy were done wherever indicated. Sinus tract biopsy was done in one case (**Figure – 1 to 5**).

Figure - 1: IVU showing left delayed nephrogram due to PUJ stricture.

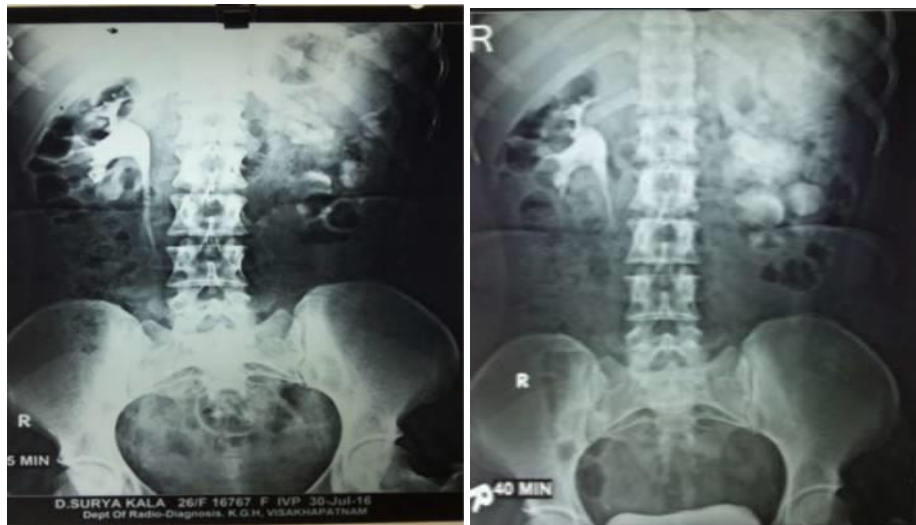

Figure - 2: Sigmoid augmentation cystoplasty with left ureter reimplantation.

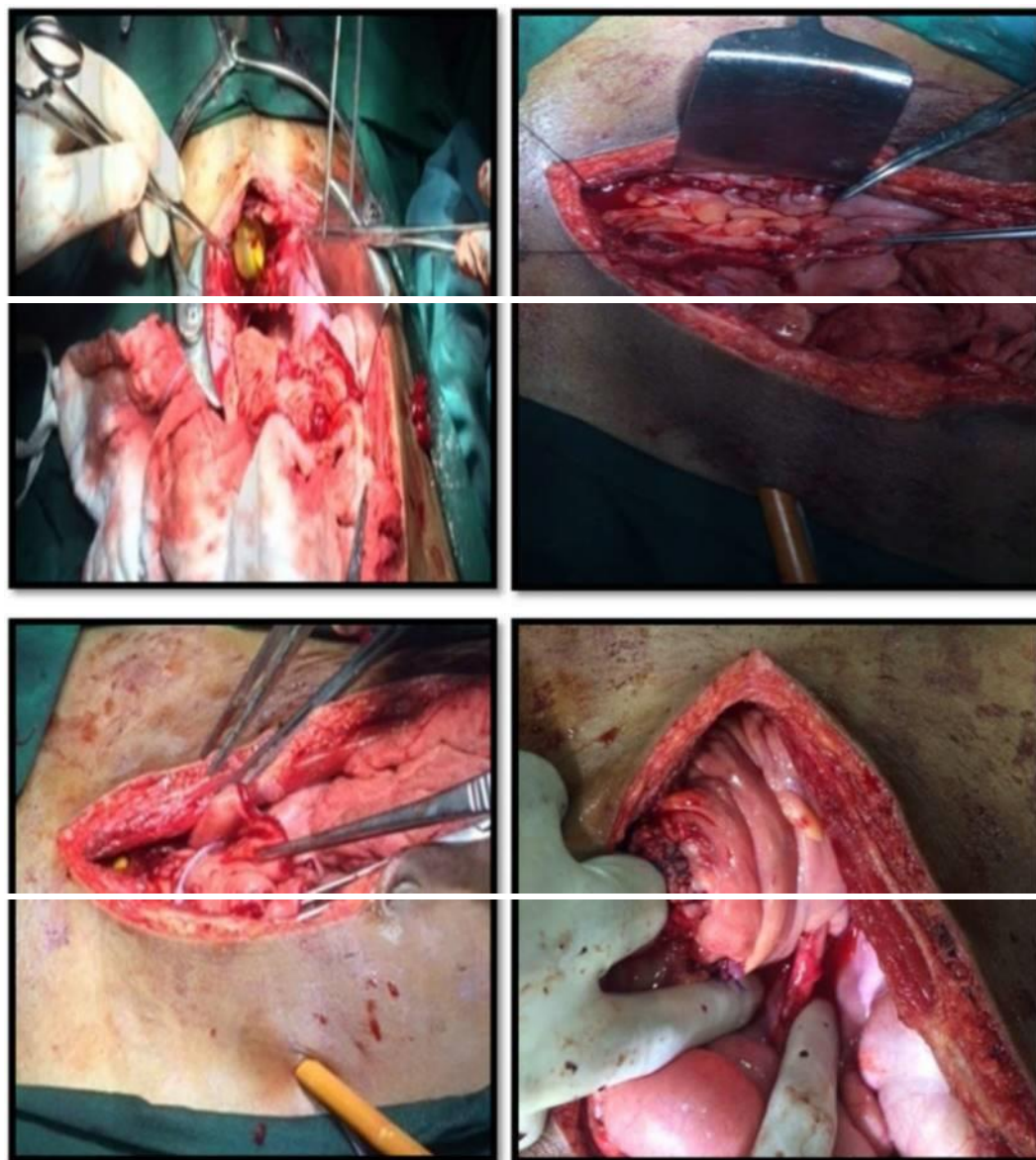


Figure - 3: CT scan showing right hydronephrotic kidney, post-operative histopathology suggesting renal tuberculosis.

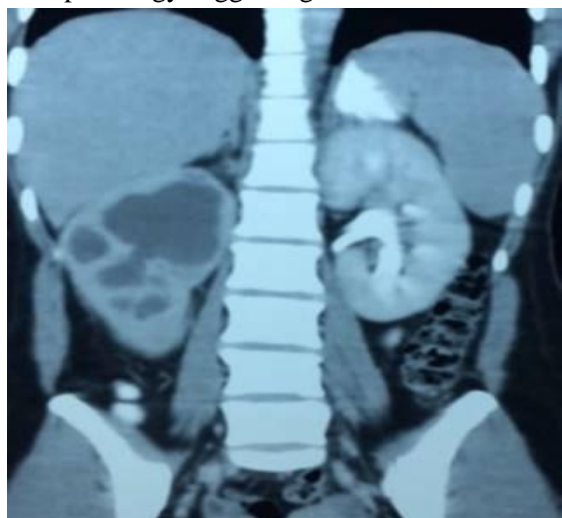
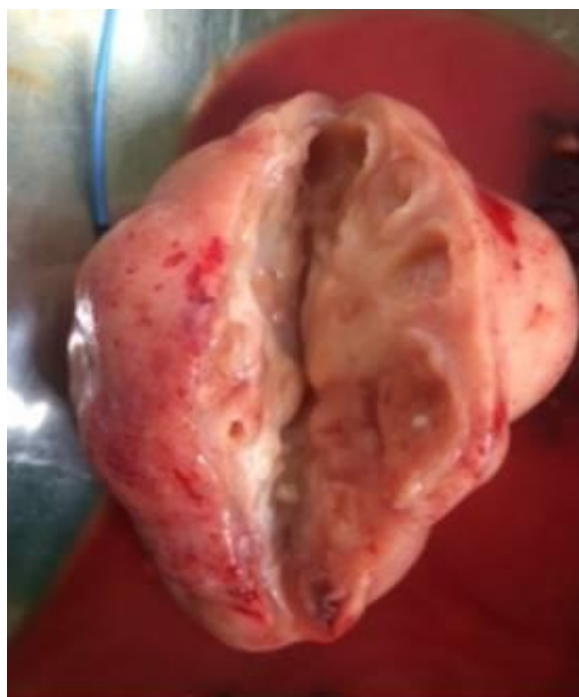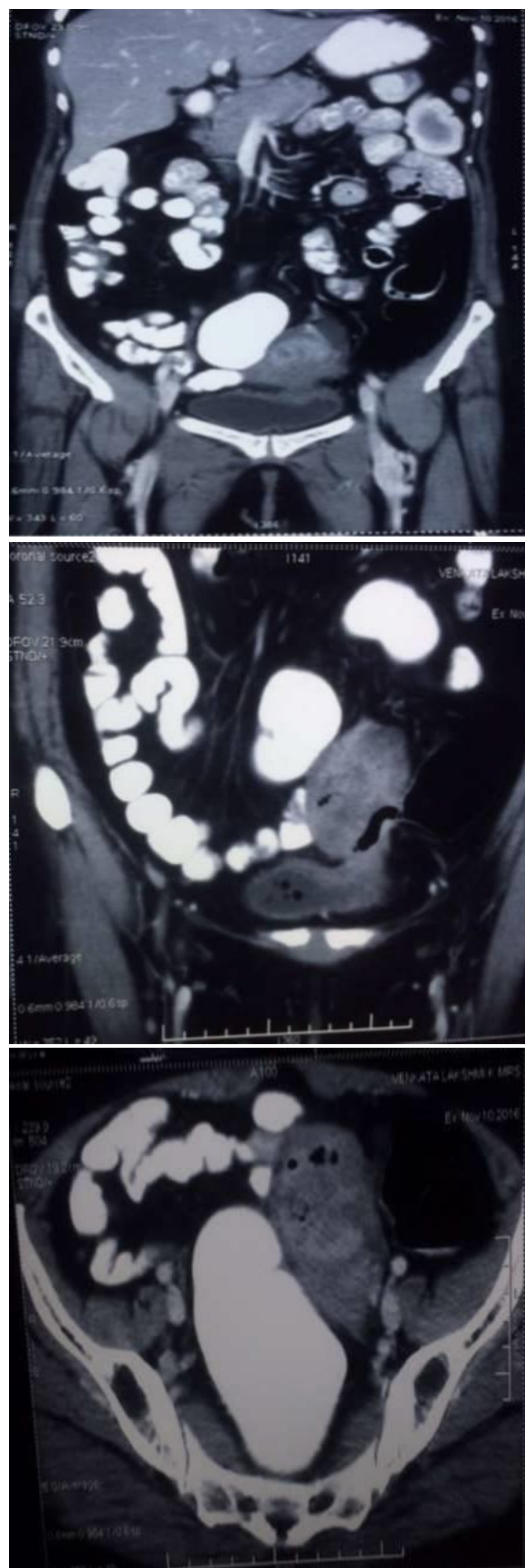


Figure - 4: Nephrectomy specimen, post-operative histopathology report suggestive of renal tuberculosis.



All the patients received anti-tuberculous therapy with 4 drugs (isoniazid, rifampicin, pyrazinamide and ethambutol) for two months followed by 2 drugs (isoniazid and rifampicin) for seven months. The operative procedure was selected depending upon the organ involved, the extent of the disease, functional status of the involved organ and overall renal function [5].

Figure - 5: CT scan and report of TB left ovary and colovesical fistula.



Results

Thirty five patients admitted in the department of Urology, King George Hospital, Visakhapatnam with the diagnosis of GU TB or diagnosed after coming to the hospital were studied. Most of the patients (33 out of 35) belonged to the low socioeconomic status and came from rural settings.

Table - 1: Sex distribution.

Gender	Frequency	Percentage
Male	10	28.57%
Female	25	71.43%

Table - 2: Age distribution.

Age group (in years)	Frequency	Percentage
< 20	2	5.71%
21-30	11	31.42%
31-40	11	31.42%
41-50	8	22.85%
> 50	3	8.57%

Table - 3: Anatomical site of involvement.

Anatomical site/ Organ	Frequency	%
Kidney	19	54.28%
Pelviureteric junction	4	11.42%
Ureter	10	28.57%
Urinary bladder	14	40%
Psoas abscess	2	5.71%
Ovary	1	2.85%

Table - 4: Symptoms and Signs.

Symptoms and Signs	Frequency	%
Irritative voiding symptoms	23	65.71%
Flank/Loin pain	20	57.14%
Hematuria	7	20%
Sterile pyuria	22	62.85%
Constitutional Symptoms	6	17.14%

Sex distribution was as per **Table – 1**. The mean age of the patients was 36 years (range 16- 60 years). The youngest patient in this study was 16

years old and the oldest patient was 60 years old (**Table – 2**).

Table - 5: Renal failure at presentation.

Renal failure	No. of cases	Percentage
Present	6	17.14%
Absent	29	82.85%

Table - 6: Past history of pulmonary TB.

Past history of pulmonary TB	No. of cases	Percentage
Present	4	11.42%
Absent	31	88.58%

Table - 7: Distribution of HIV.

HIV type	Screening	Positive
HIV-1	35	0
HIV-2	35	0

Table - 8: Radiology.

Investigation	No. of cases	Percentage
Chest X-Ray	35	100%
Ultrasound	35	100%
Intravenous urography	11	31.42%
CT scan	25	71.43%
MRI	4	11.42%

Table - 9: Diagnostic criteria.

Investigation	No. of cases	%
Histopathology	23	65.71%
Evidence of bacilli present	6	17.14%
Strong clinical and radiological suspicion with no evidence of bacilli	6	17.14%

In this study, kidney was involved in 19 cases and is the most common organ involved. One patient had TB left ovary with colovesical fistula (**Table – 3**).

Irritative voiding symptoms were the most common symptom seen in 23 cases. One patient presented with recurrent UTI, pneumaturia and fecaluria who was diagnosed with TB left ovary with colovesical fistula (**Table – 4**).

Table - 10: Surgical procedures done in our study.

Surgery	No. of cases	%
Nephrectomy	12	34.28%
Ileal conduit	6	17.14%
Ureteric reimplantation with psoas hitch	3	8.57%
Ureteroureterostomy	1	2.85%
Nephrectomy with augmentation cystoplasty and ureteric reimplantation	6	17.14%
Pyeloplasty	2	5.71%
TAH with salpingo-oophorectomy with excision of colovesical fistula	1	2.85%
DJ stenting	2	5.71%
Only medical treatment(on ATT)	2	5.71%

Six (17.14%) out of thirty five patients had renal failure at the time of presentation and diagnosis. In this study patients with serum creatinine above 2 mg/dl were considered as having renal failure (**Table - 5**).

In this study, past history of pulmonary tuberculosis is present in 4 cases (**Table – 6**).

All the patients were screened for HIV and none in our study were positive for HIV (**Table – 7**).

Chest X-ray and ultrasound abdomen were done in all cases as a routine. CT scan was done in 25 cases. IVU was done in 11 cases and MRI was done in 4 cases (**Table – 8**).

GUTB was diagnosed by histopathology in 23 cases (65.71%) in our study. Direct bacilli identification in 6 cases (17.14%) that was by positive urine culture in 4 cases and positive urine PCR for MTB DNA in 2 cases. Diagnosis was by strong clinical and radiological suspicion with no evidence of bacilli in 6 cases (17.14%) as per **Table - 9**.

Discussion

Tuberculosis is caused by a group of closely related acid-fast bacteria referred to as the Mycobacterium tuberculosis complex (MTBC). There are four means by which GU TB develops. The principal route is via hematogenous spread of MTBC. Clinical disease may occur soon after bacilli reach the GU system or they may enter a period of latency before becoming clinically active [6, 7]. The typical sites for genitourinary seedings are the kidney and epididymis. The other routes of spread are ascending or retrograde infection through the urinary system, contiguous spread from other organ systems and by direct inoculation.

Tuberculosis is a current public health problem. Tuberculosis (both pulmonary and extra pulmonary) leads to male and female infertility [8, 9]. This study is unable to comment on infertility as a symptom as most of such cases report to the infertility clinic and this study dealt with cases admitted for the treatment of genitourinary tuberculosis. GU TB mimics numerous other diseases that results in delayed diagnosis.

In our study, most of the patients (33 out of 35) came from low socio-economic status and from rural areas. Several other studies from around the globe also reported similar findings [10].

Gender distribution

GU TB is more common in males than in females [11]. In the study of Benchekroun, et al. [12], 80 patients with GU TB were analyzed between 1985 and 1995. These patients consisted of 50 males (62.5%) and 30 females (37.5%). In the study of S. Ray, et al. [13] (2012), of 40 patients, 30 were females and 10 were males (**Table – 11**).

Age distribution

Genitourinary tuberculosis is a disease of young adults. Sixty percent of the patients are between the ages of 20 and 40 [11]. In the study of Benchekroun, et al. (1998) [12], the mean age of

the patients was 38 years (range 20-50 years) as per **Table - 12**.

Organ involvement

Kidney was the most commonly affected followed by ureter and bladder [10]. In 92% of cases, GU TB was secondary to focus in lungs,

lymph nodes, bones and joints and manifests after a long latent period [15]. 131 cases of GU TB patients, who were diagnosed in between 2009-2011 in Siberia, were analyzed by Kulchavenya, et al. (2013) [16]. The most common form was kidney tuberculosis (74.8%) as per **Table - 13**.

Table - 11: Studies showing gender distribution.

Study	Males	Females	Male: Female ratio
Bencheqroun, et al. (1998) [12]	50	30	1.6:1
S. Ray, et al. (2012) [13]	10	30	1:3
Present study	10	25	1:2.5

Table - 12: Studies showing age distribution.

Study	Mean age
Bencheqroun, et al. (1998) [12]	38 years
Smita Chandra, et al. (2012) [18]	37.7 years
Present study	36 years

Table - 13: Studies showing the affected organs in GU TB.

Organ of involvement	Singh, et al. (2013) [23]	Kulchavenya, et al. (2013) [16]	Smita Chandra, et al. (2012) [18]	Present study
Kidney	64.9%	74.8%	12%	54.28%
PUJ	-	-	-	11.42%
Ureter	27.35%	-	8%	28.57%
Urinary bladder	17.09%	-	28%	40%
Epididymis	5.19%	-	12%	-
Prostate	3.4%	-	24%	-
Testis	-	-	12%	-
Ovary	-	-	-	2.85%
Psoas abscess	-	-	-	5.71%
Scrotum	-	-	4%	-

Table - 14: Studies showing clinical features in GU TB.

Symptoms and signs	Kulchavenya, et al. (2013) [16]	Smita Chandra, et al. (2012) [18]	Present study
Irritative voiding symptoms	39.8%	56%	65.71%
Flank pain	35.2%	56%	57.14%
Sterile pyuria	25%	40%	62.85%
Hematuria	7.9%	44%	20%
Constitutional symptoms	17%	32%	17.14%

Clinical features

GU TB raises major diagnostic problems due to the atypical and misleading clinical features. A high level of clinical suspicion helps in early

diagnosis and timely initiation of proper management [19]. The most common presenting symptoms are irritative voiding, dysuria and acidic urinary pH with pyuria (**Table - 14**).

Past history of pulmonary tuberculosis in GU TB

In this study past history of pulmonary TB was seen in 4 cases (11.42%). In the study by Smita Chandra, et al. (2012) [18], thirty six percent had a previous history of TB.

Radiology

Abnormalities of radiographic images can support the diagnosis of GU TB. Radiographic imaging, intravenous urogram (IVU), ultrasonography and CT scan have been suggested to detect abnormalities at the site of disease in up to 95% of cases [20]. In this study, chest X-ray and ultrasonography were done as a routine. CT scan was done in 25 cases and all cases showed abnormalities at the site of disease. MRI was done in 4 cases who had renal failure.

Diagnostic criteria

Tuberculosis being a paucibacillary disease directly visualizing the bacteria is difficult and so would be the diagnosis if based only on those criteria. In this study, bacilli could be identified only in 17.14% of the cases. The rest of the 82.86% were diagnosed on the basis of histopathology, radiographic and clinical evidence.

Treatment

Medical treatment

Anti-tuberculous drug treatment is based on an initial 2 month intensive phase with three or four drugs daily followed by a 4 month continuation phase with only two drugs [21]. In epidemic areas, WHO recommended the treatment time to be 9 months or six months with 4 drugs (isoniazid, rifampicin, pyrazinamide and streptomycin or ethambutol). In this study, 4 patients were advised 6 months of ATT, rest of the patients were advised 9-12 months of ATT as the patient presented in late stage with severe form of the disease.

Surgical treatment

Medical treatment for late diagnosed complicated forms of GU TB is not effective, so surgery is indicated [22]. The organ removing operations

were done in 73% of patients [23]. In this study, 18 nephrectomies and one TAH with bilateral salpingo-oophorectomy with excision of colovesical fistula were done. Early drainage of the kidney allows preservation of the kidney and following reconstructive surgery in 70.6% of cases. In this study, percutaneous nephrostomy was done in 2 cases before proceeding with augmentation cystoplasty with ureteric reimplantation. Urinary bladder rehabilitation either by augmentation cystoplasty or orthotopic neobladder reconstruction increases the bladder capacity and storage time and also preserves the upper tracts [24]. In this study, augmentation cystoplasty with ureteric reimplantation was done in 6 cases (17.14%) and ileal conduit was done in 6 cases with contracted bladder who had renal failure. Stenosis of the ureter usually can be managed by temporary stenting and adjuvant corticosteroid therapy which if unsuccessful might need a ureteric reconstruction [25]. In this study, DJ stenting was done 2 cases, ureter reimplantation with psoas hitch in 3 cases and ureteroureterostomy in one case. Some researchers advocate that surgical intervention should only be done 4 weeks after the initiation of TB treatment, but there is no evidence to support this idea [26].

Conclusion

Genitourinary tuberculosis is often silent and has nonspecific clinical features. Irritative voiding symptoms are the common presentation. Kidney is the most commonly affected organ in GU TB. GU TB is a disease of young adults, with majority affected in the 3rd and 4th decades. TB is still a menace, irrespective of growing HIV infection. CT scan is replacing IVU as an imaging modality of choice in GU TB. Diagnosis of GU TB can be baffling, compelling a high index of suspicion owing to paucibacillary load in the biological specimens and the difficulty to isolate or grow TB bacilli. Hence a strong clinical suspicion is necessary for correct diagnosis. Anti-tubercular therapy is the mainstay of treatment. Genitourinary tuberculosis results in sequel which may require

major organ removing and reconstructive surgeries.

Acknowledgements

We are grateful to our Professor, Dr. Ch. Subba Rao and colleague Assistant Professors, Dr. A.V. Mohan Rao and Dr. G. Manohar for their valuable support. We thank our post graduates for their co-operation.

References

1. P.G. Marjorie, R.V. Holenarasipur. Extra pulmonary tuberculosis: An overview. *AmFam Physician*, 2005, 72(9): 1761-8.
2. N. Vithalani, P.M. Udani. A study of 292 autopsies proved cases of tuberculosis. *Indian J Tuber.*, 1982, 29: 93-7.
3. World Health Organization. Global tuberculosis control report. 2007.
4. Sun L, Yuan Q, Feng J, et al. Be alert to tuberculosis-mediated glomerulonephritis: a retrospective study. *Eur J Clin Microbiol Infect Dis.*, 2012; 31(5): 775-9.
5. Bhatt C, Lodha S. Paraspinal sinuses? Do remember renal tuberculosis. *BMJ Case Rep.*, 2012; 2012: bcr1220115445.
6. Wong N, Hoag NA, Jones EC, et al. Genitourinary tuberculosis masquerading as a ureteral calculus. *Can Urol Assoc J.*, 2013; 7(5-6): E363-6.
7. Patterson IY, Robertus LM, Gwynne RA, et al. Genitourinary tuberculosis in Australia and New Zealand. *BJU Int.*, 2012; 109(Suppl. 3): 27-30.
8. Khanna A., Agarwal A. (2011). Markers of genital tuberculosis in infertility. *Singapore medical journal*, 2011; 52(12): 864-7.
9. Kulshrestha V., Kriplani A., Agarwal N., Singh U.B., Rana T. Genital tuberculosis among infertile women and fertility outcome after Antitubercular therapy. *International journal of gynecology and obstetrics*, 2011; 113(3): 229-3.
10. A. M. Figuirido, A. D. Lucon. Urogenital tuberculosis Groups According to Clinical and Radiological Presentation International. *Braz J Uro.*, 2008; 34(4): 422-432.
11. Emil A. Tanagho, Christopher J. Kane. Specific infections of the genitourinary tract. *Smith and Tanagho's General Urology*, 18th edition, 2013, chapter 15, p. 223-30.
12. Benchekroun A., Lachkar A., Soumana A., Farih M.H., Belahnech Z., Marzouk M., Faik M. Urogenital tuberculosis. 80 cases. *Ann Urol (paris)*, 1998; 32(2): 89-94.
13. Sujoy Ray, Bharti Chogtu, Rahul Magazine. Trends in genitourinary tuberculosis. *IJBMS*, 2012; 2(2): 62-65.
14. World Health Organization (WHO). Tuberculosis fact sheet no. 104; 2013.
15. N.N. Chowdhury. Overview of tuberculosis of female genital tract. *J Indian Med Assoc.*, 1996; 94(9): 345-6.
16. Kulchavenya E. Urogenital tuberculosis, an often overlooked infection. *Int J of Antimicrobial Agents*, 2013; 42(suppl.2): s6.
17. Singh J.P., Priyadarshi V., Kundu A.K., Vijay M.K., Bera M.K., Pal D.K. Genito-urinary tuberculosis revisited-13 years experience of a single centre. *Indian J Tuberc.*, 2013; 60(1): 15-22.
18. Smita Chandra, Harish Chandra, Neena Chauhan, Dushyant Singh Gaur, Harendra Gupta, Ved Prakash Pathak, Sandeep Kumar Burathoki. Male genitourinary tuberculosis – 13 yrs experience at a tertiary care centre in India. *South Asian J trop Med public health*, March 2012; 43(2): 364-369.
19. Teo EY, Wee TC. Images in clinical medicine: renal tuberculosis. *N Engl J Med.*, 2011; 365(12): e26.
20. Hemal A. K., et al. Polymerase chain reaction in clinically suspected genitourinary tuberculosis: comparison with intravenous urography, bladder biopsy and urine acid fast bacilli culture. *Urology*, 2000; 56: 570 – 574.

21. Lenk S. Genitourinary tuberculosis in Germany: diagnosis and treatment. *Der Urologe. Ausg. A.*, 2011; 50(12): 1619-27.
22. Viswaroop B, Gopalakrishnan G, Nath V, Kekre N.S. Role of imaging in predicting salvage ability of kidneys in urinary tract tuberculosis. *The Journal of Pakisthan Medical Association*, 2006; 56(12): 587 – 90.
23. Batyrov F.A., Nersesian A.A., Merkureva IA. Urogenital tuberculosis: problems of present day diagnosis and treatment. *Urologia*, 2004; 5: 16-24.
24. Singh V., Sinha R.J., Sankhwar S.N., Sinha S.M. Reconstructive surgery for tuberculosis contracted bladder: experience of a centre in northern India. *International urology and nephrology*, 2011; 43(2): 423-30.
25. EAU Guidelines for the Management of Genitourinary Tuberculosis. *European Urology*, 2005; 353 – 362.
26. Gupta NP, Kumar R, Mundada OP, Aron M, Hemal AK, Dogra PN, et al. Reconstructive surgery for the management of genitourinary tuberculosis: A single centre experience. *J Urol.*, 2006; 175: 2150 – 4.