

Original Research Article


# Efficacy of auto-implantation therapy in the treatment of extensive and recalcitrant verruca vulgaris

Dhanalakshmi Kasi<sup>1</sup>, Vinnarasan Mariaviagulam<sup>2\*</sup>, Vinothiney Krishanan Moorthy<sup>3</sup>

<sup>1</sup>Associate Professor, <sup>2</sup>Assistant Professor, <sup>3</sup>Post Graduate

Department of Dermatology, Thanjavur Medical College, Thanjavur, Tamil Nadu, India

\*Corresponding author email: [vinnskin@gmail.com](mailto:vinnskin@gmail.com)

	International Archives of Integrated Medicine, Vol. 6, Issue 3, March, 2019. Copy right © 2019, IAIM, All Rights Reserved. Available online at <a href="http://iaimjournal.com/">http://iaimjournal.com/</a> ISSN: 2394-0026 (P)                      ISSN: 2394-0034 (O)	
	Received on: 17-02-2019 Source of support: Nil	Accepted on: 21-02-2019 Conflict of interest: None declared.
<b>How to cite this article:</b> Dhanalakshmi Kasi, Vinnarasan Mariaviagulam, Vinothiney Krishanan Moorthy. Efficacy of auto-implantation therapy in the treatment of extensive and recalcitrant verruca vulgaris. IAIM, 2019; 6(3): 1-7.		

## Abstract

**Background:** Verrucae are benign tumors involving skin and mucous membrane that are caused by human papillomavirus (HPV). Several treatment modalities are available for treating extensive warts, but no single treatment is 100% effective. An ideal treatment should be effective, safe, with less morbidity and provide long-lasting immunity against HPV. This can only be achieved by stimulation of the immune system against the virus. The auto-implantation of warts is one such simple technique where the wart tissue is harvested as a donor and implanted into the uninvolved skin, thereby causing immune stimulation against the virus and resulting in the resolution of extensive and recalcitrant verrucae.

**Aim:** The aim of the study was to evaluate the safety and efficacy of auto-implantation therapy in the treatment of extensive and recalcitrant verruca vulgaris.

**Materials and methods:** A hospital-based prospective interventional study was carried out on 50 clinically diagnosed patients of extensive verruca vulgaris. Homologous auto-implantation was done over the uninvolved flexor aspect of the forearm skin after harvesting wart tissue up to the level of the papillary dermis. Patients were assessed monthly and resolution after 3 months was considered as complete clearance. Results were analyzed using SPSS version 20.0.

**Results:** Out of 50 patients, 41 patients came for regular follow up whereas 9 patients didn't turn up for the follow-up. Out of 41 verrucavulgaris patients, 34 showed resolution within 3 months, accounting for a total clearance rate of 82.9%.

**Conclusion:** The homologous auto-implantation could be an effective, simple alternative modality of treatment for extensive and recalcitrant warts.

## Key words

Auto-implantation, Verruca vulgaris, HPV, Papillomatous growth.

## Introduction

Verrucae vulgaris are benign tumors, caused by infection of keratinocytes with HPV and present as well-defined hyperkeratotic protrusions [1]. Common therapeutic modalities ablate the growth without generation of specific immunity against wart. The stimulation of the immune system by exposing the virus to immune mediators form an ideal modality of treatment due to spontaneous regression of wart with long-lasting immunity. There are over 100 subtypes of the HPV virus, but only a few types can cause skin warts at selective anatomical sites [2]. However, with skin contact, the HPV can be transferred to any part of the body. HPV tends to cause genital warts, flat warts, and palmoplantar warts [3]. Warts are easily transmitted by direct or indirect contact, especially if there is disruption of the normal epithelial barrier. Out of the 100 subtypes of HPV, a few of them have the propensity to induce cancer. These subtypes include HPV strains 6, 11, 16, 18, 31, and 35. Malignant transformation tends to occur in individuals with genital warts and those who are immunocompromised. HPV strains 5, 8, 20, and 47 also have malignant potential in individuals with epidermodysplasia verruciformis [4]. Warts, in general, are benign but there are reports that sometimes they may become malignant and develop into what is known as verrucous carcinoma [5]. The verrucous carcinoma is a slow-growing tumor and is classified as a well-differentiated squamous cell malignancy that is often mistaken for a common wart. Even though it can occur on any part of the body, it is most common on the plantar surface [6]. Verrucous cancer rarely spreads, but it is locally destructive. histopathologic features include acanthosis, digitated epidermal hyperplasia, papillomatosis, compact orthokeratosis, hypergranulosis, tortuous capillaries within the dermal papillae,

and vertical tiers of parakeratotic cells with red blood cells entrapped above the tips of the digitations [7]. Elongated rete ridges may point radially toward the center of the lesion. In the granular layer, cells infected with HPV have coarse keratohyaline granules and vacuoles surrounding wrinkled-appearing nuclei [8]. Koilocytic cells are pathognomonic. Besides the skin, warts can also occur on mucous membranes. In general, HPV usually only infects the epithelial layers of skin, and systemic dissemination is very rare. The virus is known to replicate in the upper level of the epithelium, but the virus particles also can be found in the basal layer [9]. Here, we have evaluated the efficacy of auto-implantation therapy in the treatment of recalcitrant, multiple warts.

## Materials and methods

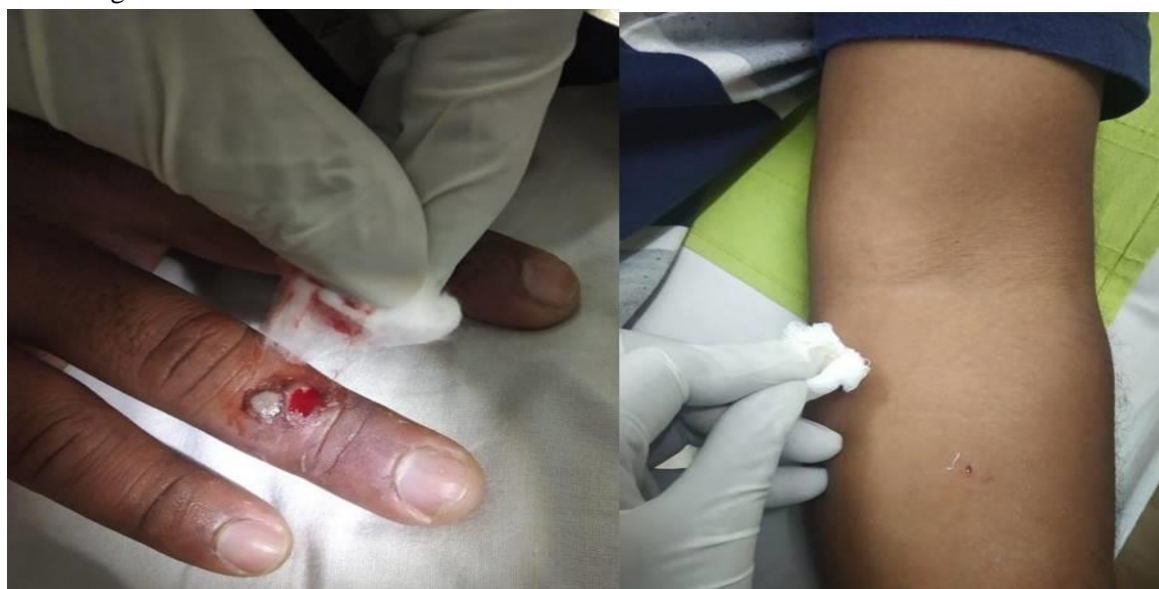This was a hospital-based, prospective, interventional study, conducted in the out-patient department of Thanjavur medical college hospital during the period of 12 months from January 2018 to December 2018. A total of 50 clinically diagnosed cases of extensive and recalcitrant warts (more than 5 warts per patient) were enrolled. Pregnant women, lactating mothers, immunocompromized individuals, children less than 18 years of age and other morphological types of verruca were excluded from the study. After getting clearance from the institutional ethical committee and informed written consent from all the patients, a single sitting of homologous auto-implantation therapy was done for all selected patients. A well-developed verrucous papule was chosen as a donor wart. Under local anesthesia with strict aseptic precautions, a full-depth nick was made with a blade up to the level of papillary dermis and a chunk of wart tissue was removed and placed on a sterile swab. An

area on the flexor aspect of the left forearm about 2 inches below antecubital fossa was chosen as a recipient site for auto-implantation. The site of grafting was cleansed with povidone iodine-spirit and under local anesthesia, a small nick was made on the skin using Bard-Parker no 11 blades in accordance with resting skin relaxation lines. The blade was then introduced subcutaneously and a pocket was created with to and fro motion of the blade. The harvested wart tissue was then gently introduced into the subcutaneous pocket with the same 11 blades

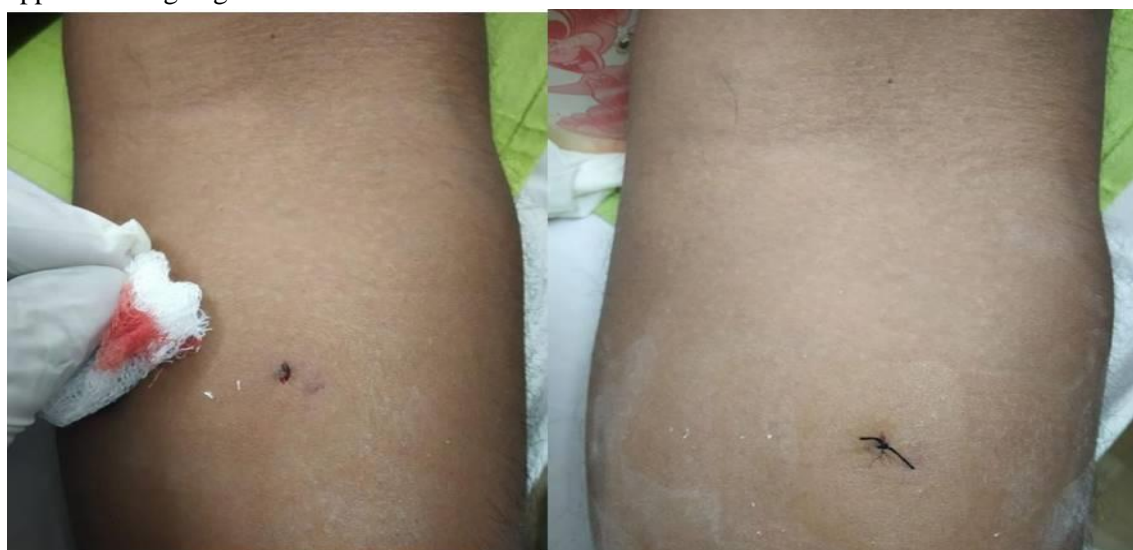and secured by single 3-0 chromic gut suturing and dressing done. Oral antibiotics were given for a period of 5 days. The dressings were removed after 7 days.

Patients were assessed monthly and resolution of all warts within 3 months was taken as complete clearance. Patients were followed up for one more month after clearance for any recurrences (**Photo – 1 to 3**).

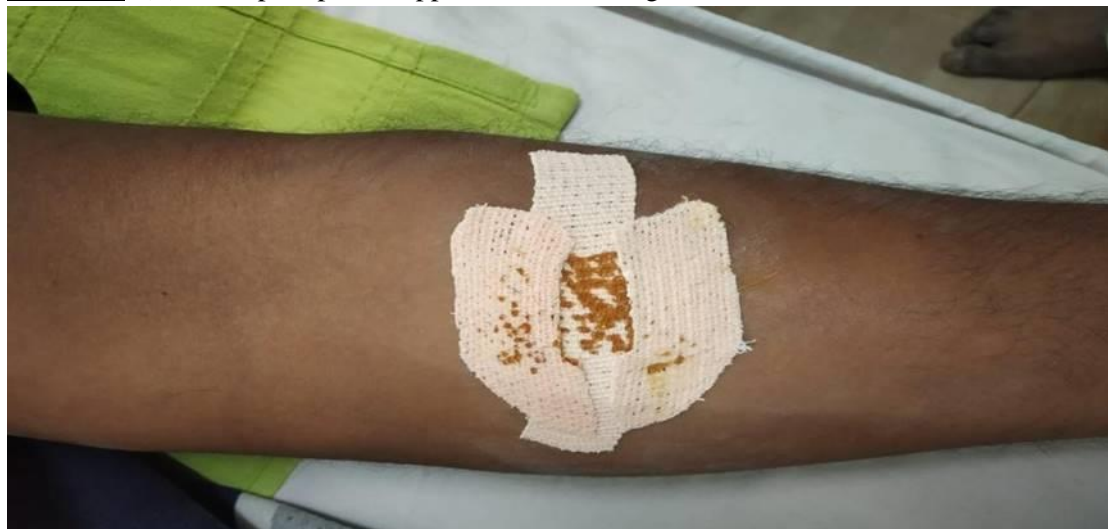**Photo – 1:** (A) The paring of the wart using a surgical blade no.11. (B) Stab incision done using the same surgical blade.



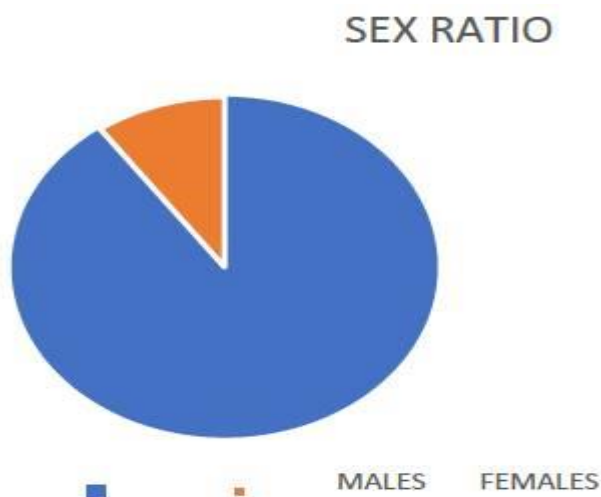
**Photo – 2:** (C) Placing paired tissue deep into subcutis. (D) The incision is sutured after approximating edges.



**Photo – 3:** (E) Micropore plaster applied after attaining hemostasis.



**Graph – 1:** Sex ratio.



## Results

Out of 50 patients, 9 did not turn up for the follow-up and 41 patients were available for evaluation. Most of the study patients were males (29 patients) 58%. The commonest age group affected was that of 20-30 years (27 patients). A total of 34 patients (82.9%) showed complete resolution of all warts within 3 months. 7 patients had no improvement at all. The earliest resolution of warts was observed at the end of 4 weeks.

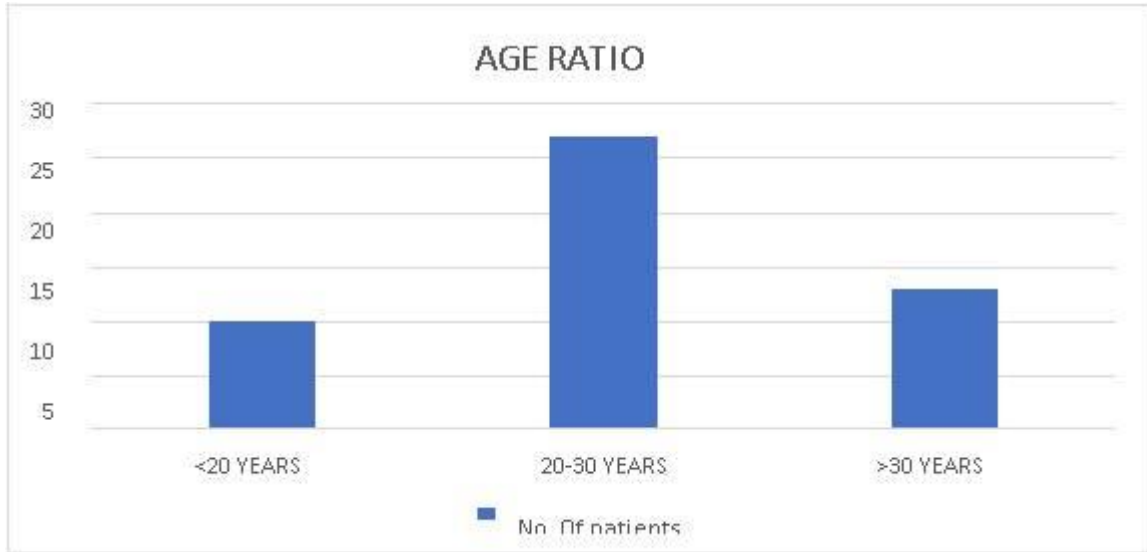
Of the total 50 patients in our study, 29 patients were males (58%) and 21 were females (42%) (M:F = 1.38:1) as per **Graph – 1**.

Among 50 patients in our study, the majority of patients were between 20-30 years of age i.e. 27 patients (54%), 10 patients were in the age group below 20 years (20%) and 13 patients were above 30 years (26%) as per **Graph - 2**.

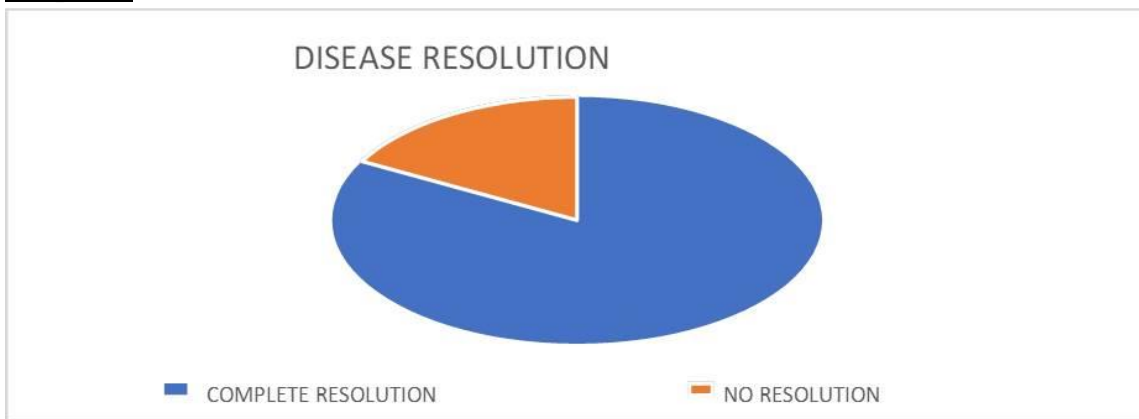
Of the total 41 patients evaluated, 34 patients showed complete resolution and 7 patients had no complete resolution (**Graph – 3**).

Of the total 41 patients evaluated, the majority of patients had complete resolution of warts within 3 months i.e. 34 patients (82.9%), earliest resolution of warts was seen in 4 patients (11.76%) i.e. 4 weeks duration. Remaining 7 patients took > 3 months for complete resolution (17.07%) as per **Graph – 4**.

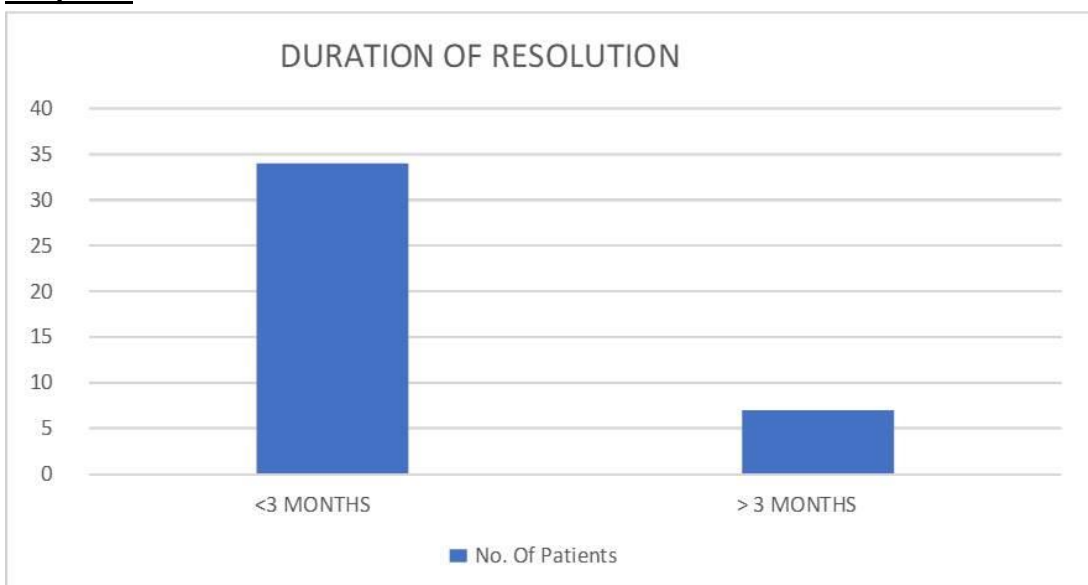
**Graph – 2:** Age ratio.



**Graph – 3:** Disease resolution.



**Graph – 4:** Duration of resolution.



## Discussion

---

Verruca vulgaris is one of the common viral infections of the mucocutaneous surfaces and often induce papillomatous growth. Although some warts regress spontaneously, it can persist for years causing physical discomfort and psychological trauma [10]. Warts in adults with longer duration are less likely to resolve spontaneously and are more resistant to treatment. The highest clearance rates for various treatments are usually observed in younger individuals who have a shorter duration of infection [11]. There is no single treatment that is 100% effective for adults with extensive and recalcitrant verruca vulgaris. Hence, multiple modalities of treatment have been tried with an average of 60-70% clearance in 3 months [12]. The commonest modality of treatment for warts is ablation using electrocautery, radiofrequency, laser or cryotherapy [13]. These treatments destroy the wart containing tissue but may not stimulate the immune system against the pathogen [14]. The ideal aims of the treatment of warts should be to remove the wart without recurrence, avoid aggressive (potentially scarring) procedures, and to assist the immune system in dealing more effectively with the virus and inducing a life-long immunity to human papillomaviruses (HPVs) [15]. The presence of local as well as systemic immunity may be necessary to eradicate the clinical manifestations of HPV infection [16]. Hence, for the effective treatment of warts, there should be an immune stimulation which can lead to a long-term immunity against HPV. Specific immune stimulation against HPV has been tried by autoimplantation of the wart tissue into the uninvolved skin [17]. Significant alterations occur in the immune status of patients during spontaneous wart regression or following successful wart therapy [3]. The most striking feature is the increase in viral-specific antibodies (both IgM and IgG type). Delayed hypersensitivity to HPV antigen also increases in regressing warts [18]. A significant booster in both antibody and delayed hypersensitivity

response are noted after intradermal testing with HPV antigens and wart treatment [19]. A quadrivalent HPV vaccine has shown promising results in the treatment of warts. However, the presence of only anecdotal reports, partial clearance in one of the two studies and limited access in resource-restricted countries are drawbacks of this vaccine. In our study, the majority of patients were males and most of them lie between 20 – 30 years of age which correlated with a study done by Witchey DJ, et al. [20].

## Conclusion

---

Homologous auto-implantation is an easy, minimally invasive technique, wherein, the wart tissue at the papillary dermal level is harvested aseptically with an 18G needle and placed subcutaneously. This could theoretically induce an adequate immune response leading to resolution of the wart, more so in multiple warts involving distant sites.

## References

---

1. Augustin M, Kirsten N, Körber A, Wilsmann-Theis D, Itschert G, Staubach-Renz P, Maul JT, Zander N. Prevalence, predictors and comorbidity of dry skin in the general population. *J Eur Acad Dermatol Venereol.*, 2019 Jan; 33(1): 147-150.
2. Briggaman RA, Wheeler CE. Immunology of human warts. *J Am Acad Dermatol.*, 1979; 1: 297-304.
3. Clebak KT, Malone MA. Skin Infections. *Prim. Care*, 2018 Sep; 45(3): 433-454.
4. Drake LA, Ceilley RI, Cornelison RL, Dobes WL, Dorner W, Goltz RW, et al. Guidelines of care for warts: Human papillomaviruses. *J Am Acad Dermatol.*, 1995; 32: 98-103.
5. KC Nischal, C S Sowmya, M R Swaroop, Dhruv Premy Agrawal, H B Basavaraj, B D Sathyanarayana. A novel modification of the autoimplantation therapy for the

- treatment of multiple, recurrent and palmoplantar warts. *J Cutan Aesthet Surg.*, 2012 Jan- Mar; 5(1): 26-29.
6. Khatu SS, More YE, Vangawala D, Pawar SS, Gokhale NR, Chavan DC. Treating multiple and recalcitrant warts with autoimplantation technique. *J NTR Univ Health Sci.*, 2017; 6: 247-50.
  7. Khozeimeh F, Jabbari Azad F, Mahboubi Oskouei Y, Jafari M, Tehranian S, Alizadehsani R, Layegh P. Intralesional immunotherapy compared to cryotherapy in the treatment of warts. *Int. J. Dermatol.*, 2017 Apr; 56(4): 474-478.
  8. Kreuter A, Waterboer T, Wieland U. Regression of cutaneous warts in patients with WILD syndrome following recombinant quadrivalent human papillomavirus vaccination. *Arch Dermatol.*, 2010; 146: 1196-7.
  9. Kumar N, Warren CB. Photodynamic therapy for dermatologic conditions in the pediatric population: a literature review. *Photodermatol Photoimmunol Photomed.*, 2017 May; 33(3): 125-134.
  10. Larsson PA, Lidén S. Prevalence of skin diseases among adolescents 12--16 years of age. *Acta Derm. Venereol.*, 1980; 60(5): 415-23.
  11. Morison W. In vitro assay of cell-mediated immunity to human wart antigen. *Br J Dermatol.*, 1974; 90: 531-4.
  12. Nicol AF, de Andrade CV, Russomano FB, Rodrigues LS, Oliveira NS, Provance DW, Nuovo GJ. HPV vaccines: their pathology-based discovery, benefits, and adverse effects. *Ann Diagn Pathol.*, 2015 Dec; 19(6): 418-22
  13. Peterson AR, Nash E, Anderson BJ. Infectious Disease in Contact Sports. *Sports Health*, 2018 Aug 14; 1941738118789954.
  14. Schianchi R, Brena M, Veraldi S. Treatment of common recalcitrant warts with topical formic acid. *Int. J. Dermatol.*, 2018 Feb; 57(2): e3-e4.
  15. Shahmoradi Z, Assaf F, Al-Said H, Khosravani P, Hosseini SM. Topical pyruvic acid (70%) versus topical salicylic acid (16.7%) compound in the treatment of plantar warts: A randomized controlled trial. *Adv Biomed Res.*, 2015; 4: 113.
  16. Shivakumar V, Okada R, Rajkumar R. Autoimplantation therapy for multiple warts. *Indian J Dermatol, Venerol Leprol.*, 2009; 75: 593-5.
  17. Sterling JC, Handfield-Jones S, Hudson PM. Guidelines for the management of cutaneous warts. *Br J Dermatol.*, 2001; 144: 4-11.
  18. Valerio E, Parata F, Cutrone M. Handy paediatric dermatology. *Arch Dis Child Educ Pract Ed.*, 2017 Apr; 102(2): 78.
  19. Venugopal SS, Murrell DF. Recalcitrant cutaneous warts treated with recombinant quadrivalent human papillomavirus vaccine (types 6, 11, 16, 18) in a developmentally delayed, 31-year old white man. *Arch Dermatol.*, 2010; 146: 475-77.
  20. Witchey DJ, Witchey NB, Roth-Kauffman MM, Kauffman MK. Plantar Warts: Epidemiology, Pathophysiology, and Clinical Management. *J Am Osteopath Assoc.*, 2018 Feb 01; 118(2): 92-105.